



## Adenoid Cystic Carcinoma: A Case Series

Dr. Delna Lucia Varghese<sup>1</sup>, Dr. Padma Kumar S K<sup>2</sup>, Dr. Anjana K<sup>1</sup>, Dr. NivinG<sup>1</sup>

<sup>1</sup>Junior residents, <sup>2</sup>Professor and Head; Dept. of Oral Pathology and Microbiology  
Govt. Dental college Thiruvananthapuram

Submitted: 01-08-2022

Accepted: 14-08-2022

### ABSTRACT:

Adenoidcystic carcinoma (AdCC) is an invasive neoplasm composed of basaloid cells with predominant myoepithelial/basal cell differentiation, accompanied by some interspersed ductal structures. It is characterized by cribriform, tubular and/ or solid patterns of growth. This tumor most frequently presents in the fourth to sixth decades of life, with a slight female predominance (3:2). The parotid gland, submandibular gland and palate are most commonly involved sites. Clinically, the commonest complaint is a slowly growing swelling. Adenoid cystic carcinoma has a marked propensity for perineural invasion. The long-term prognosis is poor.

Here we are presenting a series of 5 cases of adenoid cystic carcinoma. Histopathology of all five lesions exhibited the characteristic cribriform pattern by the tumor cells.

**KEYWORDS:** Adenoid cystic carcinoma, Cribriform pattern, Perineural invasion, Swelling, Pain, Bone destruction

### I. INTRODUCTION:

The adenoid cystic carcinoma is one of the more common and best-recognized salivary gland malignancies [1] first described in 1853 by Robin, Lorain and Laboulbene as an uncommon epithelial tumor of the nose and the parotid gland. In 1856 Billroth was named it as "cylindroma" for its cribriform appearance formed by tumor cells [2]. Prior to the 1940s, AdCC was thought of be a benign neoplasm of mixed salivary gland origin. In 1943, Dockerty and Mayo revealed the malignant character of this tumour. In 1954 it was termed as AdCC by Ewing. [3]. AdCC is a rare tumor of the head and neck. However, it is the most common malignant tumor of the minor salivary glands. [4]

Adenoid cystic carcinomas (AdCCs) are uncommon tumors, comprising < 1% of all head-and-neck cancers and 20%–25% of all salivary cancers. [5] AdCC most frequently presents in the fourth to sixth decades of life, with a slight female predominance (3:2). The parotid gland, submandibular gland and palate are most commonly involved. This tumor has also been

reported in lacrimal glands, mucous glands of the upper respiratory tract, lung, digestive tract, skin, breast, prostate, and lower female genital tract [6]. The adenoid cystic carcinoma usually appears as a slowly growing mass. Pain is a common and important finding, occasionally occurring early in the course of the disease before there is a noticeable swelling. Patients often complain of a constant, low-grade, dull ache, which gradually increases in intensity. Facial nerve paralysis may develop with parotid tumors. Palatal tumors can be smooth surfaced or ulcerated. Tumors arising in the palate or maxillary sinus often show radiographic evidence of bone destruction [1]

Although adenoid cystic carcinoma is generally indolent, the long-term prognosis is poor. The majority of affected patients eventually die of the disease after a protracted clinical course characterized by multiple local recurrences and metastases. The 5-year survival is about 60-75%, but the 10-year survival drops dismally to 30-40%. Distant metastases to the lung, bone and soft tissue are more common than regional lymph node metastasis. Radical excision with post-operative radiotherapy is the treatment of choice, although a high proportion of patients will still eventually succumb to the tumor. [6]

Adenoid cystic carcinoma is composed of myoepithelial cells and ductal cells which have a varied arrangement. Histopathologically, three growth patterns have been described: cribriform (classic), tubular, and solid (basaloid). The tumors are categorized according to the predominant pattern. The cribriform pattern shows basaloid epithelial cell nests that form multiple cylindrical cysts like patterns resembling a "Swiss cheese" or honey comb pattern, which is the most classic and best recognized pattern. The lumina of these spaces contain periodic acid-Schiff (PAS) positive mucopolysaccharide secretion. The tubular pattern reveals tubular structures that are lined by stratified cuboidal epithelium. The solid pattern shows solid groups of cuboidal cells with little tendency towards duct or cyst formation. The cribriform pattern is the most common, whereas the solid



pattern is the least common. Solid adenoid cystic carcinoma is a high-grade lesion with reported recurrence rates of up to 100% compared with 50–80% for the tubular and cribriform variants.<sup>[7]</sup>

Here we are reporting a case series of five cases of AdCC.

#### CASE NO 1.

49-year-old female patient reported to the OPD with a swelling on roof of oral cavity with duration of one month. The swelling was small initially and gradually increased to the present size. On examination a swelling of size 1cmx0.5cm noted on the right side of the palate for one month. The swelling was nontender, non-fluctuant, firm in consistency and immobile. Overlying mucosa was smooth and firm in consistency with induration, no ulceration was noted. Routine blood investigations were found to be normal. The radiograph appeared to be normal. Provisional diagnosis included a benign or malignant neoplasm of minor salivary glands. Incisional biopsy was done

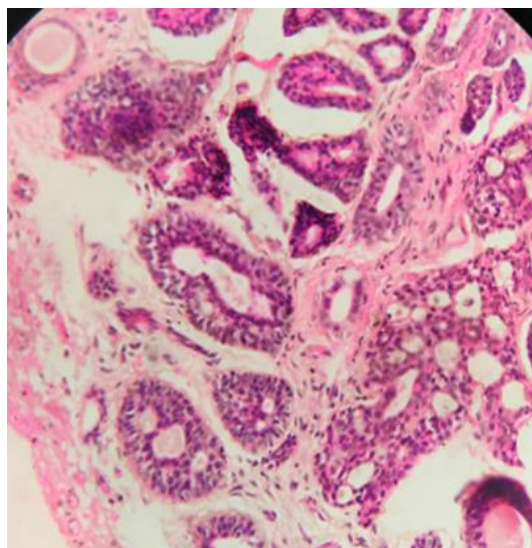


Figure 1.1: Ducts lined by basaloid cells and filled with eosinophilic coagulum.

Histopathological examination revealed proliferation of cuboidal cells with deeply basophilic nuclei, within a fibrovascular connective tissue stroma with mild inflammatory response, in the form of ducts with most of them showing mucoid material within the lumen [Figure 1.1]. Cribriform pattern was also noted within the tumor islands [Figure 1.2].

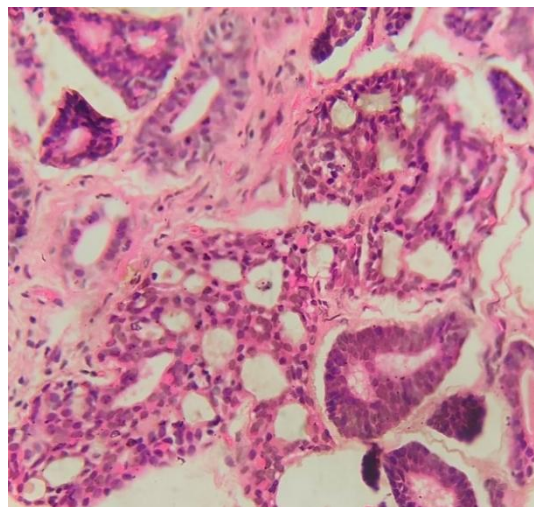


Figure 1.2: Tumor cells are proliferating in the form of cribriform pattern.

Based on histopathology, diagnosis of AdCC was confirmed. Management was done in Regional Cancer Centre (RCC), no recurrence reported till date.

#### CASE NO 2.

A 62-year-old male patient was referred from RCC with suspected chondrosarcoma of maxilla. Patient noticed a swelling on the palate 7 months back which was not associated with pain. Swelling gradually increased in size. After 5 months patient noticed swelling over bilateral cheek and malar region associated with difficulty in speech and nasal tone.

Extra oral examination revealed a bilateral non tender, hard swelling over malar region with smooth surface. Intra orally, diffuse palatal swelling extending from rugae to the soft palate was noted [Figure 2.1]. The swelling was non tender, hard in consistency. Expansion of maxillary buccal and palatal cortical plate with decreased buccal vestibular depth also noted over the right side. Posterior one third of hard palate had a well-defined, soft, tender swelling of size 2cmX2cm with change in surface colour compared to surrounding mucosa. Entire maxilla was mobile on palpation. Generalized grade II mobility and tenderness on percussion of maxillary teeth noted.



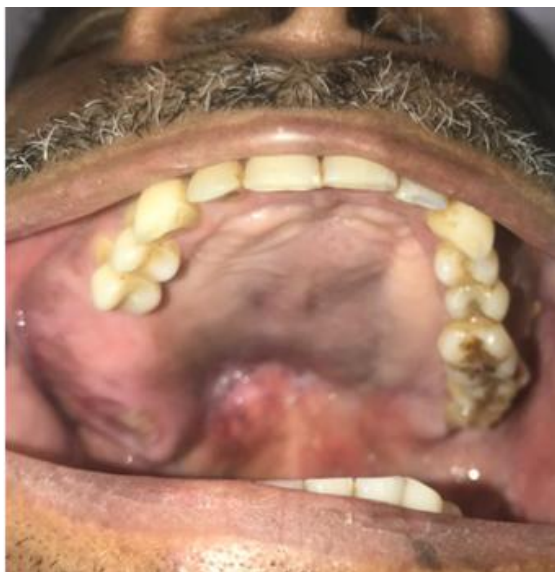

Figure 2.1: Diffuse palatal swelling extending from rugae to the soft palate

OPG revealed extensive loss of maxillary bone with floating maxillary teeth [Figure 2.2]. Clinical features suggested the provisional diagnosis of chondrosarcoma. Biopsy done to confirm the diagnosis.

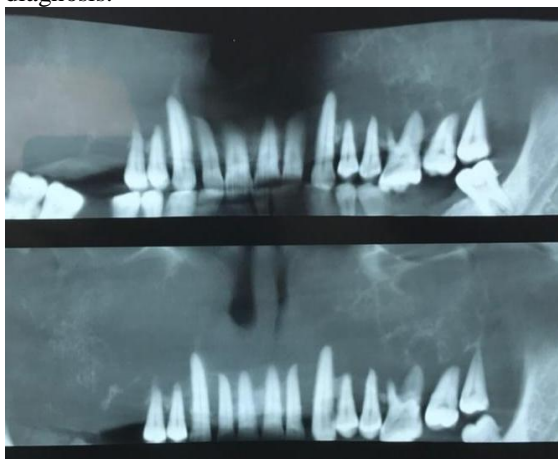


Figure 2.2: Extensive loss of maxillary bone with floating maxillary teeth

Serial sections of H and E-stained biopsy specimen revealed basaloid epithelial cell nests, in a moderately collagenous and moderately vascular connective tissue stroma, that form multiple tubules and cylindrical cysts like patterns resembling a Swiss cheese or honey comb pattern [Figure 2.3 and 2.4]. Final diagnosis of adenoid cystic carcinoma was made.

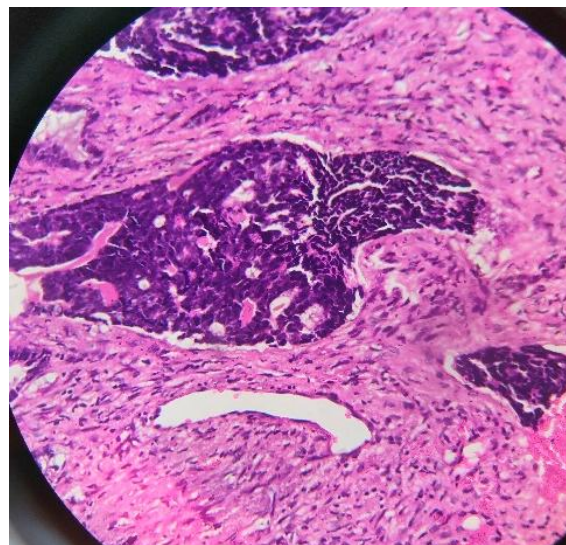


Figure 2.3: Basaloid cells proliferating in a moderately collagenous connective tissue stroma.

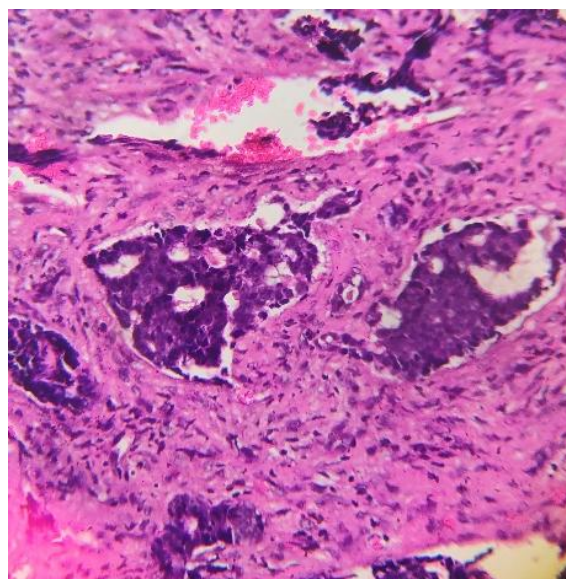


Figure 2.3: Tumor cells proliferating in cribriform pattern and solid sheets.

### CASE NO:3

A 20-year-old female patient presented with pain in the infra temporal region with a history of parotidectomy for pleomorphic adenoma 3 year back. Examination revealed firmness of right buccal mucosa with tenderness on palpation and restricted mouth opening [Figure 3.1]

CT image showed heterogeneously isodense lesion in the right retro maxillary space with obliteration of retro maxillary fat pad [Figure 3.2].

Recurrent pleomorphic adenoma was suspected.



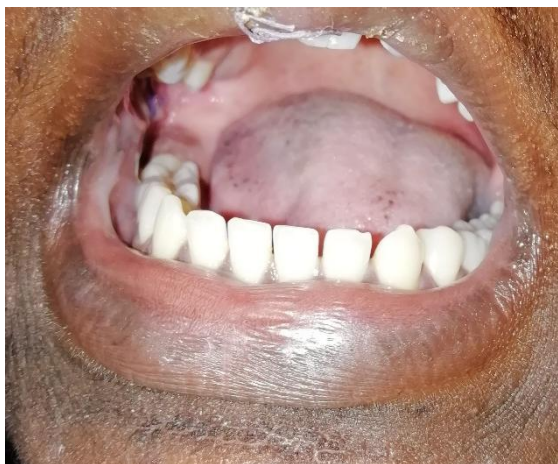

Figure 3.1: patient with restricted mouth opening.

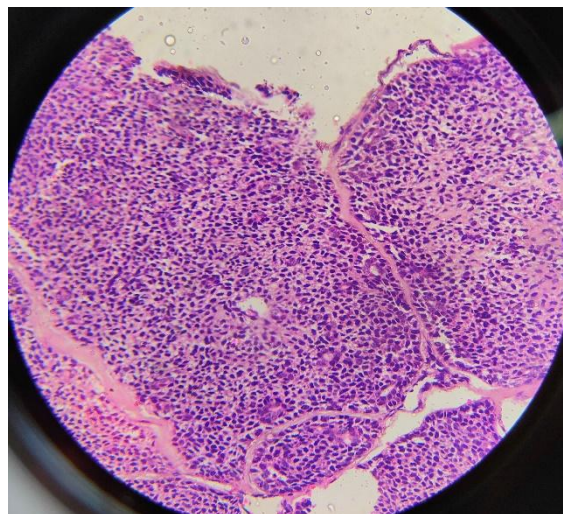


Figure3.3: Proliferation of basaloid cells in the form of sheets

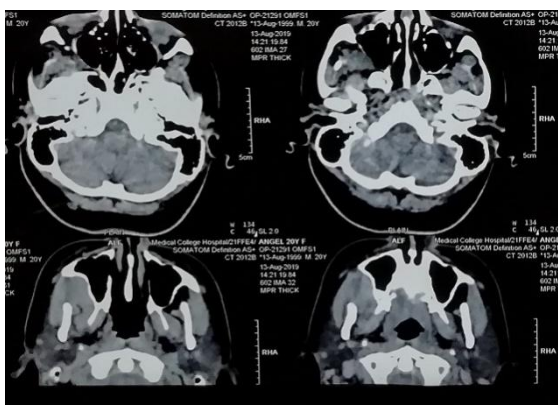


Figure 3.2: Heterogeneously isodense lesion in the right retro maxillary space with obliteration of retro maxillary fat pad

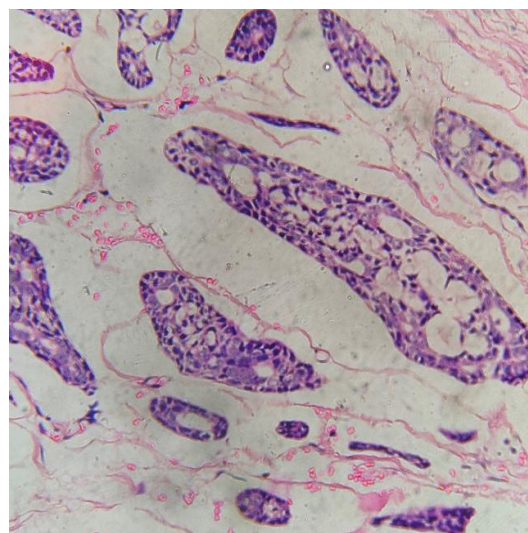


Figure 3.4: Proliferation of basaloid cells in cribriform pattern

Biopsy was done and histopathology revealed proliferation of basaloid cells in the form of sheets [Figure3.3] and cribriform pattern [Figure 3.4]. Characteristic retraction of tumor islands from the fibrovascular connective tissue stroma and perineural invasion by the tumor islands also noted

Final diagnosis of adenoid cystic carcinoma was made.

#### CASE NO: 4

A 38-year-old female patient presented with a swelling on the roof of the oral cavity for 3 months. On examination a firm, well defined, non-tender swelling of size 5cmX4cm noted on left side of the posterior palatal region. Surface of the swelling was lobulated, and smooth [Figure 4.1]. Aspiration cytology of the swelling was done. PAP-stained smear showed clusters of darkly stained cells[Figure 4.2]. Diagnosis of a benign salivary gland neoplasm was made. Biopsy of the lesion was taken for confirmation.

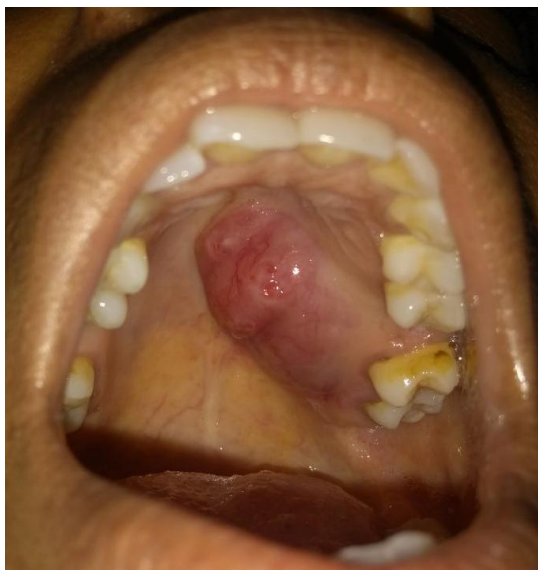

Figure 4.1: Firm, well defined, non-tender swelling of size 5cmX4cm on left side of the posterior palatal region

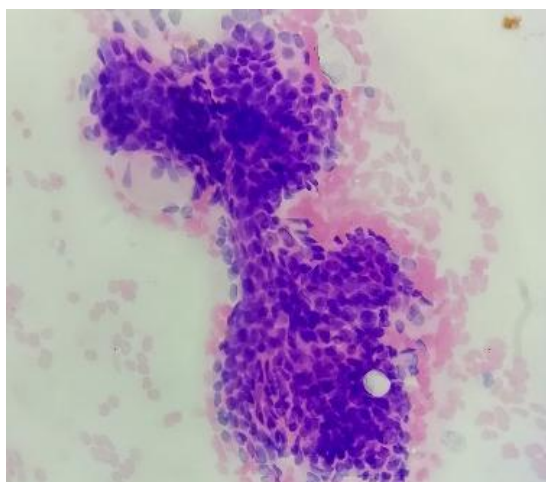


Figure 4.2: PAP-stained smear showing clusters of darkly stained cells

Histopathology of the lesion showed cribriform and tubular pattern by basaloid cells in a moderately collagenous and moderately vascular connective tissue stroma [Figure4.3]. Perivascular and perineural invasion by tumor cells is also noted within the stroma [Figure 4.4 and 4.5] Histopathology confirmed the diagnosis of adenoid cystic carcinoma.

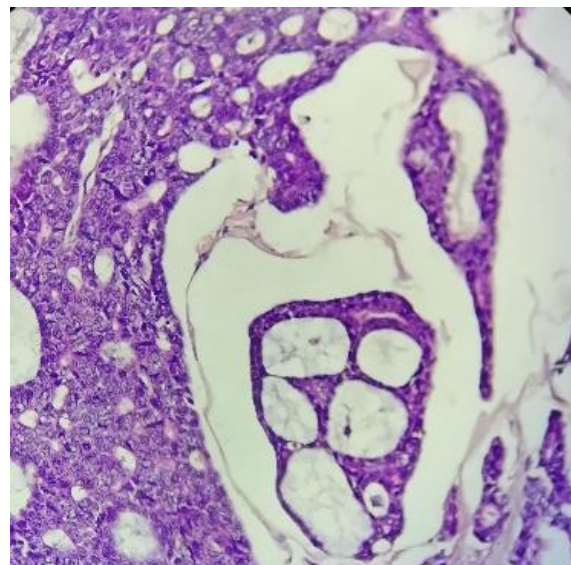


Figure4.3: Cribriform and tubular pattern by basaloid cells

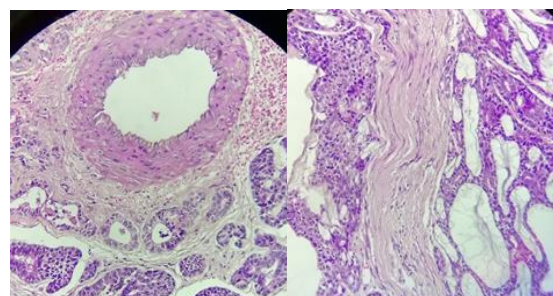


Figure4.4: Perivascular invasion Figure4.5: Perineural invasion

#### CASE NO:5

A 48-year-old female patient presented with a swelling on the hard palate. On examination a well-defined localized swelling of size 2cmx3 cm noted on the left side of the hard palate extending from anterior 2/3<sup>rd</sup> to the posterior 1/3<sup>rd</sup>. The swelling was smooth, firm and non-tender. No surface ulceration was noted [Figure 5.1]. No bony changes noted in the occlusal radiographs. Incision biopsy of the lesion was taken.

Histopathology of the lesion showed basaloid cells proliferating in uniform cribriform pattern. Each of the lumen contain a mucoid material with a bluish hue [Figure 5.2].

All the five cases were reported in a period of 2 year (2020 and 2021). All these cases were referred to RCC and underwent surgical management. None of these cases were recurred till date.



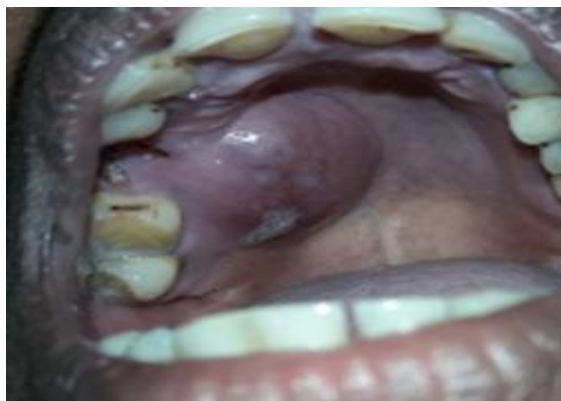

Figure 5.1: a well-defined localized swelling of size 2cmx3 cm noted on the left side of the hard palate

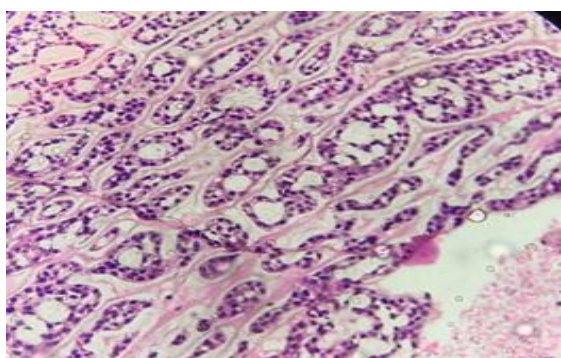


Figure 5.2: Basaloid cells proliferating in uniform cribriform pattern. Each of the lumen contain a mucoid material with a bluish hue

## II. DISCUSSION

Among all the salivary gland neoplasms 9- 23% affect intraoral minor salivary gland. Out of which 50% tumours are malignant. In all, 42- 54% of these occur on the palate.<sup>[8]</sup> The AdCC are relatively uncommon tumours of the head and neck region, representing about 10% to 15% of the histology of head and neck tumours. In these series of cases also palate was the most common affected site with an exception of a case which occurred in parotid gland, but parotid gland is considered as a relatively rare site for adenoid cystic carcinoma.

As most of the authors reported a slight female predominance for this tumor four of our cases were reported in females and was not associated with any habit history.

Eventhough age of occurrence of AdCC have been differently reported among different authors, none of them reported in younger ages, 2<sup>nd</sup> decades. But one of these cases occurred in a 20-year-old female patient in a relatively uncommon site, parotid gland.

Pain and swelling are considered as the most common presenting symptoms, that make

patient to seek medical help and pain is considered as an important finding. Here also four of these patients presented with swelling. Among the five cases, one patient was reported with pain and histopathology of the same lesion revealed perineural invasion by tumor cells.

Eventhough AdCC has been described as a tumor with apparently indolent course, it has an aggressive long-term behaviour, with metastases on later stages and persistent and recurrent growth pattern. All these factors lead to eventual death of the patient<sup>[9]</sup>. It has been described as 'one of the most biologically destructive and unpredictable tumors of the head and neck'<sup>[10]</sup>

Radiographically, tumors arising in the palate or maxillary sinus often show evidence of bone destruction. Bone invasion may occur without radiographic changes as the tumor infiltrates through the marrow spaces. One of the cases showed extensive destruction of the maxilla with floating teeth appearance. Other cases were not associated with a significant bone destruction or erosion.

Histopathologically, adenoid cystic carcinoma is composed of a mixture of myoepithelial cells and ductal cells with different patterns of proliferations. Three major patterns are recognized: (1) cribriform, (2) tubular, and (3) solid. Usually, a combination of these is seen, and the tumor is classified based on the predominant pattern<sup>[1]</sup>

Microscopically, AdCC carry a strong accent of uniformity. Typical "Swiss cheese" pattern is composed of small cells that take a deep-blue stain and have scanty cytoplasm. The punched-out zones are round and usually contain some pale-staining amorphous material. Eventhough AdCC shows uniformity in their morphology, close examination may reveal striking differences among tumors and also among various zones in a single tumor

AdCC characteristically grow in solid sheets devoid of connective-tissue trabeculation, in large tissue clumps that sometimes have necrotic centers or in an almost alveolar pattern with extensive connective-tissue trabeculation

The tissue response is different in different tumors. The edges may be completely smooth and free of reaction or there may be large sheets of fibrous tissue. All variations between these extremes are seen.

Overlying mucous membrane usually appears to be intact. In some zones, the tumor apparently is derived from the basal layer of the lining membranes

In addition to the "typical" picture of the deep-blue, round, cells with scant cytoplasm,



variation are also noted in the cytomorphology including nuclear and cellular pleomorphism, abnormal mitotic figures and spindle morphology. Some of the cells palisade around the lumens whereas some do not. The cells grow in solid sheets almost devoid of lumens, or in a single layer around large quantities of hyaline material, or as a double-celled layer around uniformly small and large lakes of thick or thin hyaline material, or in any variations thereof.

**Hyaline Element:** It is an amorphous noncellular material contained in the spaces of the tumor. It is sometimes extremely hyaline in appearance, but occasionally it is foamy, sometimes dense and may appear to be the dominant element, but it is often so thin as to be apparently non-existent.<sup>[11]</sup>

Perineural, and to a lesser extent, the intraneural invasion is a common and frequently conspicuous feature of AdCC. Tumors can extend along nerves for a considerable distance beyond the clinically apparent boundaries of the tumor. Perineural invasion (PNI) is grouped into two categories as incidental and clinical.<sup>[12]</sup>

All the five tumors of the present series showed basaloid cells with scant cytoplasm with hyperchromatic nuclei forming cribriform architecture with mucoid material within the lumen and tubular and solid pattern of tumor cells are also noted. The connective tissue in all of these cases were fibrovascular with mild inflammatory response. Retraction of tumor islands from the stroma is also noted. Perineural invasion by the tumor cells noted in two of the cases and perivascular invasion noted in one case. All the cases were confirmed as AdCC with histopathology alone.

All the five cases were referred to RCC for further management. Till today no recurrence were reported.

### III. CONCLUSION

Early diagnosis of AdCC is very important because of the high potential of recurrence and distant metastasis. The diagnosis of the AdCC can be late due to its slow growing potential and lack of symptoms. Clinical appearance of the lesion may mix with other lesions, may mimic a benign lesion. Disease specific survival is 89% at 5 years but only 40% at 15 years. FNAC may not be confirmatory, but can assist the pathologist to some extent. Histopathology is the gold standard for diagnosis and definitive diagnosis will guide the clinician to apply the right treatment modality.

### REFERENCE

- [1]. Oral and Maxillofacial Pathology . Neville, Damm, Allen, Bouquot.pdf.
- [2]. Yaga US, Gollamudi N, Mengji AK, Mengji AK, Besta R, Panta P, et al. Adenoid cystic carcinoma of the palate: case report and review of literature. Pan Afr Med J [Internet] 2016 [cited 2022 Jul 30];24. Available from: <http://www.panafrican-med-journal.com/content/article/24/106/full/>
- [3]. Datta. Adenoid cystic carcinoma of palate: A unique case report [Internet]. [cited 2022 Jul 30]; Available from: <https://www.jiaomr.in/article.asp?issn=0972-1363;year=2022;volume=34;issue=1;page=116;epage=119;aulast=Datta>
- [4]. Spiro RH, Huvos AG, Strong EW. Adenoid cystic carcinoma: Factors influencing survival. The American Journal of Surgery 1979;138(4):579–83.
- [5]. Srivastava AC, Barpande SR, Bhavthankar JD, Mandale MS. Adenoid cystic carcinoma of palate: Report of a solid variant. J Oral Maxillofac Pathol 2018;22(Suppl 1):S65–8.
- [6]. Diagnostic histopathology of tumors- Christopher D. M Fletcher.pdf.
- [7]. Shafer WG, Hine MK, Levy BM. A textbook of oral pathology. 4th ed. Philadelphia: Saunders; 1983.
- [8]. Kapoor C, Ohri N, Vaidya S. Adenoid cystic carcinoma of hard palate: Case report with emphasis on diagnostic approach. Saudi J Health Sci 2015;4(1):65.
- [9]. Spiro RH. Salivary neoplasms: Overview of a 35-year experience with 2,807 patients. Head Neck 1986;8(3):177–84.
- [10]. Conley J, Dingman DL. Adenoid Cystic Carcinoma in the Head and Neck (Cylindroma). Archives of Otolaryngology - Head and Neck Surgery 1974;100(2):81–90.
- [11]. Tauxe WN, McDonald JR, Devine KD. A Century of Cylindromas: Short Review and Report of 27 Adenoid Cystic Carcinomas Arising in the Upper Respiratory Passages. Archives of Otolaryngology - Head and Neck Surgery 1962;75(4):364–76.
- [12]. Speight P, Barrett A. Salivary gland tumours: **Salivary gland tumours**. Oral Diseases 2002;8(5):229–40.