



Aspiration followed by Triamcinolone and Hyaluronidase Injection in Treatment of Ganglion Cyst of the Wrist: A Case Series

Dr Debayan Chowdhury¹, Dr Shivaji Mandal²

¹3rd Year DNB Post Graduate Trainee, Department of General Surgery, Vivekananda Institute of Medical Sciences, Kolkata, West Bengal, India

²Assistant Professor, Department of General Surgery, Vivekananda Institute of Medical Sciences, Kolkata, West Bengal, India.

Corresponding Author: Dr Debayan Chowdhury

Submitted: 10-02-2022

Revised: 22-02-2022

Accepted: 25-02-2022

ABSTRACT:

Background: Wrist Ganglion cyst cases commonly present in the general surgery outpatient department. Main concern is the cosmesis or symptoms, that can be managed by various means starting from observation to surgery, with sclerotherapy as a popular option. A successful sclerotherapy and regression of the cyst gives a potential alternative to surgery.

Materials and Methods: This study was carried out in the Department of General Surgery, Ramakrishna Mission Seva Pratishthan, Vivekananda Institute of Medical Sciences, Kolkata, between June 2020 to Dec 2021. Twenty patients with wrist ganglion with varying age, sex, site of the cyst, whether receiving any previous treatment, was treated by aspiration of cyst material followed by sclerotherapy with triamcinolone and hyaluronidase injection, for several sittings with 14 days interval. They were followed up for once 12 weeks later after the disappearance of the swelling after their respective last cycles. Failure of treatment was defined as persistence of swelling even after 6 cycles.

Results: We evaluated 20 patients (12 females and 8 males) with wrist ganglion cysts. 10%, 35%, 35%, 15% and 5% ganglion cysts resolved after 2, 3, 4, 5 and 6 cycles of sclerotherapy respectively. Only 1 developed a complication of skin hypopigmentation. None had recurrence on follow up visit at 12 weeks after their last sclerotherapy. There were no cases of treatment failure.

Conclusion: Intralesional injection of sclerosant (Triamcinolone and Hyaluronidase) may be considered as a safe, convenient, economical and less invasive alternative to surgical excision of ganglion cysts of wrist.

KEYWORDS: Ganglioncyst, Sclerotherapy, Triamcinolone, Hyaluronidase.

I. INTRODUCTION

Ganglion cysts are among the most common tumours of the hand and wrist¹ and constitute 50-70% of all soft tissue tumours of the hand and wrist². They are more common between the 2nd and 4th decade of life and in the female gender³. Wrist ganglia commonly develop at the dorsal and palmar-radial aspects of the wrist⁴. The cyst may be asymptomatic or cause local pain that is exacerbated with wrist movement. The diagnosis is usually made by clinical examination and confirmed with ultrasound⁵.

Ganglion cysts contain a thick, clear, mucous-like fluid similar to the fluid found in joints. The ganglion capsule is formed from compressed stroma, with no cellular lining, and may be linked to the underlying joint capsule by a narrow channel that functions as a one-way valve. The etiology of ganglions is unknown. Theories include mucoid degeneration and trauma (<10%)⁶.

There are several treatment options for ganglion cysts – observational, aspiration of the cyst fluid – with or without sclerotherapy or corticosteroid infiltration, trans-fixation with silk suture, transcutaneous electrocautery and surgical excision by either open or arthroscopic method^{3,5,7,8,9,10}. Historically, bursting of the ganglion by manually humping with a heavy book (traditionally “the Bible”) was a popular method¹¹.

Open or arthroscopic surgical excision has a cure rate of 70-100%¹². However, they are invasive and have a higher rate of complications^{1,13}. Conservative treatment has a cure rate of 20-30%¹³.

Few sclerosing agents have been studied for treatment of ganglion cysts of the wrist – hypertonic serum¹⁴, 3% povidocanol¹⁵, hyalurocyl¹, triamcinolone¹, sodium tetradecyl sulfate¹, 75% hypertonic glucose¹⁶.



We report a case series where we performed aspiration of cyst fluid followed by sclerotherapy with injection triamcinolone and

II. CASE PRESENTATIONS

20 cases were examined, mostly presented with an asymptomatic visible cystic swelling in the wrist, while 8 presented with occasional pain in the wrist with activity. On inspection, the swelling is transilluminant, with no local signs of inflammation. On palpation, it is a firm cystic swelling, well circumscribed, free from overlying skin, but often fixed to the deeper tissue with mobility perpendicular to the direction of the tendon but no mobility along the axis of the tendon.

III. MATERIALS AND METHODS

Study Design: This study is a case series, a prospective, longitudinal, interventionist study.

Study Location: Outpatient Department of General Surgery, Ramakrishna Mission Seva Pratishthan, Vivekananda Institute of Medical Sciences, Kolkata, West Bengal, India.

Study Duration: 1st June 2020 to 31st December 2021.

Sample Size: 20

Inclusion Criteria:

- 1) Both male and female patients
- 2) Age \geq 18 years and \leq 60 years
- 3) Both dorsal or ventral aspect wrist ganglion cysts

hyaluronidase mixed together, in 20 cases of wrist ganglion cyst.

Exclusion Criteria:

- 1) Patients who refused consent
- 2) Patients with previous history of any treatment
- 3) Patients with diabetes mellitus
- 4) Infected ganglion
- 5) Ganglion at other sites
- 6) Ganglion associated with arthritic disorder

Diagnosis: By Clinical Examination and confirmed by USG.

Materials:

10 cc and 5 cc syringes with 21G needle, Injection Triamcinolone 40 mg (InjKenacort 1 ml), Injection Hyaluronidase 1500 IU (InjHynidase in powder form).

Procedure Methodology:

The procedure was carried out on an out-patient basis under all aseptic conditions.

Step 1: Injection Kenacort 1ml, was mixed with hynidase powder 1500 IU and the mixture was kept aspirated in a 5cc syringe. (**Fig 1**).

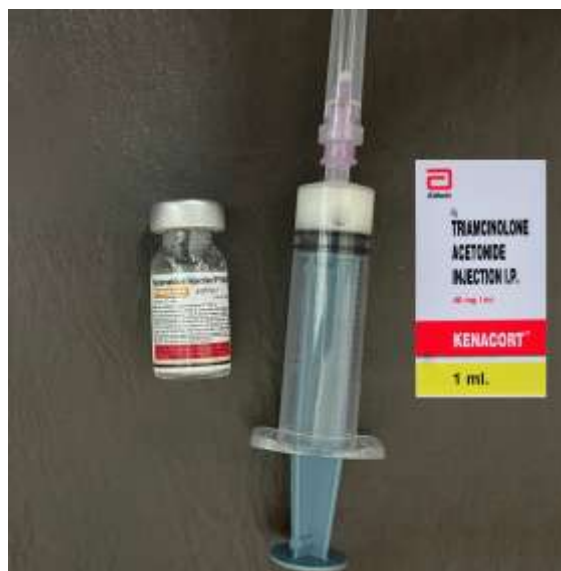

Fig 1: Injection Kenacort and Hynidase mixed together and kept aspirated in a syringe.

Step 2: Maintaining asepsis, the ganglion cyst wall was punctured with a 21G needle attached to a 10cc syringe and the gelatinous cyst fluid was aspirated

from the lateral aspect with a gentle external counter pressure over the cyst so as to aspirate the fluid completely. (**Fig 2,3**).

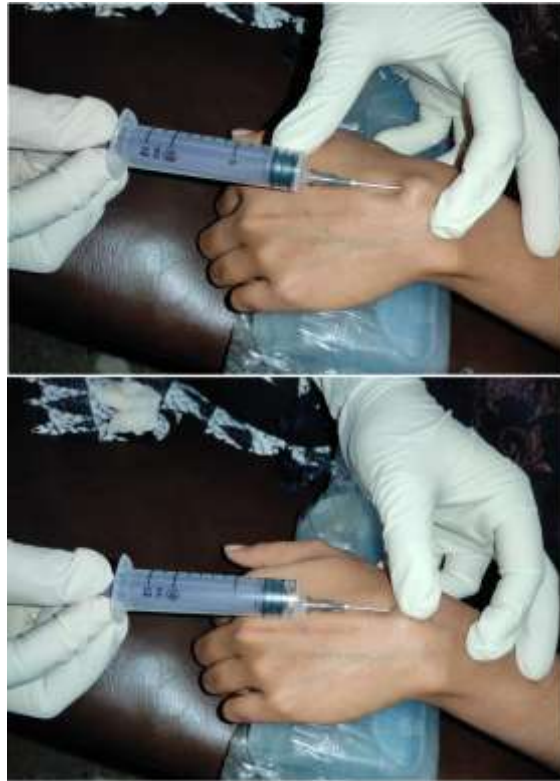

Fig 2: Procedure of cyst wall puncture and aspiration of cyst fluid by counter pressure.



Fig 3: The aspirated gelatinous cyst fluid



Step 3: Keeping the 21G needle in place, inside the cyst cavity, the 10cc syringe was detached from the needle (**Fig 4**), and the 5cc syringe with the sclerosant mixture (Kenacort + Hynidase) was

connected to the needle, and the sclerosant was injected into the cyst cavity, equal to the amount of fluid that was aspirated, so that the swelling reappeared (**Fig 5**).

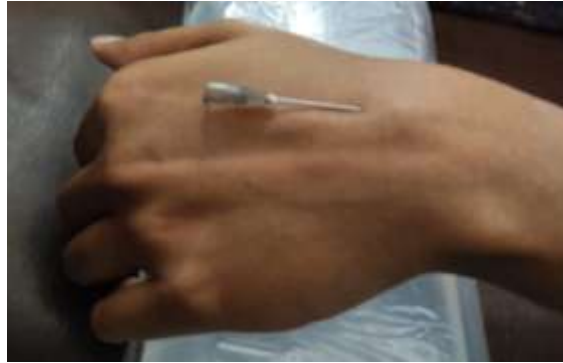

Fig 4: The 10 cc syringe detached from the needle keeping the needle inside the cyst cavity.

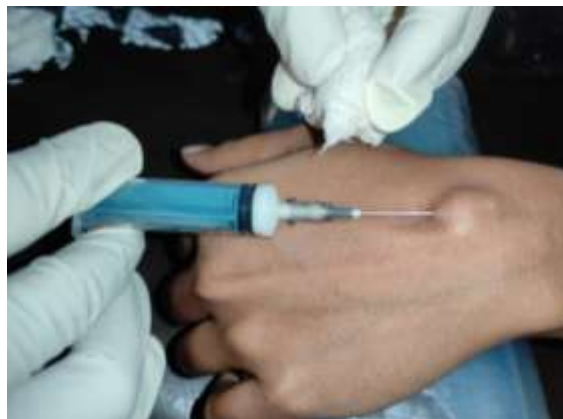

Fig 5: The Kenacort + Hynidase mixture was injected into the cyst cavity.

Step 4: The needle was taken out and compression bandage was applied (**Fig 6**).

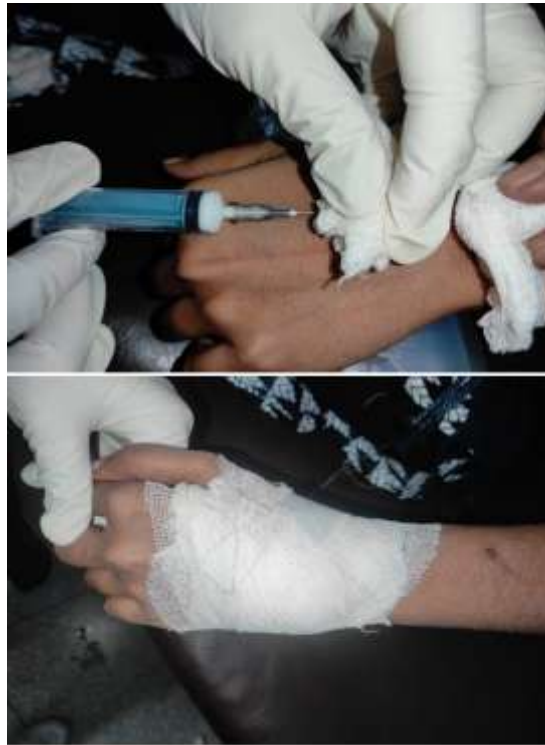

Fig 6: The needle with syringe was taken out and compression bandage applied with gauze and roller bandage.

Patient was advised to remove the bandage after 48 hours and keep it open hence. Patients were advised to review after 14 days at OPD. A repeat cycle of aspiration and sclerotherapy was done after every 14 days if the swelling did not regress in size. Once the swelling regressed and disappeared, treatment was considered completed.

Treatment Failure: Failure of treatment was defined as persistence of swelling even after 6 cycles of sclerotherapy.

Follow Up: After treatment was complete, the patient was advised to follow up once after 3 months. Any complication or recurrence was noted.

IV. RESULTS

Out of 20 patients who were included in the study, 60%(n=12) were females and 40%(n=8) were males.

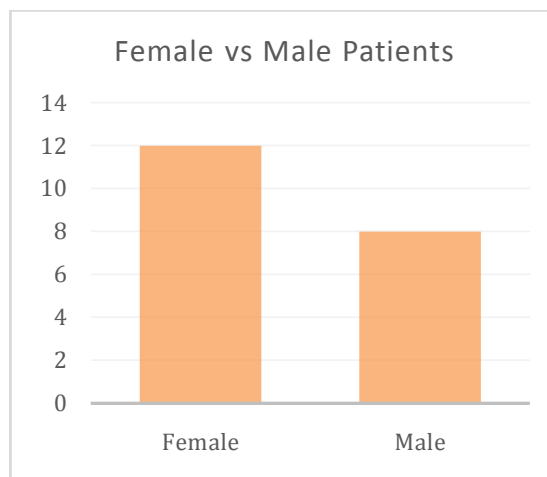


Fig 7: Number of male and female patients with wrist ganglion.



Age of the patients vary between 17 to 58 years, with maximum occurrence in the age group of 31-40 years. 5% patients lie in age group of 11-

20 years, 25% lie in 21-30 years age group, 30% in 31-40 years group, 20% in 41-50 years group and 20% in 51-60 years group.

Age group (years)	Number of patients	Percentage
11-20	1	5%
21-30	5	25%
31-40	6	30%
41-50	4	20%
51-60	4	20%

Table 1: Number and percentage of patients in different age groups.

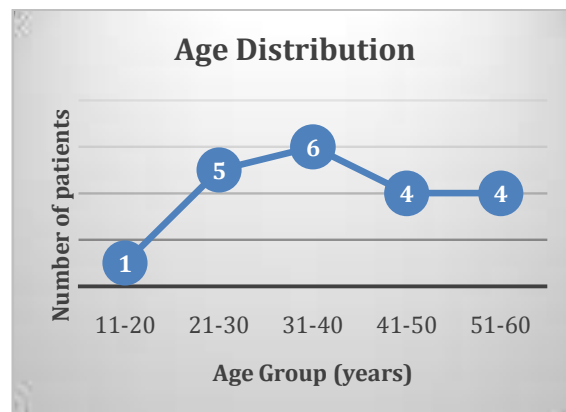


Fig 8: Age Distribution of the patients with wrist ganglion.

Out of all the patients, 55%(n=11) had the ganglion cyst in their right wrist, while 45%(n=9) had it in their left wrist.

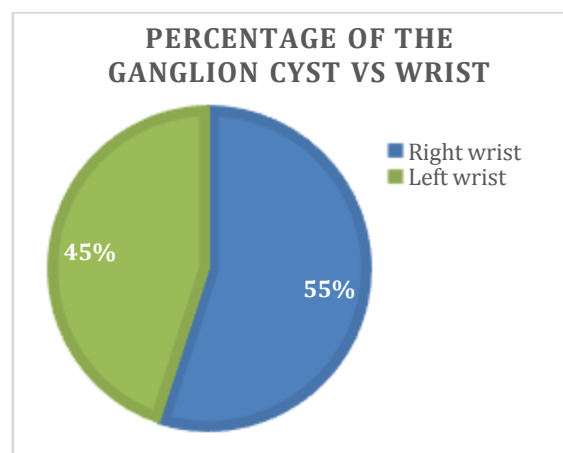


Fig 9: Percentage of patients with ganglion cyst in right vs left wrist.



65%(n=13) ganglion cysts were present in the dorsal aspect of the wrist, while 35%(n=7) cysts were present in the volar aspect of the wrist.

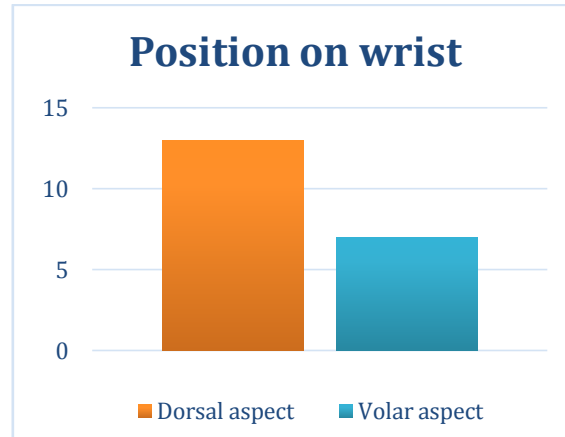


Fig 10: Number of ganlion cysts in dorsal vs volar aspect of the wrist.

Out of 20 cases, 90%(n=18) cysts were globular in shape, with size of the diameter ranging from 1.5 cm to 2.8 cm. 10%(n=2) were elongated in shape, with size 3x1.5cm and 2.8x1.2cm.

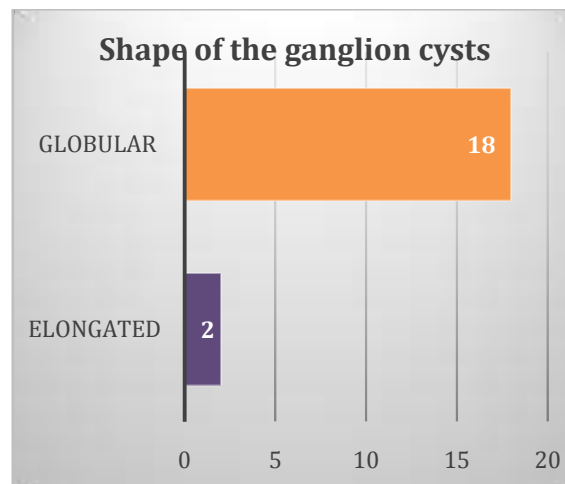


Fig 11a: Number of globular vs elongated shaped ganglion cysts.

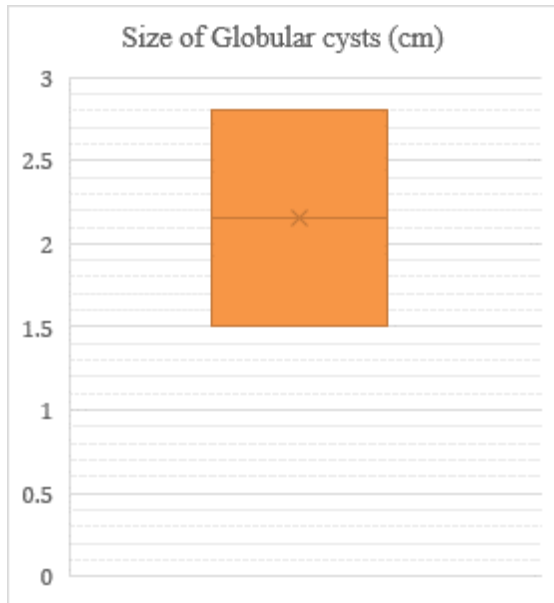


Fig 11b: Size distribution of globular cysts.

10% (n=2) ganglion cysts disappeared after 2 cycles of sclerotherapy, 35%(n=7) cysts resolved after 3 cycles, 35%(n=7) cysts resolved after 4 cycles, 15%(n=3) cysts resolved after 5 cycles and 5%(n=1) cysts resolved after 6 cycles of sclerotherapy.

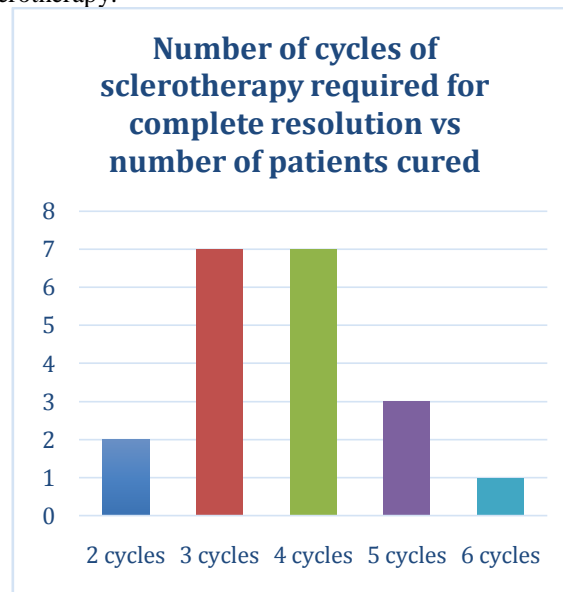


Fig 12a: Number of cycles of sclerotherapy required for resolution of the ganglion cyst to the number of patients cured by it.

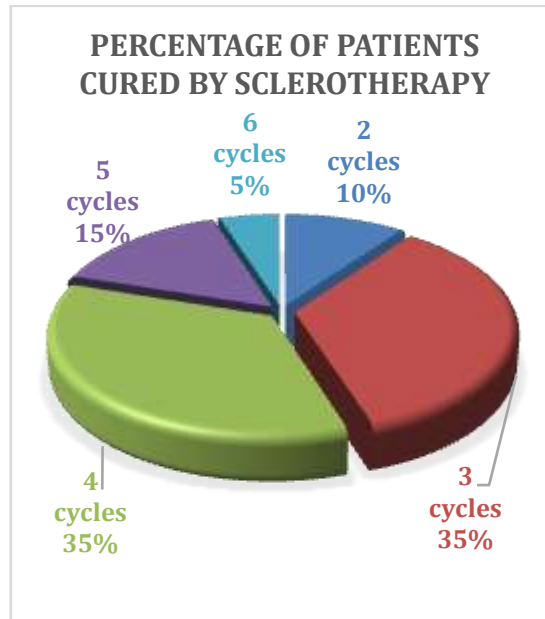


Fig 12b: Percentage of patients being cured by the number of cycles of sclerotherapy.

Out of 20 patients, only 5% (n=1) developed whitish discolouration of the skin overlying the ganglion cyst.

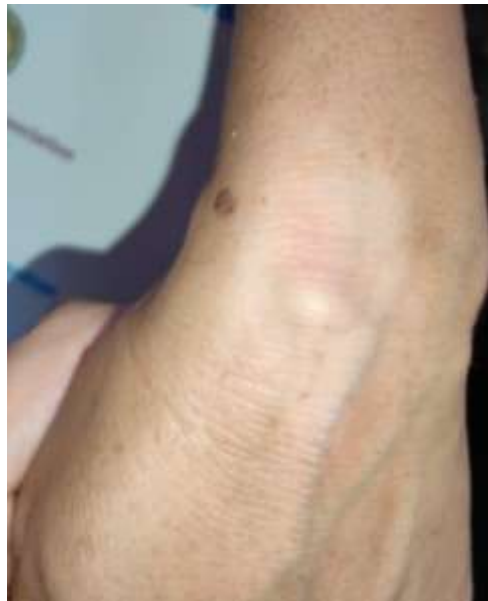

Fig 13: Whitish discolouration of the skin overlying the ganglion cyst, noticed during her 3rd cycle sclerotherapy.

All the patients were followed up once after 12 weeks of their respective final cycles of sclerotherapy i.e. the cycle after which the swelling resolved or disappeared. None noted to have

V. DISCUSSION

We included 20 cases of wrist ganglion cases in our study, a number comparable to other related studies like by Mackie et al¹⁷(16 patients) and Pires et al¹⁶(15 patients).

developed a recurrence. There were no cases of treatment failure in the above 20 cases.

In our study, occurrence of wrist ganglion cysts was found higher in females, with female:male ratio being 1.5:1. Paramhans et al⁵ and Kulinski et al³ also found a higher incidence of cysts in women. In Paramhans et al study, female: male



ratio was 2.04:1, while in Kulinski et al study, the ratio was 2.8:1.

Age range in our study was 17-58 years with highest incidence between 30-40 years, while in Paramhans et al⁵ study was age range was 16-58 years with highest incidence between 20-30 years.

In our study, right arm or the dominant arm was the most affected with ganglion cysts. Kulinski et al³ also found that right hand was affected more often with ganglion cysts.

Paramhans et al⁵ stated that ganglion cysts are more common in the dorsal topography of the wrist. Most of the patients in our study, also presented with ganglion cysts in the dorsal aspect of the wrist.

Diagnosis of the ganglion cyst in our study was done by clinical examination which was confirmed by ultrasound examination of the swelling as in Paramhans et al⁵ study.

In literature, there has been several studies on sclerotherapy of ganglion cysts with several types of sclerosants, but none had used a mixture of triamcinolone and hyaluronidase for sclerotherapy, as in our study. So, our study is unique.

Hyaluronidase probably acts by improving liquefaction of the gelatinous content of the cyst¹⁸. Recurrence rate after hyaluronidase sclerotherapy is reported to be approximately 25%¹⁹. Triamcinolone, when injected in the cyst cavity, lies in close contact with mucin-secreting mesenchymal cells of the cyst lining, arresting the secretion of gelatinous fluid into the cavity²⁰.

Recurrence rate after triamcinolone sclerotherapy is reported to be approximately 8.4% within 6 months of the sclerotherapy procedure⁵.

Chatterjee et al¹ in 2014, published recurrence rates of 20%, 31% and 35%, respectively, using triamcinolone, hyaluronidase and sodium tetradecyl sulfate. In our study, we followed up the patients for once, after 12 weeks of their respective last cycle of sclerotherapy which resolved their ganglion cyst. None was found to have a recurrence after 12 weeks.

Majority of the ganglion cysts resolved on 3 or 4 cycles of sclerotherapy (35% with 3 cycles and 35% with 4 cycles) with triamcinolone and hyaluronidase mixture. There were no cases of failure of treatment in our study. Chatterjee et al¹ in his randomized study, reported to have conducted up to three procedures, but not informing the number of procedures in each cyst. They repeated sclerotherapy cycles every 3 months. In our study, we repeated sclerotherapy cycles every 14 days.

Chatterjee et al¹ reported wrist stiffness with the use of triamcinolone, hyaluronidase and sodium tetradecyl sulfate. In our study, there were

no cases who developed wrist stiffness or decrease in range of motion except for 1 patient who developed depigmentation of the skin over the ganglion cyst after sclerotherapy. Varley et al²¹ also reported aspiration with infiltration of corticosteroid leading to skin hypopigmentation.

Surgical treatment is often associated with grave consequences such as wrist stiffness, pain, and swelling of the hand. There is also evidence of damage to the superficial branch of the radial nerve and palmar cutaneous branch of the median nerve while performing excision of a simple ganglion cyst²². Injection sclerotherapy is a good alternative with few side effects.

VI. CONCLUSION

Ganglion cysts of the wrist are common presentation in the surgical OPD. Treatment options are either sclerotherapy or surgery. Several sclerosant agents have been used in literature but none used a mixture of Triamcinolone and Hyaluronidase. Our study proved that aspiration followed by intralesional injection of sclerosant (Triamcinolone and Hyaluronidase) may be thus considered as a safe, convenient, economical and less invasive alternative to surgical excision of ganglion cysts of wrist, with fewer side effects, and recurrence rates as compared to surgery or to other sclerotherapy agents.

REFERENCES

- [1]. Chatterjee S, Basu A, Gupta S, Biswas S. Comparative study of recurrence and complications using various sclerosants by single dart technique in treatment of ganglion cysts. *Indian J Surg*. 2014 Oct;76(5):350–353.
- [2]. Ajekigbe L, Stothard J. The effectiveness of sodium tetradecyl sulfate in the treatment of wrist ganglia. *Can J Plast Surg*. 2006 Spring;14(1):28–30.
- [3]. Kulinski S, Gutkowska O, Mizia S, Gosk J. Ganglions of the hand and wrist: retrospective statistical analysis of 520 cases. *Adv Clin Exp Med*. 2017 Jan-Feb;26(1):95–100.
- [4]. Clay NR, Clement DA. The treatment of dorsal wrist ganglia by radical excision. *J Hand Surg Br*. 1988 May;13(2):187–191.
- [5]. Paramhans D, Nayak D, Mathur RK, Kushwah K. Double dart technique of instillation of triamcinolone in ganglion over the wrist. *J Cutan Aesthet Surg*. 2010 Jan-Apr;3(1):29–31.
- [6]. Burke FD, Melikyan EY, Bradley MJ, Dias JJ. Primary care referral protocol for wrist



- ganglia. *Postgrad Med J.* 2003 Jun;79(932):329-331.
- [7]. Gumus N. A new sclerotherapy technique for the wrist ganglion: transcutaneous electrocauterization. *Ann Plast Surg.* 2009 Jul;63(1):42-44.
- [8]. Ho PC, Griffiths J, Lo WN, Yen CH, Hung LK. Current treatment of ganglion of the wrist. *Hand Surg.* 2001 Jul;6(1):49-58.
- [9]. Barnes WE, Larsen RD, Posch JL. Review of ganglia of the hand and wrist with analysis of surgical treatment. *Plast Reconstr Surg.* 1964 Dec;34:570-578.
- [10]. Limpaphayom N, Wilairatana V. Randomized controlled trial between surgery and aspiration combined with methylprednisolone acetate injection plus wrist immobilization in the treatment of dorsal carpal ganglion. *J Med Assoc Thai.* 2004 Dec;87(12):1513-7.
- [11]. Nelson CL, Sawmiller S, Phalen GS. Ganglions of the wrist and hand. *J Bone Joint Surg Am.* 1972 Oct;54(7):1459-64.
- [12]. Suen M, Fung B, Lung CP. Treatment of ganglion cysts. *ISRN Orthopaedics.* 2013 May 28;2013:940615(7 pages). doi:10.1155/2013/940615.
- [13]. Athanasian EA. Bone and soft tissue tumors. In: Wolfe SW, Hotchkiss RN, Pederson WC, Kozin SH, Cohen MS, editors. *Green's operative hand surgery.* 7th ed. Amsterdam. Elsevier; 2016.
- [14]. Dogo D, Hassan AW, Babayo U. Treatment of ganglion using hypertonic saline as sclerosant. *West Afr J Med.* 2003 Jan-Mar;22(1):13-14.
- [15]. Hernández Espinosa OA, Sasturain Miranda ME, Labrada Blanco PO. Uso de polidocanol en el tratamiento conservador del ganglión del carpo. *Rev Cubana Ortop Traumatol.* 1997;11(1-2):37-40.
- [16]. Pires FA, Santos JBGD, Fernandes CH, Nakashima LR, Faloppa F. Sclerotherapy with 75% hypertonic glucose to treat dorsal synovial cysts of the wrist. *Acta Ortop Bras.* 2021 Mar-Apr;29(2):101-104.
- [17]. Mackie IG, Howard CB, Wilkins P. The dangers of sclerotherapy in the treatment of ganglia. *J Hand Surg Br.* 1984 Jun;9(2):181-184.
- [18]. Jagers Op Akkerhuis M, Van Der Heijden M, Brink PR. Hyaluronidase versus surgical excision of ganglia: a prospective, randomized clinical trial. *J Hand Surg Br.* 2002 Jun;27(3):256-8.
- [19]. Westbrook AP, Stephen AB, Oni J, Davis TR. Ganglia: the patient's perception. *J Hand Surg Br.* 2000 Dec;25(6):566-567.
- [20]. Colberg RE, Sanchez CF, Lugo-Vicente H. Aspiration and triamcinolone acetone injection of wrist synovial cysts in children. *J Pediatr Surg.* 2008 Nov;43(11):2087-2090.
- [21]. Varley GW, Needoff M, Davis TR, Clay NR. Conservative management of wrist ganglia aspiration versus steroid infiltration. *J Hand Surg Br.* 1997 Oct;22(5):636-637.
- [22]. Edwards SG, Johansen JA. Prospective outcomes and associations of wrist ganglion cysts resected arthroscopically. *J Hand Surg Am.* 2009 Mar;34(3):395-400.
- [23].