



## Assessment of severity of hypoxic ischemic encephalopathy using spectroscopy as an imaging modality

Irshad Ahmad Paul

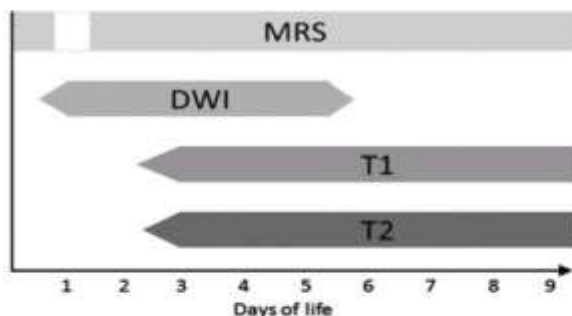
Submitted: 01-07-2022

Accepted: 08-07-2022

### INTRODUCTION

Neonatal hypoxic encephalopathy, is characterized by clinical and laboratory evidence of acute or subacute brain injury manifested by difficulty with initiating and maintaining respiration, depression of tone and reflexes, subnormal level of consciousness and often by seizures.<sup>(1)</sup>HIE is the most important cause of neurological morbidity and mortality in term neonates.<sup>(2)</sup>It accounts for 23% of 4 million neonatal deaths worldwide.<sup>(3)</sup> It is an important cause of cerebral palsy and associated disabilities in children. Early diagnosis of hypoxic-ischemic encephalopathy (HIE) is particularly important in the immediate postnatal period, when decisions about the provision of active life support must be made. Clinical confirmation of ischemic damage is often difficult at this time, when the neonate may present with nonspecific clinical features, such as seizures, hypotonia, or lethargy.<sup>(4)</sup> Two main patterns of HIE have been described in term neonates : peripheral (cortical/ subcortical) and central (basal ganglia- thalamus) with predominant pattern dependent on duration and severity of ischemia/hypoxia. The peripheral pattern occurs in the setting of mild hypoxia or ischemia of prolonged duration with predominant findings in the cerebral cortex and subcortical white matter along the intervascular boundary zones. The central pattern is secondary to more severe hypoxic or ischemic event of short duration predominantly affecting posterolateral putamen, ventrolateral thalami and corticospinal tracts. There are several methods for the diagnosis of asphyxia, including electrophysiological tests like amplitude electroencephalography (EEG), brain stem auditory evoked potentials (BAEP), visual evoked potentials (VEP), and somato-sensorial evoked potentials (SEP).<sup>(5)</sup>

Of the imaging modalities available, MR imaging is the most sensitive and specific imaging technique to assess perinatal asphyxia associated brain injury in full term neonates.<sup>(6)</sup> MRI provides early detection to initiate preventive measures, assess the severity of tissue injury and serves as a prognostic indicator. Diffusion weighted MR imaging performed with apparent diffusion coefficient maps between 24 hours and 8 days of life is more sensitive for detection of cytotoxic edema as it reveals restricted diffusion with reduced ADC values earlier than the signal intensity abnormalities are evident on conventional T<sub>1</sub> or T<sub>2</sub> images. DW imaging becomes falsely negative approximately one week after the hypoxic or ischemic event, a phenomenon known as pseudonormalization. MRS is a quantitative, non invasive method of detecting energy metabolism disturbances and measure intracerebral metabolites in vivo. <sup>(7)</sup> It has a definite use in accurate prediction of adverse outcome in newborn with encephalopathy secondary to perinatal asphyxia mainly when performed near the hypoxic-ischemic event and has been shown to be more predictive of long term neurodevelopment outcome than conventional MR and diffusion.<sup>(8)</sup>. Limited studies have suggested the potential utility of proton MRS for the evaluation of brain injury in asphyxiated neonates. <sup>(9-12)</sup>, therefore we decided to study the potential utility of proton MRS along with DWI in assessing the hypoxic ischemic encephalopathy in term neonates.



**Figure-1:** Optimal time to perform each imaging technique. Proton MR Spectroscopy (MRS) is most sensitive in the first 24 hours after injury, particularly since diffusion-weighted. T1-, and T2-weighted images may yield false-negative results. However, lactate levels may fall to normal at approximately 24 hours, with pseudonormalization (White Square) of MR spectra and false negative MR spectroscopy findings if images are interpreted in this time frame. At 24 hours after an asphyxic event, DW imaging is the most sensitive technique. A secondary rise in lactate levels, known as secondary energy failure, occurs after 24-48 hours, at which time the sensitivity of MR spectroscopy return. DW imaging is most optimal 1-5 days after injury, after which pseudonormalization occurs. T1- and T2-weighted imaging is most sensitive after 2-3 days.

## MATERIALS AND METHODS

This was a prospective longitudinal study conducted over 2 years (August 2017 to August 2019) at our institute. Term neonates with gestational age of  $\geq 37$  weeks and suspected of having intrapartum hypoxic-ischemic injury and admitted in the neonatal intensive care were enrolled in the study and submitted to routine MR study, DWI and MR spectroscopy. The clinical data were obtained from hospital charts and include information about pregnancy, labor condition, Apgar score at 1 and 5 minutes and gestation. Exclusion criteria were severe brain malformations, and congenital or acquired central nervous system infections. The study was approved by the Ethics committee of the institute and parental consent was taken for participation in the study.

Sedation was given either by oral chloral hydrate or intravenous midazolam. All studies were performed using circularly polarized head coil in a 1.5 T MR imaging system (Magnetom Avanto, Siemens Medical System). The MR imaging protocol included axial and coronal T2 sequences (repetition time [TR]= 3500 ms, echo time [TE]=110 ms, flip angle=150°), fast fluid-attenuated inversion recovery (TR= 9000 ms, TE=97 ms, flip angle=150°), and diffusion (TR=3200ms, TE=99ms), followed by axial and coronal T1 sequences (TR=450ms, TE=10 ms, flip angle=90°).

An echo planar imaging technique was used for DWI. 180x180 mm FOV; 4mm thickness section, 0 mm section gap, b factors 0 and 1000 sec/mm<sup>2</sup>. Mean ADC values were derived from isotropic ADC maps in the two standard locations; putamen and thalamus and anterior and posterior subcortical watershed areas and mean ADC were calculated. ROI were circled with a mean area of 0.18 cm<sup>2</sup>.





The spectroscopy was performed using 2D chemical shift point resolved spectroscopy (TR=1500 ms, TE=135 ms, field of view 120x120 mm, flip angle 90°, and 16x16 phase encoding steps). The field of view with nominal voxel size of 7.5 x 7.5 x 15 mm was located in the basal ganglia and thalami bilaterally and in fronto-parietal intervascular boundary zone (watershed zone) without bone or CSF contact. Spectral post processing was analyzed using software Luise (Siemens Avanto, Medical System). The peak areas were integrated for choline, N-acetyl aspartate (NAA), and lactate resonances, and peak area ratios of lactate/choline and lactate/NAA were calculated for each voxel. The metabolite ratios of right and left sides were averaged for statistical analysis. First MRI was conventional MRI with DWI followed by multivoxel proton spectroscopy done within 72 hours of life. Ear protection was provided by ear muffs, heart rate and transcutaneous oxygen saturation were maintained with a pulse oximeter.

## RESULTS

A total of 25 patients, 14 males and 11 females admitted in neonatal intensive care, and diagnosed with HIE were included in this study. All of them were term neonates with median gestational age of 37 weeks 4 days and median birth weight of 3200 grams. Normal vaginal delivery occurred in 8 and 17 had cesarean deliveries. Immediately after birth, resuscitation was necessary in 18. With respect to encephalopathy grade, 14 were diagnosed with grade 1, 7 were diagnosed with grade 2, and 4 were diagnosed grade 3.

Out of 25 patients who were suspected of hypoxic encephalopathy based on clinical, neurological and laboratory features, 15 patients had early positive conventional MR findings (T1 hyperintensity in basal ganglia/thalami and watershed zone), 16 patients had positive late positive conventional MR findings (T1 hyperintensity in basal ganglia/thalami and watershed zone, with T2 hypointensity), 19 patients positive diffusion weighted imaging based on diffusion restriction with low ADC values, and 22 patients had positive MRS findings with high lactate/choline and lactate/NAA ratio.

The most common abnormality detected on DWI was diffusion restriction with low ADC values. The most consistently noted abnormality on MR spectroscopy was presence of variable sized lactate doublet peak centered at 1.31 ppm. The amount of lactate (determined by integration of lactate doublet) was small in those patients who had low

The statistical methods compared patients with HIE (neonatal encephalopathy) and abnormalities identified at conventional MR, DWI and MR-spectroscopy. Analysis between clinical and neurophysiological variables with spectroscopy, DWI, and conventional MR was performed by means of chi square test or Fischer's exact test. Associations between HIE grade and MRS ratios, DWI scores ADC ratios, and conventional MR findings were compared by ANOVA test. The adopted significance level was 0.05. All the tests were performed using statistical software SPSS (version 20.0) and Microsoft Excel

grades of clinical HIE. In contrast, lactate levels were higher in those patients in severe hypoxic brain injury. In those patients with central pattern of injury greater elevations of lactate were seen in basal ganglia and thalami than in the watershed zone. Patients with peripheral pattern of injury had greater elevations of lactate in the watershed zone than in basal ganglia or thalami regions. The peak area ratios of lactate /choline and lactate / NAA in both basal ganglia and watershed zones were compared with the grade of HIE that showed a significant association with p value of <0.05. No new or unexpected peaks were seen on MRS studies of any of the affected infant.

## DISCUSSION

MRI is considered to be the method of choice to assess brain injury in full term infants with perinatal asphyxia, and this technique reliably identifies the patients who are at risk of developing ischemic brain insult following hypoxia. In the present study we assessed the pattern of changes on conventional MRI, DWI, and MR-spectroscopy in the early neonatal period in term infants with perinatal asphyxia. Visual analysis was done for T1, T2 weighted images, and diffusion weighted images followed by measurement of ADC values and MRS peak ratios in basal ganglia /thalami and watershed zones. ADC values for both basal ganglia and watershed zones were compared with that of MRS peak ratios that showed significant association. The present study adds to existing knowledge by suggesting how visual evaluation and quantitative MRI data can be integrated to accurately assess patients with encephalopathy following ischemic brain insult.



In our study, we compared association between proton MRS spectroscopic measurements in term neonates with HIE based on clinical and neurological findings following perinatal asphyxia. The associations were compared with the findings of conventional and diffusion MR imaging with ADC. The combination of MR imaging score and ADC had a significantly better relationship with grades of HIE than did MR imaging alone. Our findings of association between ADC of basal ganglia and thalami and / or watershed zone with clinical and neurological findings are in agreement with those of several other studies. (10-12)

Our study reveals high significant association between results of proton MRS performed in the early neonatal period and hypoxic ischemia of term neonates. We found that lactate/choline and lactate/NAA ratios were strongly associated with grades of HIE consistent with Cady's discovery that choline levels are reduced and lactate levels are increased in human infants with hypoxic-ischemic injury. (13) It has been reported (14,15) that lactate levels of injured brain increase within first 24 hours and remain elevated after 24 hours, presumably because of energy failure and necessity to metabolize glucose anaerobically. Our present data are in agreement with several other studies and observations (16-19) showing higher lactate in basal ganglia and watershed zone of patients with HIE which is shown by increased lactate/choline and lactate/NAA ratio

Also our findings for lactate and NAA are in agreement with recent meta-analysis of MRS studies of basal ganglia/thalamic brain regions, indicating amongst the various possible metabolite ratios Lactate/NAA is the best biomarker for predicting adverse outcome after HIE. (20) Higher association was found between spectroscopic findings and hypoxic ischemic injury compared to MR imaging and ADC. Although the number of patients in the present study was relatively small, the data support that proton magnetic spectroscopy combined with ADC values performed within the first week of life, can be used to identify term neonates with high risk of developing encephalopathy secondary to hypoxic-ischemic brain injury and with normal magnetic resonance imaging.