



## Cerebrospinal fluid pseudocyst following ventriculoperitoneal shunt: A case report and review of literature.

Dr.Aritra Bhattacharjee, Dr.KBhuyan

PG student of surgery, Department of Surgery, Gauhati Medical College & Hospital, Guwahati, Assam

Professor of Surgery, Department of Surgery, Gauhati Medical College & Hospital, Guwahati, Assam

Submitted: 08-12-2022

Accepted: 16-12-2022

### ABSTRACT:

**INTRODUCTION:** Ventriculoperitoneal shunt (VPS) placement is an established procedure for the treatment of hydrocephalus in children and adults. An Abdominal pseudocyst of cerebrospinal fluid, a rare complication and usually occurs after a period of successful surgery. We report a case of abdominal pseudocyst following a VPS surgery.

**CASE DESCRIPTION:** A30 year-old female reported with abdominal distension of 2months duration with diffuse abdominal pain. The patient had a history of undergoing a VPS surgery 3 years earlier for hydrocephalus secondary to brain abscess. Abdominal computed tomography (CECT) revealed a homogeneous low-density multi loculated fluid collection with the tip of VPS catheter within the collection. A peritoneal pseudocyst around shunt catheter was suspected and laparotomy was performed. A large cystic mass covering whole of the abdomen extending into the pelvis with the fimbriae of right fallopian tube around was detected. The tip of the shunt was inside the cyst. The cyst was excised in toto and the distal end of the tip of VPS catheter was repositioned in the peritoneal cavity.

**DISCUSSION:** The cerebrospinal fluid pseudocyst is a rare complication of VPS surgery. It is characterized by the collection of cerebrospinal fluid in the peritoneal cavity containing the distal end of the VPS catheter in a cavity surrounded by fibrous tissue. **CONCLUSION:** The complication of peritoneal pseudocyst following a VP shunt may be considered in presence of abdominal distension.

**Key word:** VP shunt-Pseudocyst abdomen-excision-reposition.

### I. INTRODUCTION:

The procedure of Ventriculoperitoneal shunt (VPS) placement is performed to relieve intracranial pressure caused by hydrocephalus of in children and adults [1]. The incidence of cerebrospinal fluid pseudocyst is a rare complication of VPS surgery ranging from less than 0.25% to 10% [1]. It is characterized by the collection of cerebrospinal fluid in the peritoneal cavity containing the distal end of the VPS catheter in a cavity surrounded by fibrous tissue. This condition is rare in adult and mostly reported in children. We present here a case of cerebrospinal fluid pseudocyst in a 30 years old female after VPS operation performed 3 years earlier.

**CASE DESCRIPTION:** A 30 year-old female reported with abdominal distension of 2 months duration with diffuse abdominal pain. The patient had a history of undergoing a VPS surgery 3 years back for hydrocephalus secondary to brain abscess. The patient had history of headache and nausea and vomiting. Abdominal computed tomography (CECT) revealed a homogeneous low-density multi loculated fluid collection with VPS catheter tip within the collection [fig 1]. A peritoneal pseudocyst around shunt catheter was suspected and laparotomy was performed.

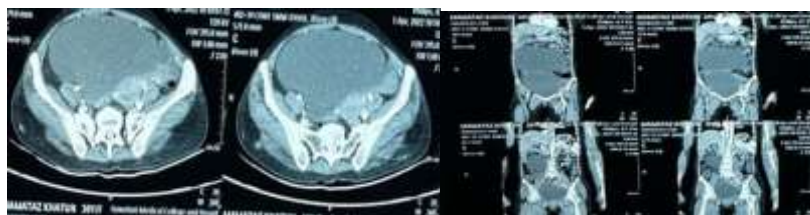

Fig 1 : CECT abdomen showing multiloculated homogenous mass.

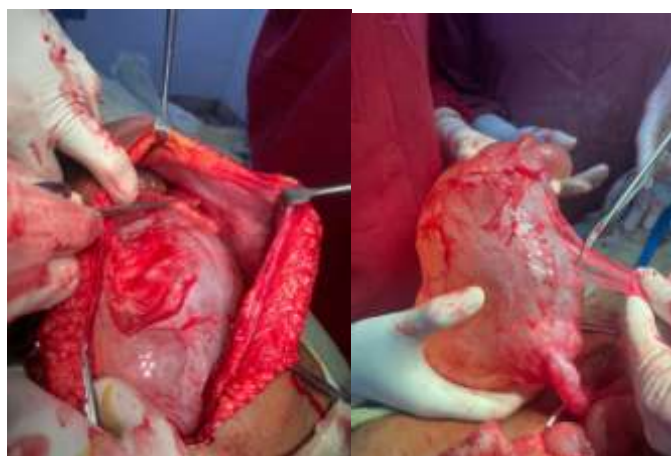


Fig 2

Fig 3

A large cystic mass (20X12X 10)cm covering whole of the abdomen extending into the pelvis with the fimbriae of right fallopian tube around the tip of the shunt catheter was found (Fig2,3) during the procedure. The tip of the shunt was inside the cyst cavity. The cyst was excised in toto and the distal end of the tip of VPS catheter was repositioned in peritoneal cavity. The fluid was clear in nature and the histopathology examination cyst wall showed CSF pseudocyst with fibro-collagenous wall with chronic inflammatory changes. The post operative recovery was uneventful.

## II. DISCUSSION:

Abdominal pseudocyst formation following VP shunt surgery is a rare complication of with the incidence ranging from 0.25% to 10%[1]. It is characterized by the collection of cerebrospinal fluid in the peritoneal cavity containing the distal end of the VPS catheter in a cavity surrounded by fibrous tissue. Abdominal complications related to VP shunt placement include pseudocysts both infected and sterile, abscess and bowel perforation. Abdominal pain is often the chief complaint in most patients accompanied by nausea and vomiting, which is often in absence of neurological signs[1,2]. The present case was reported with abdominal distension with history of nausea and vomiting. The underline mechanism for formation of CSF pseudocyst is unknown. Inflammation either sterile or infectious is regarded as main causative factor (2). The time between the last VPS surgery and collection of abdominal cerebrospinal fluid has been reported to range from 3 weeks to 10 years(2,3). The present case the VPS surgery was performed 3 years before this presentation. The diagnosis of pseudocysts is most accurately made by a contrast CT scan of the abdomen (1,2,3,4). It

differentiates abdominal abscess, lymphocele, seroma, cystic lymphangioma, cystic mesothelioma, mesenteric cyst, benign cystic teratoma, cystic spindle-cell tumour, pancreatic pseudocyst, and duplication cyst(5). Treatment algorithms of laparotomy with wide excision of cystic walls, paracentesis and aspiration of the cystic fluid, CT-guided or ultrasound-guided aspiration of the pseudocyst have been described(2,6). In the present case, exploratory laparotomy and excision of the cystic with repositioning of VP shunt was performed. This can be achieved with laparoscopic technique as well(7,8).

## III. CONCLUSION:

A case of a huge abdominal pseudocyst as a complication of VPS is described here. A possible diagnosis of CSF pseudocyst may be considered in presence of abdominal distension following VP shunt surgery as early diagnosis and treatment would improve the clinical outcome. Post VP shunt pseudo cysts if suspected should be evaluated by imaging. CECT abdomen is an useful diagnostic tool. Surgical exploration with excision of cysts and repositioning of the shunt catheter is the treatment of choice.

## REFERENCES:

- [1]. Kashyap S, Ghanchi H, Minasian T, Dong F, Miulli D. Abdominal pseudocyst as a complication of ventriculoperitoneal shunt placement: Review of the literature and a proposed algorithm for treatment using 4 illustrative cases. *SurgNeurol Int* 2017;8:78.



- [2]. Atsumi Tamura<sup>1</sup>, Dai Shida<sup>2\*</sup> and Kyosuke Tsutsumi. Abdominal cerebrospinal fluid pseudocyst occurring 21 years after ventriculoperitoneal shunt placement: a case report. *BMC Surgery* 2013, 13:27
- [3]. Aparici-Robles F, Molina-Fabrega R: Abdominal cerebrospinal fluid pseudocyst: a complication of ventriculoperitoneal shunts in adults. *J Med Imaging Radiat Oncol* 2008, 52(1):40–43
- [4]. Bryant M, Bremer A, Tepas 3rd J, Mollitt D, Nquyen T, Talbert J. Abdominal complications of ventriculoperitoneal shunts. Case reports and review of the literature. *Am Surg* 1988;54:50-
- [5]. Pernas JC, Catala J: Case 72: Pseudocyst around ventriculoperitoneal shunt. *Radiology* 2004, 232(1):239–243
- [6]. Ersahin y, Mulluer S, S Takeli et al Abdominal cerebrospinal pseudocyst. *Child's Ner. Syst* (1996), 13.755-759.
- [7]. Popa F, Grigorean VT, Onose G, Popescu M, Strambu V, Sandu AM: Laparoscopic treatment of abdominal complications following ventriculoperitoneal shunt. *J Med Life*. 2009, 2 (4): 426-436.
- [8]. Hamid R, Baba AA, Bhat NA, Mufti G, Mir YA, Sajad W. Post ventriculoperitoneal shunt abdominal pseudocyst: Challenges posed in management. *Asian J Neurosurg* 2017;12:13-6