



Cervical Fibroid in pregnancy: an Obstetric Challenge

¹Karanpreet Kaur Bakshi, ²Kirti Patel, ³Archana Singh, Dr Parul Shukla

*SR NSCB Medical College And Hospital Jabalpur;
Assistant Professor NSCB Medical College And Hospital Jabalpur;
Associate Professor NSCB Medical College And Hospital, Jabalpur
SR NSCB Medical College And Hospital , Jabalpur*

Submitted: 10-07-2022

Accepted: 23-07-2022

ABSTRACT: This is a case report of 34 year old women presenting with large cervical fibroid in pregnancy with obstructed labour at emergency labour ward of Department of Obstetrics and Gynecology , NSCB Medical college and hospital , Jabalpur, Madhya Pradesh. Patient underwent emergency caesarean section and large cervical fibroid was left untouched and managed conservatively. Later patient was followed up in postnatal period. This case illustrated that conservative management can sometimes be the right choice over surgery.

Keywords: Cervical pregnancy, conservative management

I. INTRODUCTION:

Uterine fibroids are one of most common tumors of pelvis. Fibroid in pregnancy are becoming more common with prevalence of approximately 10.7%¹, but still cervical fibroids are a rare occurrence with a prevalence of <1%². Most of the fibroid does not increase in size during pregnancy but one third of them do increase in size causing multiple complications during antepartum, intrapartum and postpartum period. With such potential complication cervical fibroids in pregnancy still is a challenge for obstetricians managing antenatal women. We report a case of women presenting with large cervical fibroid during labour in obstruction for which emergency caesarean section was performed and fibroid was managed conservatively.

II. CASE REPORT

A 34 year old Gravida 2 , Parity 1 , living 1 with previously full term delivered female child presented with full term gestation with labour pains in emergency labour ward of NSCB Medical College and Hospital , Jabalpur Madhya Pradesh. She was referred as a case of Non progression of labour from District hospital , Jabalpur. She was a booked patient with 3 visits at District hospital, Jabalpur, with basic antenatal investigations.

On general examinations Her vitals were found to be stable, mild pallor was present. On her obstetric examination per abdominally abdomen was found to be overdistended with bladder distended and adequate contractions were present. Fetal heart was found to audible, regular and rate was 132/min. head was palpable per abdominally. On her vaginal examination, cervix was found to be 6-7 cm dilated with large mass occupying the vagina about 10*10cm and head was not palpable, suggestive of cervical fibroid. Thus a diagnosis of large cervical fibroid in pregnancy with obstructed labour was made. Blood samples were sent for investigations and cross matching, Patient was taken up for emergency caesarean section was done.

Intraoperatively during caesarean section due to bladder distention and large cervical mass upper segment transverse incision was taken and a healthy female baby of 2400gms was delivered. A large cervical fibroid of 16*16cm size was noted. Keeping in mind age of patient and size of the fibroid decision of conservative management was taken and fibroid arising from anterior lip of cervix was left undisturbed and proper hemostasis with prophylactic use of uterotonics was done to prevent PPH. There was around 3cm extension of uterine incision which was managed. Postoperatively there was no complications and patient for kept under regular follow up postnatally. She underwent ultrasonography after 6 weeks post delivery and it was found a cervical fibroid arising from anterior lip of cervix of about 15*15cms and she was then asked for follow up after 4 weeks.

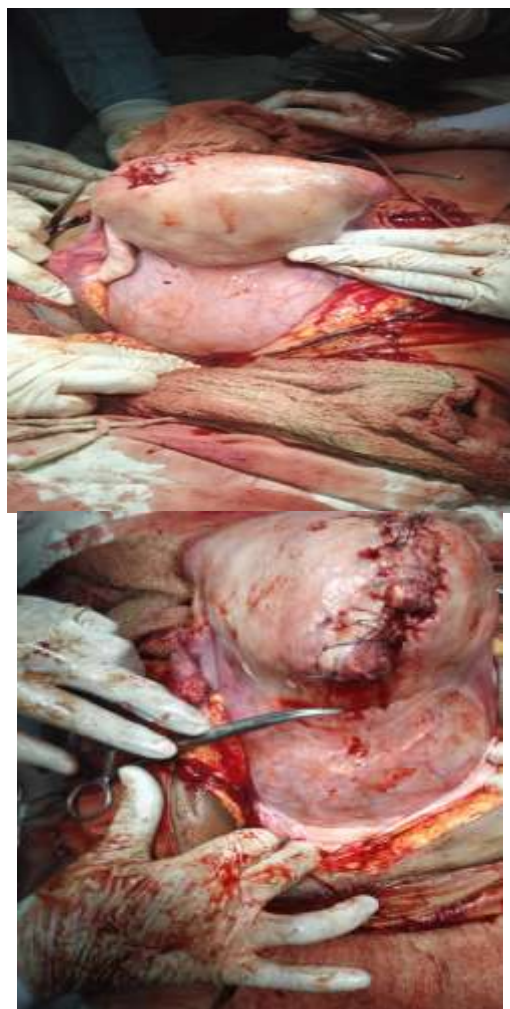


Fig 1

III. DISCUSSION :

Cervical fibroid with its rare occurrence and lack of proper literature pose a challenging situation for obstetricians to manage especially in our case where the large fibroid had occupied almost entire pelvis and presented a referred case with obstructed labour, which is one of the most dreadful complication of cervical fibroid in

pregnancy. It is of utmost importance that such high risk cases are identified and are referred to tertiary centers for early booking and management, so that various complications are anticipated and case is being closely monitored by group of experts and there is accessibility of facilities like blood transfusion and interventional radiology.

Women with cervical fibroid can present with non cephalic presentations, miscarriages in early trimester, pain during pregnancy, infection, urinary and bowel symptoms and obstructed labour. Close monitoring and assessment of size can determine the mode of delivery and in cases of solitary rapidly increasing size mass MRI is recommended. Conservative management of cervical fibroid during caesarean section can prevent torrential bleeding and hazardous complications. Patient should be followed up after delivery to monitor decrease in size of fibroid and plan further management.

This case illustrates that sometimes decision of conservative management is more rewarding as it reduces the risk of massive blood transfusions, longer hospitalizations, infections and high cost burdens which are special area of concern in developing countries like India.

REFERENCES

- [1]. Straub HL, Chohan L, Kilpatrick CC. Cervical and prolapsed sub- Mucosal leiomyomas complicating pregnancy. *Obstet Gynecol Surv.* 2010;65(9):583–590.
- [2]. Laughlin SK, Baird DD, Savitz DA, et al. Prevalence of uterine Leiomyomas in the first trimester of pregnancy: an ultrasound screening Study. *Obstet Gynecol.* 2009;113(3):630–635.
- [3]. Ng AX, Sulaiman S, Tagore S. Challenges of a large cervical fibroid in pregnancy. *Obstet Gynecol Int J.* 2016;5(3):345–346. DOI: 10.15406/ogij.2016.05.00161