



Clinical Implications of Analysis of Radial Head Morphometry (original study)

Dr. Neelofar, Dr. Sajad Hamid, Dr. Ashfaque Hassan, Dr. Sajad Hamid

Post md tutor anatomy skims medical college
Associate professor anatomy skims medical college
Associate professor anatomy skims medical college
Associate professor anatomy skims medical college

Submitted: 10-08-2022

Accepted: 22-08-2022

ABSTRACT

Background: Radius is a long bone which is present in the lateral side of forearm and ulna is present on the medial side. Upper end of Radius is important as it participates in the formation of Elbow joint. In our study we will discuss about the morphometry of the upper end of radius.

Aims and Objective: Our aim was to study various parameters of proximal end of radius and assess its clinical importance

Material and Methods: We collected 52 dry adult radius and assessed various parameters of upper end. All the measurements were recorded with the help of digital vernier caliper and noted in Microsoft excel sheet.

Results: The mean thickness of ventral curve of proximal left radius was 3.99 ± 1.05 mm and on right side the mean thickness of ventral curve was 4.28 ± 0.75 mm. The mean thickness of lateral curve of proximal right radius was 2.98 ± 0.68 mm and on left side the mean thickness of lateral curve was 2.70 ± 0.91 mm. The mean thickness of dorsal curve was 2.88 ± 0.68 mm on right side and on left side it was 2.86 ± 0.99 mm. The mean depth of superior articular facet of proximal radius was 1.92 ± 0.38 mm on right side while on left side the mean thickness was 1.84 ± 0.45 mm. All the morphometric parameters were non-significant when right compared to left radius.

Conclusion: The complete knowledge of upper end of radius including its anthropometry is very important so that we can make proper sized prostheses in case of various surgical procedures

Key words: Morphometry, proximal radius, prosthesis

I. INTRODUCTION

The fractures of the upper end of radius are not uncommon, the fractures of the radial head constitute about 20% of all elbow trauma cases [1]. Radius is the long bone which is present in the lateral side of forearm. It has three parts, upper end, shaft and lower end. Upper end has further

three parts, head, neck and radial tuberosity. In Latin the radius means the ray. Head of the radius articulates with the capitulum of the humerus to form the elbow joint which is very important for the flexion and extension of the forearm. As upper end of radius is very important for maintaining the stability of elbow joint and participates in formation of two joints; radioulnar joint and radiohumeral joint [2,3]. Radius bone ossifies from 3 centers, one primary center for body, one secondary centre for upper end and one secondary centre for lower end [4-8].

Upper end of radius is prone to pathological conditions like dislocations, fractures, subluxation etc. And these conditions are many times treated with prosthetic implants [3]. Therefore, the knowledge of various parameters of radial head is very important for prosthesis procedures. Hence, we decided to study various parameters of proximal end of radius. Morphometry means quantitative analysis of an object and it includes shape and size of the object.

II. MATERIAL AND METHODS

Our study was conducted in the Department of Anatomy, SKIMS Medical College and Hospital Srinagar. We studied 52 dry adult radius and evaluated their morphometry of upper end of radius.

Exclusion criteria: fractured bones, deformed bones and incompletely ossified bones were not included in the study. Out of 52, we had 28 left and 24 right radius of unknown gender. We took all the measurements in different positions of radius with the help of digital vernier caliper. Various parameters were recorded in Microsoft excel sheet then analysis was done in SPSS software

The parameters we measured are:

- Depth of articular facet (D):- scale was kept over the radial head touching most prominent anterior and posterior rim of radial head and then depth in the centre was measured by using the digital caliper.



- b) Thickness of ventral curve (TVC)
- c) Thickness of dorsal curve (TDC)

- d) Thickness of lateral curve(TLC)



Diagram 1: showing measurement of thickness of ventral curve (TVC) by digital vernier caliper

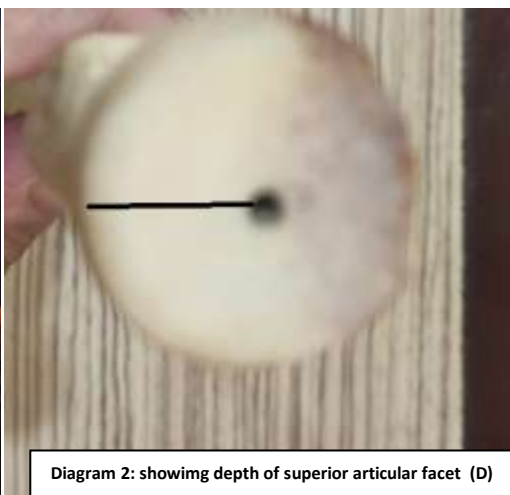


Diagram 2: showing depth of superior articular facet (D)

III. RESULTS

A total of 52 (24 right and 28 left) dry radius bones were selected. Mean values of all the parameters studied in this study are shown in Tables 1 and 2. The mean thickness of ventral curve of proximal left radius was 3.99 ± 1.05 mm and on right side the mean thickness of ventral curve was 4.28 ± 0.75 mm. The mean thickness of lateral curve of proximal right radius was 2.98 ± 0.68 mm and on

left side the mean thickness of lateral curve was 2.70 ± 0.91 mm. The mean thickness of dorsal curve was 2.88 ± 0.68 mm on right side and on left side it was 2.86 ± 0.99 mm. The mean depth of superior articular facet of proximal radius was 1.92 ± 0.38 mm on right side while on left side the mean thickness was 1.84 ± 0.45 mm. Statistically all morphometric parameters were non-significant when comparing right to left (radius table 3).

Table 1: Various parameters of right radial head.

parameter	mean	minimum	Maximum	Std deviation
D	1.92	1.11	2.68	0.38
TVC	4.28	3.45	6.90	0.75
TDC	2.83	3.1	5.7	0.68
TLC	2.98	2.91	4.99	0.66

TVC: Thickness of Ventral Curve; TLC: Thickness of Lateral Curve; TDC: Thickness of Dorsal Curve; D: Depth of Superior Articular Facet;

Table 2: Various parameters of left radial head.

left.parameter	mean	minimum	Maximum	Std deviation
D	1.84	1.39	3.52	0.45
TVC	3.99	2.80	7.23	1.05
TDC	2.86	1.99	5.56	0.99
TLC	2.70	1.55	4.98	0.91

TVC: Thickness of Ventral Curve; TLC: Thickness of Lateral Curve; TDC: Thickness of Dorsal Curve; D: Depth of Superior Articular Facet;



Table 3: Comparisons of morphometric values of right and left radial Head.

Parameters	Right side (n=24) Mean±SD	Left side (n=28) Mean± SD	P value	Significance
D	1.92±0.38	1.84±0.45	0.021	NS
TDC	2.83±0.68	2.86±0.99	0.652	NS
TLC	2.98±0.66	2.70±0.91	0.458	NS
TVC	4.28±0.75	3.99±1.05	0.056	NS

TVC: Thickness of Ventral Curve; TLC: Thickness of Lateral Curve; TDC:Thickness of Dorsal Curve; D: Depth of Superior Articular Facet, NS =nonsignificant

IV. DISCUSSION

In addition of the forearm movement, the proximal radius is very important for the stability of the elbow. To design prosthesis and for reconstructive surgery of radius, the detailed and accurate anatomical description of proximal radius is important for successful orthopaedic surgeries. Some biomechanical studies have emphasized the importance of correctly sizing the radial head prosthesis at the time of implantation [8]. In unstable elbow fractures, accurate implant size is a significant factor to prevent subluxation of the radial head. The proximal end of the radius plays a major role in the stability of the elbow and forearm movement [9]. Hence having the accurate description of its anatomy is essential in the design of prosthesis and reconstructive surgery if function must be maintained. The present study examined the radius with emphasis on its proximal end, in an attempt to define the values of the proximal end. The parameters studied were depth of articular facet (D), thickness of ventral curve (TVC), thickness of dorsal curve (TDC), and thickness of lateral curve(TLC). Similar type of Morphological and Morphometric Study of Proximal radius was conducted by Chandni et al, and their findings correlates with our results of Articular depth (D), TDC, TLC and TVC [10]. Archana Singh and Arun Singh conducted morphometric study of proximal radius and their mean values were 5.07±0.97 mm (TVC), 3.63±0.82 mm (TLC), 4.02±0.94 mm (TDC) and 1.97±0.45 mm (DH) these results correlate with our study [11]. Al-Imam A et al. and Gupta C et al. also reported similar results [12,13]. U. Ekeneokot et al. on their morphometric study of proximal radius also reported the same results of [14]. Anjana et al. documented higher values for the all radius compared to this current study [15]. Swieszkowski et al did a morphologic study of the radial head which was performed using a co-ordinate measuring machine integrated with a computer aided design system. They concluded that there

were no significant differences on the right and left sides[16]. Koslowsky et al. took optosil imprints of 18 pairs of proximal radii and measured maximum and minimum radial head diameter and concluded that radial head has complex shape and no significant differences occurred between right and left radii [17]. King et al. did dimensions of the native radial head were measured in 28 cadaveric upper extremities and radiographs of the contra lateral elbows of 40 patients who had received a radial head replacement. They measured mean difference between the maximum and minimum radial head diameters. They concluded that although the native radial head is not circular, it does not have a consistently elliptic shape [18]. Smith et al. did cadaveric study of the radial head and neck to determine the anterior and posterior limits for safe placement of internal fixation on the surface of the radial head or neck. They concluded that the “safe zone” is nearly one third of radial head circumference and can be reliably determined with the method of intraoperative marking as outlined [19]. The radial head shows difference in the morphometry parameters based on the races as seen in the study conducted by Paul Puchwein et al. and the study conducted by Tejwani and Mehta [20,21].

V. CONCLUSION:

For reconstructive orthopaedic surgeries of proximal radius, the knowledge of size and shape of radial head is necessary for creation of radial head prosthesis that should be anatomically and biomechanically correct so that the open reduction and internal fixation and osteo-synthesis may be safely applied. The present study correlates with the various studies but further studies should be done to know the morphometric variations with race and region.

REFERENCES

- [1]. vanEerten PV, Lindeboom R, Oosterkamp AE, Goslings JC. An X-ray template



- assessment for distal radial fractures. *Arch Orthop Trauma Surg.* 2008;128:217–21.
- [2]. Slutsky DJ. Predicting the outcome of distal radius fractures. *Hand Clin.* 2005;21:289–94.
- [3]. Giannicola G, Manauzzi E, Sacchetti FM, Greco A, Bullitta G, Vestri A, et al. Anatomical variations of the proximal radius and their effects on osteosynthesis. *J Hand Surg Am* 2012;37:1015–23.
- [4]. Slutsky DJ. Predicting the outcome of distal radius fractures. *Hand Clin.* 2005;21(3):289–94.
- [5]. Werner FW, Palmer AK, Fortino MD, Short WH. Force transmission through the distal ulna: Effect of ulnar variance, lunate fossa angulation, and radial and palmar tilt of the distal radius. *J Hand Surg* 1992;17:423–8.
- [6]. Chien HY, Chen AC, Huang JW, Cheng CY, Hsu KY. Short to medium term outcomes of radial head replacement arthroplasty in posttraumatic unstable elbows: 20 to 70 months follow up. *Chang Gung Med J* 2010;33:668–78.
- [7]. Ando Y, Yasuda M, Goto K. Is ulnar variance suitable for a parameter of Colles' fracture preoperatively? *Osaka City Med J.* 2006;52:63–6.
- [8]. Leung F, Ozkan M, Chow SP. Conservative treatment of intraarticular fractures of the distal radius – Factors affecting functional outcome. *Hand Surg.* 2000;5:145–53.
- [9]. Kapandji, A. Biomechanics of pronation and supination of the forearm. *Hand Clin*, 2001; 17: 111-122.],
- [10]. Chandni Gupta, SnehaGuruprasadKalthur, J. C. Malsawmzuali, Antony Sylvan D'souza A Morphological and Morphometric Study of Proximal and Distal Ends of Dry Radii with its Clinical Implications. *Biomed J* 2015;38:323-328)
- [11]. ArchanaSingh1, Arun Singh2A Morphometric Study of Head of Radius and its Clinical Implication in Radial Head Prosthesis. *International Journal of Anatomy, Radiology and Surgery.* 2019, Jan, Vol-8(1): AO20-AO23
- [12]. Al-Imam, A. (2016) 'Medio-lateral inclination of proximal and distal articular surface of the radius', *Asian Journal of Medical Sciences.* nepjol.info, 7(5), pp. 117–123.
- [13]. Gupta, C. et al. (2015) 'A morphological and morphometric study of proximal and distal ends of dry radii with its clinical implications', *Biomedical journal.* biomedj.cgu.edu.tw, 38(4), pp. 323–328.
- [14]. UtoonEkeneokotEkeneokot*, Emeka Anthony Osunwoke, Valentine ChidozieAmasiatu and OkezieChineduUgwa. Morphometric study of the proximal end of the radius: its clinical applications. *European Journal of Biomedical and Pharmaceutical Sciences.*2019, Volume 6, Issue 10, 323-332.
- [15]. Anjana M, Ashwani U, Gurdev G, Sonia K. (2017). Morphometric considerations of proximal radius- clinical implications in radial head implants. *Int J Sci Res.*, 2017; 6(10): 683–685.
- [16]. Swieszkowski W, Skalski K, Pomianowski S, Kedzior K. The anatomic features of the radial head and their implication for prosthesis design. *ClinBiomech (Bristol, Avon).* 2001 Dec; 16(10):880-7.
- [17]. Koslowsky TC, Beyer F, Germund I, Mader K, Jergas M, Koebke J. Morphometric parameters of the radial neck: an anatomical study. *SurgRadiol Anat.* 2007 Jun; 29(4):279-84.
- [18]. King GJ, Zarzour ZD, Patterson SD, Johnson JA..An anthropometric study of the radial head: implications in the design of a prosthesis. *J Arthroplasty.* 2001 Jan; 16(1):112-6.
- [19]. Smith GR, Hotchkiss RN. Radial head and neck fractures: anatomic guidelines for proper placement of internal fixation. *J Shoulder Elbow Surg*, 1996 Mar-Apr; 5(2 Pt 1):113-7.
- [20]. Puchwein P, Heidari N, Dorr K, Struger L, Pichler W (2013) Computer aided analysis of radial head morphometry. *Orthopedics*, 2013; 36(1): e51-57
- [21]. Tejwani NC, Mehta H (2007) Fractures of the radial head and neck: current concepts in management. *J Am AcadOrthopSurg*, 2007; 15: 380-387