



Covid 19 and neurological manifestation: A review

Dr. Shilpa. Karkera, 2. Ms Danielle Vera, Ms Kathleen Carter

Assistant Professor Department of Anatomy Trinity school of medicine St Vincent and Grenadines

Term 4 student Trinity school of medicine St Vincent and Grenadines

Term 4 student Trinity school of medicine St Vincent and Grenadines

Submitted: 10-08-2022

Accepted: 22-08-2022

ABSTRACT

Introduction:

Coronavirus disease 2019 (COVID-19), the highly contagious infectious disease caused by severe acute respiratory syndrome coronavirus 2 (SARS-CoV-2), has had a catastrophic effect on the world's demographics resulting in more than 2.9 million deaths worldwide, emerging as the most consequential global health crisis since the era of the influenza pandemic of 1918.

Aim:

Identify the etiology and epidemiology of COVID-19.

Describe the clinical features and neurological findings expected in patients with COVID-19.

Discuss interprofessional team strategies for improving care coordination and communication to care for patients with coronavirus and improve outcomes.

Results:

In the present review we found that the respiratory symptoms and fever, cough and shortness of breath are common feature in most of the patients. In more severe cases, infection can cause pneumonia, severe acute respiratory syndrome and sometimes death. Neurological complications may be significance of comprehensive cardiorespiratory failure and metabolic abnormalities elicited by the infection, through invasion of the virus, or an autoimmune response to the virus.

named severe acute respiratory syndrome coronavirus 2 (SARS-2) has spread in more than 215 countries. COVID 19 is a global pandemic that led to a dramatic loss of human life worldwide. Total number of Cases Worldwide -308,186,767 and total number of deaths Worldwide-5,507,612. Total number of recovered individuals -259,714,030.(organization WHO 2022)

The coronavirus: SARS- CoV-2

Coronaviruses, the family of viruses belongs to COVID -19 were first identified in humans in 1965 from child with an upper respiratory tract infection which was responsible for 1-35% of upper respiratory tract infections of that season. (McIntosh 1985)

The severe acute respiratory syndrome (SARS) in 2002-2003 which affected more than 8000 persons worldwide with a 10% mortality (CDC 2020) and middle east syndrome (MERS) epidemic that started in 2012 affected nearly 2500 persons with 35% mortality (Organization WH 2020).

Coronaviruses are minute in size and contain a single-stranded RNA as a nucleic material.

The viral genome is protected within the nucleocapsid and the genome encodes for the 3' structural proteins, including spike (S), envelope (E), membrane (M), nucleocapsid (N), which are common to all coronaviruses. (Figure 1 ,2 and 3)

I. INTRODUCTION:

In December 2019, a novel coronavirus commenced in Wuhan, China, as the causing factor of pneumonia and severe acute respiratory syndrome. As of August 1st, 2021, the currently



Figure 1: Classification of coronavirus

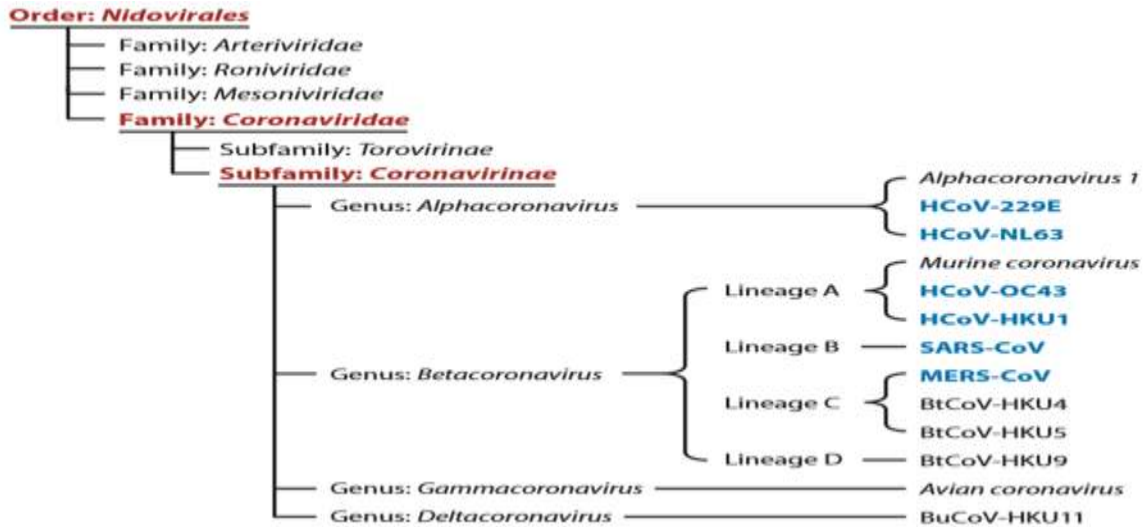
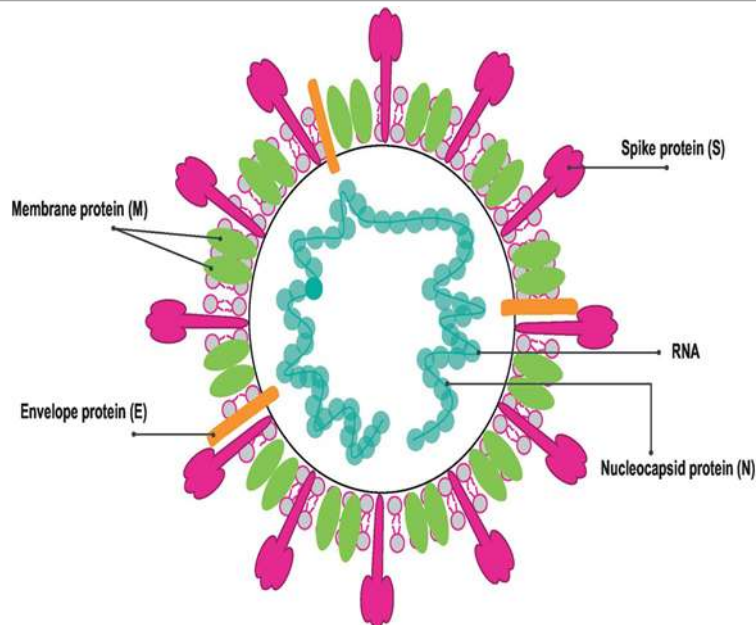


Figure 2: Animal Reservoirs Between the Three Viruses

Animal Reservoirs	Sars-CoV	Mers-CoV	Sars-CoV 2
Primary Host	Raccoon Dogs	Camels	Bats(BatCoV RaTG13)
Secondary Host	Civet Palm	Pipistrellus and Perimyotis Bats(Key host)	-

Figure 3: Structure of coronavirus





Mode of transmission

Hugging or kissing and touching someone with direct contact is the main chances in transmission of virus.

Being in close proximity with someone or a group of people, specifically within 6 feet proximity and for 10 mins or more (Concerts, meetings, parks) and the using of utensils with others.

Indirect contact (such as tables, railings of stairs, door handles)

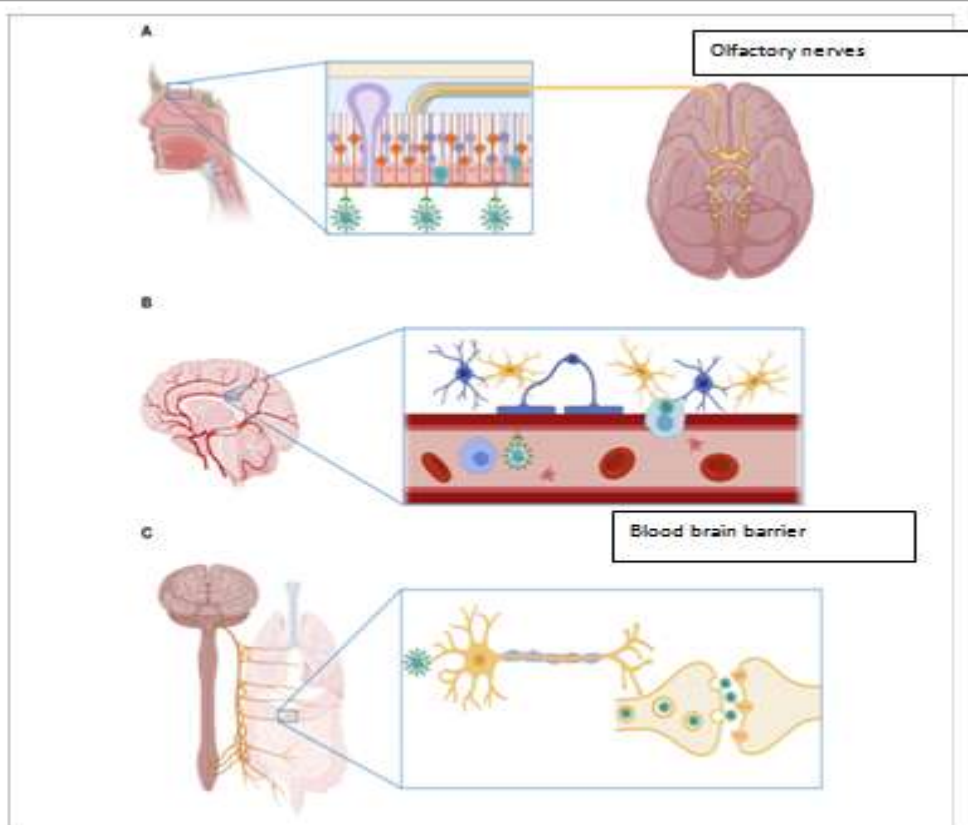
Pathophysiology:

Invasion of the cells in host body by SARS- Cov-2, causing inflammatory reaction and

indications. (Figure 4). The key of the entry of the virus is through the angiotensin converting enzyme 2 (ACE2) receptors expressed in the both the neurons and glial cells of the brain. These receptors are mainly present in the brainstem regions which is in charge for regulation of Cardiovascular function including subfornical organ, paraventricular nucleus, nucleus of tractussolatrius and rostral ventrolateral medulla. Though severe acute respiratory syndrome(SARS) and Middle east respiratory syndrome (MERS), the virus might also take a direct route through the olfactory bulb upon inhalation without using the ACE 2 receptors.

Figure 4: Entry of SARS 2 to Nervous system

A: Olfactory nerves B: Haematogenous route C: Axonal transmission in peripheral nervous system



Once invaded, the viruses will be reactive which causes astrogliosis and activation of microglia setting off a gigantic neuroinflammatory cascade. Instantaneously, the systemic inflammation associated with SARS- CoV-2 infection negotiates with the blood brain barrier (BBB) which relentlessly disturbs brain hemostasis and leads into death of neuronal cells. Moreover, damages of the brainstem centers for respiration

will cause the impairment of the ventilator lung function resulting in profound hypoxia.

Combination of hypoxia with existing neuroinflammation origins to hippocampal and cortical areas damage, resulting in neuropsychiatric effects of the virus.

General clinical manifestation (Table 1)



It includes respiratory symptoms and fever, cough and shortness of breath. In more severe cases,

infection can cause pneumonia, severe acute respiratory syndrome and sometimes death.

Table 1: Clinical manifestation in Covid 19

Most common symptoms	Less common symptoms	Serious symptoms
Fever	aches and pains	difficulty breathing or shortness of breath
Dry cough	sore throat	chest pain or pressure loss of speech or movement
Tiredness	diarrhea conjunctivitis headache loss of taste or smell a rash on skin, or discoloration of fingers or toes	

Neurological Complications of Covid19(Table 2)

Several neurological complications of COVID 19 appear to be both uncommon and various in nature.

Neurological complications may be significance of comprehensive cardiorespiratory failure and metabolic abnormalities elicited by the infection, through invasion of the virus, or an autoimmune response to the virus.

Most of our knowledge about CNS effects comes from the few retrospective observational case series which are as follows:

A multicenter, retrospective study by Mao et al. (4) was the first study to estimate the neurological manifestations in COVID-19 and neurological manifestations were present in 36.4% of total found that 214 patients, out of which most common was CNS manifestations (24.8%) shadowed by peripheral nervous system manifestations (8.9%).

An observational case series study reported by Helms et al. on 58 patients who was admitted to ICU for ARDS, secondary to COVID-19 in France. Between 3 march 2020 and 3 April

2020. Out of 58 patients, 14% showed neurological findings at admission and 69% of cases were weaned off sedation and paralytics. Most often observed symptoms were confusion (65%), anxiety (69%), upper motor neuron syndrome signs like hyperreflexia with clonus (involuntary and rhythmic muscle contractions) and positive Babinski's sign (69%) during ICU admission and after discharge (33%) few patients even had dysexecutive syndrome.

Brain MRI of these patients revealed leptomenigeal enhancement (62%), perfusion abnormalities on MRI (100%), and ischemic CVA (23%). Only one out of the eight patients who endured electroencephalogram (EEG) showed findings consistent with encephalopathy (3).

Many other retrospective observational studies described the incidence of neurological manifestations as 4.3% (6), 15% (7), and 57.4% (8). The most common neurological manifestations reported in COVID-19 were smell disturbances, taste disturbances, headache, myalgia, stroke, meningitis and disturbances in consciousness/ altered mental status.

Table 2: Neurological Complications of Covid 19

Localization in the Nervous system

Central nervous system	Headache, Dizziness, Stroke symptoms, Meningitis, Seizures, confusion, Agitation, Delirium, stupor, coma
Peripheral nervous system	Hypogeusia, Hyposmia, Generalized weakness
Muscles	Myalgias, weakness



Effects of SARS CoV19 on Nervous system(CNS) and autoimmune disorders:

Headache:

In 40% of patients, the headache of COVID-19 is a common symptom and only lasts a few days, while in others, it can last up to months. Symptomatically, the headache has been regarded as mild. It is presenting mostly as a whole-head, severe-pressure pain. It's different than migraine, which by definition is unilateral throbbing with sensitivity to light or sound, or nausea. This is more of a whole-head pressure presentation. (9)

Meningitis/ encephalitis

The first case of meningitis associated with COVID-19 was reported in Japan in February 2020 (10). Meanwhile, two or three more cases of meningoencephalitis have also been described in the United States (11–12). Even though very rare, these neurological manifestations occasionally are the exclusive initial presenting complaint of COVID-19.

Predictably, meningitis has been described. For example, physicians of Pakistan reported 21-year-old male medical student with multiple underlying comorbidities including history of frontal headache and fever, and 1-day history of neck stiffness. He denied any cough, shortness of breath, body aches, and diarrhea. Based on clinical presentations and initial blood work up, bacterial meningitis was suspected and he was started on intravenous antibiotics empirically after cerebral spinal fluid (CSF) was sent for analysis. CSF analysis showed a picture of viral meningitis and in addition to empiric antibiotics, he was also given antiviral agents. CSF gram staining, Ziehl-Neelsen staining, and culture showed no microorganisms, and tests for Herpes simplex type 1, Herpes simplex type 2, and Varicella zoster virus were negative. On that same day, he developed tachycardia, tachypnea, and hypotension; his oxygen saturation started to drop gradually and was put on a ventilator. His chest X-ray showed diffuse multi-lobar infiltrates consistent with acute respiratory distress syndrome. His laboratory reports showed respiratory acidosis and a picture of disseminated intravascular coagulation (DIC). One day later, he passed away due to multi-organ failure (13).

Stroke

A stroke occurs when the blood supply to part of your brain is interrupted or reduced, preventing brain tissue from getting oxygen and nutrients. Brain cells begin to die in minutes'. Various etiology factors may be responsible for an

increased risk of stroke. A study on total of 103 (1.3%) patients developed acute ischemic stroke among 8163 patients with COVID-19. Among all patients with COVID-19, the ratio of patients with hypertension, diabetes, hyperlipidemia, atrial fibrillation, and congestive heart failure was significantly higher among those with acute ischemic stroke. Acute ischemic stroke was associated with discharge to destination other than home or death (relative risk, 2.1 [95% CI, 1.6–2.4]; $P < 0.0001$) after adjusting for potential confounders.

A total of 199 (1.0%) patients developed acute ischemic stroke among 19 513 patients without COVID-19.

Among all ischemic stroke patients, COVID-19 was associated with discharge to destination other than home or death (relative risk, 1.2 [95% CI, 1.0–1.3]; $P = 0.03$) after adjusting for potential confounders. (14)

Risk may be increased for both arterial and venous cerebrovascular disease. In one recent study on 78 COVID-19 patients, stroke occurred in 6 (2.8%) (5 ischemic and 1 hemorrhagic) (4). In a small series of 24 patients from the Seattle region, stroke was observed in 2 (8%) of 24 hospitalized COVID-19 patients (15). Viral myocarditis may increase the risk of stroke (16).

AIDP/ Guillain –Barre syndrome:

Guillain-Barré syndrome is an acute acquired autoimmune disorder of the peripheral nerves that often occurs after infection (17).

During the recent pandemic in Northern Italy, one case of a 57-year-old man developing acute motor-sensory axonal neuropathy, a variant of Guillain-Barré syndrome (GBS), 12 days after severe acute respiratory syndrome-coronavirus-2 (SARS-CoV-2) infection. Similarly, to other bacterial and viral infections, dysregulation of the immune system due to post-infectious mechanisms, such as the molecular mimicry, could lead to an indirect damage of the peripheral nervous system related to SARS-CoV-2.

GBS causes motor dysfunctions that are not easily detectable in non-neurological settings or in patients needing ventilatory assistance. Several reports also suggested that GBS and Miller Fisher syndrome (MFS) could be neurological complications of COVID-19 (18).

GBS connected to SARS-CoV-2 infection may follow the classic post-infectious pattern, with report indicating that it is also possible in children. GBS has also been reported as part of the “long COVID-19 syndrome” (19).



Acute disseminating encephalomyelitis(ADEM):

ADEM is a demyelinating inflammatory condition existing at the severe end of the spectrum of neurological manifestations in COVID-19. Clinical presentation is of a non-specific sudden onset encephalopathy, which may present as behavioral change or alteration in consciousness with or without fever (20).

ADEM has been described with the COVID 19 infection in a 53-year-old man at London hospital complicated by a tension pneumothorax, bilateral DVTs and the development of PICC line sepsis on day 36 (blood cultures grew *Serratiamarcescens*)(21).

Effects of SARS CoV19 on Peripheral nervous system (PNS):

Hypogeusia, Hyposmia

Anosmia, also known as smell blindness which is caused commonly due to upper respiratory infection and has attributed to damage to olfactory epithelium by causative virus (22). During Covid 19 outbreak it was one of the most common symptom.

In a cross-sectional study conducted on 390 positive Covid 19 patients, one-third of patients reported hyposmia and/or hypogeusia, which occurred significantly more frequently in non-severe outpatients (23). Anosmia and ageusia

related to Covid 19 normally recovers over several weeks.

Anosmia did not appear to be a commonly reported manifestation during SARS epidemic (24).

A high expression of ACE-2 receptors on oral mucosa has been reported and may be related to these symptoms with COVID 19 (25).

Myalgia/ myositis/ Skeletal muscle injury

The myalgia has been already reported in several cohorts of patients with covid-19 infection (26).

Whereas a case study of a MRI- documented myositis secondary to covid-19 patient was reported in France.

In conclusion, although covid 19 is frequently limited to upper and lower airways, as shown in this case, reveal itself by acute myositis. Since the association of muscle inflammation with interstitial pneumonia can be seen in either covid-19 or autoimmune myositis, this differential diagnosis should be noted by clinicians (27).

In the Guan et al study, two patients had rhabdomyolysis (0.2%) and the CK levels were elevated in 13.7% patients (28). One study even showed statistical association between elevated CK levels and mortality (29).

Explanation of each manifestation (Table 3)

Table 3: Summary of Major neurological abnormalities in COVID 19

Author	Study Design	RT-PCR in CSF	Findings
Mao et al (4)	Case series	NA	214 Covid 19 positive patients were included. 24.8% [53] had neurological manifestations; 2.8% [6] patients developed stroke (acute cerebrovascular disease); 8.9% [19] had peripheral nervous system symptoms were observed; 0.5% [1] deceased.
Guan et al (28)	Retrospective study	NA	1099 Covid 19 positive patients were included. In which 13.6% [150] had headache; 14.9% [164] had myalgia; 0.2% [2] had Rhabdomyolysis.
Li et al (30)	Retrospective study	NA	221 Covid 19 positive patients were included. 5% [11] had acute ischemic stroke, 0.5% [1] had



			cerebral venous thrombosis and 0.5% [1] had intracerebral hemorrhage.
Moriguchi et al (10)	Case study	+	A 24-year-old man was hospitalized for Covid 19 positive, At day 15, his treatment was continued for bacterial pneumonia and impaired consciousness due to encephalitis associated with SARS-CoV-2 in intensive care unit.
Filatov et al (31)	Case report	NA	A 74-year-old male with past medical history of atrial fibrillation, cardioembolic stroke, parkinson disease, chronic obstructive pulmonary disease (COPD) was critically ill and was hospitalized due to positive Covid 19. Upon examination, the patient was found encephalopathic.
Xiang et al(32)	Case report	+	A case of encephalitis were found along with other symptoms of Covid 19.
Poyiadji et al (12)	Case report	NA	A 58-year-old female airline worker presented with a 3-day history of cough, fever, and altered mental status. Was positive for SARS CoV 2. Brain MRI demonstrated hemorrhagic rim-enhancing lesions within the bilateral thalami, medial temporal lobes, and subinsular regions. Which was the first reported case of COVID-19-associated acute necrotizing hemorrhagic encephalopathy

II. DISCUSSION

Our narrative view summarized the so far documented neurological complications of Covid 19 that involved CNS and PNS. The neurological symptoms include dizziness, headache, myalgia's, hypogeusia and hyposomnia, there are even more serious disorders including Meningitis, encephalitis, Guillain –Barre syndrome and stroke.

More data are needed to establish the incidence, outcomes and management. Additionally, the covid 19 pandemic has a huge impact on the management and treatment of neurological patients.

Our review suggests that neurological involvement in covid 19 can cause a negative effect in the whole quality of life. Our review of the pathophysiology hypothesized by various authors seems to specify



that CNS manifestations principally arises due to inflammatory causes, PNS due to immune-mediated mechanisms, and skeletal muscle injury due to direct effects of the virus.

On the other hand, study at the bio-molecular levels are needed to accept or disprove such theories with conviction. This would help in categorizing the whole spectrum of neuropathology successful, which in turn would help in developing consent regarding the better treatment modalities.

Conflict of Interest: The authors declare that the research was conducted in the absence of any commercial or financial relationships that could be construed as a potential conflict of interest

REFERENCES

- [1]. WHO 2021 Weekly Epidemiological and Operational updates August 2021
- [2]. <https://www.who.int/emergencies/diseases/novel-coronavirus-2019/situation-reports>
- [3]. McInthosh K, 1985; Coronaviruses. In: Fields BN et al (eds) Fields's virology, Reven press, New York, pp 1323-1330
- [4]. Helms J, Kremer S, Merdji H, et al.: Neurologic features in severe SARS-CoV-2 infection. *N Engl J Med.* 2020, 10.1056/NEJMc2008597
- [5]. Mao L, Jin H, Wang M, Hu Y, Chen S, He Q, Chang J, Hong C, Zhou Y, Wang D, Miao X, Li Y, Hu B (2020) Neurologic manifestations of hospitalized patients with coronavirus disease 2019 in Wuhan, China. *JAMA Neurol* 77(6):683–690. <https://doi.org/10.1001/jamaneurol.2020.1127>
- [6]. Xiong W, Mu J, Guo J, et al. New onset neurologic events in people with COVID-19 infection in three regions in China [published online ahead of print, 2020 Jun 17]. *Neurology.* 2020; <https://doi.org/10.1212/WNL.00000000000010034>
- [7]. Mahammedi A, Saba L, Vagal A, et al. (2020) Imaging in neurological disease of hospitalized COVID-19 patients: An Italian multicenter retrospective observational study [published online ahead of print, 2020 May 21]. *Radiology.* 201933. <https://doi.org/10.1148/radiol.2020201933>
- [8]. Radmanesh A, Raz E, Zan E, Derman A, Kaminetzky M (2020) Brain imaging use and findings in COVID-19: a single academic center experience in the epicenter of disease in the United States. *AJNR Am J Neuroradiol* 41(7):1179–1183. <https://doi.org/10.3174/ajnr.A6610>
- [9]. Romero-Sánchez CM, Díaz-Maroto I, Fernández-Díaz E, et al. (2020) Neurologic manifestations in hospitalized patients with COVID-19: The ALBACOVID registry [published online ahead of print, 2020 Jun 1]. *Neurology.* <https://doi.org/10.1212/WNL.00000000000009937>
- [10]. Ding Q et al (2022) The clinical characteristics of pneumonia patients co-infected with 2019 novel coronavirus and influenza virus in Wuhan, Chin *J Med Virol*
- [11]. Moriguchi T, Harii N, Goto J, Harada D, Sugawara H, Takamino J, et al. A first case of meningitis/encephalitis associated with SARS-Coronavirus-2. *Int J Infect Dis.* (2020) 94:55–8. doi: 10.1016/j.ijid.2020.03.062
- [12]. Duong L, Xu P, Liu A. Meningoencephalitis without respiratory failure in a young female patient with COVID-19 infection in Downtown Los Angeles, early April 2020. *Brain Behav Immun.* (2020) 87:83. doi: 10.1016/j.bbi.2020.04.024
- [13]. Poyiadji N, Shahin G, Noujaim D, Stone M, Patel S, Griffith B. COVID-19-associated acute hemorrhagic necrotizing encephalopathy: CT and MRI features. *Radiology.* (2020) 296:201187. doi: 10.1148/radiol.2020201187
- [14]. Naz S, Hanif M, Haider MA, Ali MJ, Ahmed MU and Saleem S (2020) Meningitis as an Initial Presentation of COVID-19: A Case Report. *Front. Public Health* 8:474. doi: 10.3389/fpubh.2020.00474
- [15]. Adnan I. Qureshi, William I. Baskett, Wei Huang, Daniel Shyu, Danny Myers, Murugesan Raju, Iryna Lobanova, M. Fareed K. Suri, S. Hasan Naqvi, Brandi R. French; (2021) Acute Ischemic Stroke and COVID-19; 52:905–912
- [16]. Bhatraju Pavan K., Ghassemieh Bijan J., Nichols Michelle, Kim Richard, Jerome Keith R., Nalla Arun K., Greninger Alexander L., Pipavath Sudhakar, Wurfel Mark M., Evans Laura, Kritek Patricia A., West T. Eoin, Luks Andrew, Gerbino Anthony, Dale Chris R., Goldman Jason D., O'Mahony Shane, Mikacenic Carmen. Covid-19 in Critically Ill Patients in the Seattle Region — Case Series. *New England Journal of Medicine.* 2020;382(21):2012–2022. doi: 10.1056/NEJMoa2004500.



- [17]. Madjid M et al (2020) Potential effects of coronaviruses on the cardiovascular system: a review. *JAMA Cardiol*
- [18]. Yamana M, Kuwahara M, Fukumoto Y, Yoshikawa K, Takada K, Kusunoki S. Guillain-Barré Syndrome and Related Diseases After Influenza Virus Infection. *Neurol: NeuroimmunolNeuroinflamm* (2019) 6:1–7. doi: 10.1212/NXI.0000000000000575
- [19]. Antonio Zito¹, Enrico Alfonsi, Diego Franciotta, Massimiliano Todisco, Matteo Gastaldi; COVID-19 and Guillain-Barré Syndrome: A Case Report and Review of Literature *Front. Neurol.*, 21 August 2020 | <https://doi.org/10.3389/fneur.2020.00909>
- [20]. Raahimi MM, Kane A, Moore CE, Alareed AW. Late Onset of Guillain-Barré Syndrome Following SARS-CoV-2 Infection: Part of ‘Long COVID-19 Syndrome’? *BMJ Case Rep CP* (2021) 14(1): e240178. doi: 10.1136/bcr-2020-240178
- [21]. Scolding N. Acute disseminated encephalomyelitis and other inflammatory demyelinating variants. In: *Handbook of Clinical Neurology*, 2014
- [22]. Langley L, Zeicu C, Whitton L, et al Acute disseminated encephalomyelitis (ADEM) associated with COVID-19 *BMJ Case Reports CP* 2020;13: e239597.
- [23]. Seiden AM. Postviral olfactory loss. *OtolaryngolClin.* 2004; 37:1159–1166.
- [24]. Nouchi, Agathe et al. “Prevalence of hyposmia and hypogeusia in 390 COVID-19 hospitalized patients and outpatients: a cross-sectional study.” *European journal of clinical microbiology & infectious diseases: official publication of the European Society of Clinical Microbiology* vol. 40,4 (2021): 691-697. doi:10.1007/s10096-020-04056-7.
- [25]. Hwang CS (2006) Olfactory neuropathy in severe acute respiratory syndrome: report of A case. *ActaNeurol Taiwan.* 15(1):26–28. <https://www.ncbi.nlm.nih.gov/pubmed/32171076> - PubMed
- [26]. Xu XW, et al. Clinical findings in a group of patients infected with the 2019 novel coronavirus (SARS-Cov-2) outside of Wuhan, China: retrospective case series. *BMJ.* 2020;368:m606. doi: 10.1136/bmj.m606.
- [27]. Wang D, Hu B, Hu C, et al. Clinical characteristics of 138 hospitalized patients with 2019 novel coronavirus- infected pneumonia in Wuhan, China. *JAMA* 2020. doi:10.1001/jama.2020.1585
- [28]. Beydon M, Chevalier K, Al Tabaa O, et al. *Ann Rheum Dis* 2021;80: e42.
- [29]. Guan W- jie, Ni Z- yi, Hu Y, et al. Clinical characteristics of coronavirus disease 2019 in China. *N Engl J Med OverseasEd* 2020
- [30]. Zhou F, Yu T, DuR, et al. Clinical course and risk factors for mortality of adult inpatients with COVID-19 in Wuhan, China: a retrospective cohort study. *Lancet* 2020; 395:1054–62.