



Laparoscopically Assisted Simple Suturing Obliteration (Lasso) Of The internal Ring using An Epidural Needle: Report On The Technique And Early Results.

Dr. BINAYAK SADHYA

Post graduate trainee

Department of general surgery

Silchar medical college and hospital

Submitted: 15-07-2022

Accepted: 27-07-2022

ABSTRACT:

Background: Many different laparoscopic techniques for paediatric inguinal hernia (PIH) have been developed, with a trend towards increasing use of extracorporeal knotting and decreasing use of working ports. Single-port laparoscopic percutaneous extraperitoneal closure is one of the most simple and reliable methods. The concept of single-port laparoscopic percutaneous extraperitoneal closure for the treatment of inguinal hernias repair in children has been practising recent years. The applicable instruments and skills are still evolving. This study aimed to investigate this comparatively new technique for laparoscopic percutaneous ligation for paediatric inguinal hernias. Its safety, effectiveness and along with post-operative outcomes were studied.

Materials and methods: Twenty patients with PIH were treated with single-port LASSO from September 2021 to February 2022. Under laparoscopic visualization, an 18-gauge epidural needle was inserted at the corresponding point of the internal ring. The hernia defect was obliterated extraperitoneally by a nonabsorbable suture that was introduced into the abdomen on one side and withdrawn on the opposite side in an identical subcutaneous path around the internal ring using the LASSO technique.

Results: A total of 20 PIHs were successfully performed by LASSO, all 20 patients had unilateral inguinal hernia repair, mean operating time for the hernia repairs was 32 ± 5 min. There were no perioperative complications. Post-operative complications were nil. Patient could be discharged on post operative day 1. No recurrence has been observed.

Conclusions: LASSO using an epidural needle as a handy technique has proved to be a safe and effective procedure. It is easy to perform with high parent satisfaction, invisible scarring, and good cosmetic results, and therefore is a worthy choice for PIH.

I. INTRODUCTION

Indirect inguinal hernia is one of the most common diseases in paediatric surgery. Currently, single-port endoscopic-assisted percutaneous closure is the ultimate attainment in minimal access surgery for paediatric inguinal hernia. In the past decade, single-port laparoscopic closure of the internal ring for paediatric inguinal hernia using variable devices was designed to minimize invasiveness, with a minimal risk of injury to the cord structure, a low recurrence, and better cosmetic results. However, single-port laparoscopic surgery for paediatric inguinal hernia is a technique that is continually evolving. In previously reported techniques, single ligation was popular for closing the neck of the hernial sac. When the knot is loosened, closure of the hernial sac fails, leading to recurrence of hernia and postoperative hydrocele. A double ligation appears to be more reliable. Furthermore, performing tight transcuteaneous ligation of the sac is difficult, especially for obese patients with a thick abdominal wall, which would result in failure of the closure.

The concept of single-port laparoscopic percutaneous extraperitoneal closure for the treatment of inguinal hernias repair in children has been practised recent years. The applicable instruments and skills are still evolving and being probed, such as modified Kirschner pin, epidural needle, optical forceps assisting, twohooked cannula device and two-hooked core needle apparatus. In this study, we used an epidural needle to practise this minimal invasive method for inguinal hernias repair. Its safety, effectiveness and along with post-operative outcomes were studied.

II. MATERIALS AND METHODS

A total of 20 consecutive children with inguinal hernias from age group 6 years to 12 years underwent hernial repair using this technique.

The diagnosis of inguinal hernia was based on clinical presentation, physical and



radiological examination. All patients and the attendants were counselled regarding the procedure of the surgery. All patient records were reviewed to identify demographics and preoperative comorbidities. Data that were collected included demographics, unilateral versus bilateral hernia, operative time, recurrence rate, and complications.

The primary outcomes were reported including the operative time and perioperative outcome, post operative events, surgical complications, conversion to open surgery, re-admissions etc. The present study will be a case series aimed to evaluate this technique for feasibility, safety and early outcomes.

The principle of our repair is closure of the internal inguinal ring using a laparoscopically guided suture that is placed through the abdominal wall and tied extracorporeally. The procedure is begun by positioning the patient supine and in Trendelenburg on the operating table with a rolled towel for lumbar. This aids in visualization of the inguinal structures. The skin around the umbilicus is anesthetized and a 5-mm incision opens the skin for the placement of a Verres needle to attain pneumoperitoneum. Standard technique is then used to place the trocar. This is the only trocar placed throughout the operation. A 5-mm 30° scope is then used to visualize the internal inguinal ring and confirm hernia demonstrated in Fig. 1. The contralateral internal ring is also inspected. If a patent processus vaginalis is observed, we chose to repair these defects as potential hernias even in the absence of clinical symptoms. Once the borders of the hernia are identified a 1-mm needle stab incision is made, and a 22G-Touhy spinal needle is inserted with a 3-0 prolene suture threaded through its barrel. Another prolene 3-0 suture is introduced

with the needle and looped back along the side of the needle. The Touhy needle is the key instrument in our repair. The length, calibre, flexibility, and small curve at the tip help guide the appropriate positioning of the suture. This needle is then passed underneath inguinal ligament just superficial to the peritoneum and then exits into the peritoneal cavity lateral to the internal inguinal ring. The prolene suture is then advanced through the barrel of the needle carefully creating an intraperitoneal loop. The needle is removed and then repositioned through the same puncture site this time to pass anteromedial to the inguinal ring in a superficial plane to the peritoneum. In this plane, the needle traverses superficial to the vas and vessels and exits into the peritoneal cavity very close to the site that the suture is already passing through. Now, one end of the suture that is exiting at skin level is passed through the barrel of the Touhy needle and directed through the loop intraperitoneally. The free end of the suture on the outside of the patient is then pulled to lasso the end of the suture placed into it and both are pulled extracorporeally. This action creates the purse-string suture around the internal inguinal ring. The suture is tied extracorporeally, and the knot is buried beneath the skin. Occasionally, a second pursestring is required to close a very large defect, and this decision is made at the time of surgery at the clinical discretion of the attending surgeon. The purse-string suture closes the defect by causing ligation with subsequent necrosis and scarring of the hernia sac. No cautery is used during the closure of the hernia sac as to avoid thermal injury to the spermatic cord.

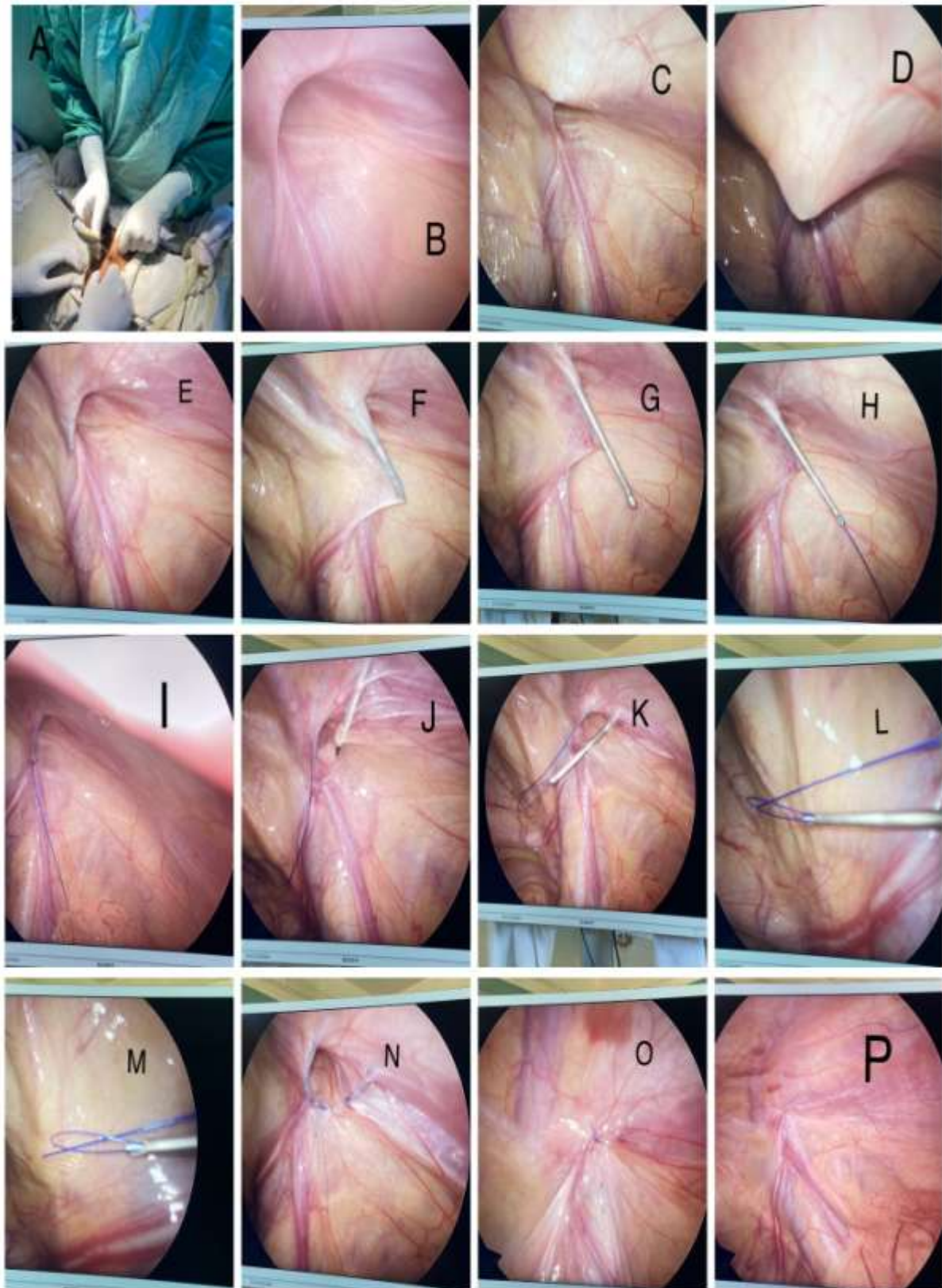


FIG 1. A-Attaining pneumoperitoneum with veress needle, B-Intraoperative photograph showing right sided inguinal hernia, (C-E)- A puncture needle (epidural needle) with the lasso in



the sheath was advanced extraperitoneally in the medial side of the ring and crossed over the vas deferens/testicular vessels, (F-G)- The needle was passed into the peritoneal cavity lateral to the testicular vessels. (H-J)- The prolene suture was introduced and kept inside, the epidural needle is taken out and the prolene suture is inserted again in such a way making a LASSO loop. (K-M)-The suture is manipulated in such a way that the opposite end of the suture is passed through the loop to complete the purse-string. N-The loop end of the ligature is pulled out by the LASSO obliterating the internal ring in a purse-string manner,(O-P)- The hernial sac was closed after ligation.

III. RESULTS

The demographic and clinical characteristics of the patients are shown in Table 1. Preoperative diagnosis of unilateral inguinal hernia was made in 20 patients. The mean operating time was 25 min (range 20-30 min). Postoperative pain was slight and no narcotic analgesia was necessary. All of the children resumed a regular diet 6 h after surgery and were discharged on the second day. No recurrence of hernia or occurrence of postoperative hydrocele was observed. No chronic wound pain or abdominal pain was found during this period. In operated boys, all of the testes were correctly positioned in the scrotum. Additionally, no testicular swelling or hematoma was observed, and no testicular atrophy was found. Parents considered that the postoperative cosmetic results were excellent with no scarring in the inguinal region and almost invisible scarring in the umbilicus.

Study Period	6 months
Age	6 years-12years
Boys:Girls	9:1
No. of obese patients needing knot pusher	Nil
No. of unilateral hernia at presentation	20
No. of bilateral hernia at presentation	Nil
Mean operating time	35 min
Follow up	3 months
Recurrence	Nil
Post operative hydrocele	Nil
Testicular swelling/Hematoma	Nil
Post operative testicular atrophy	Nil
Conversion to open surgery	Nil
Other	Nil

Table:1 Data for patients who underwent LASSO technique

IV. DISCUSSION

Inguinal hernia repair is one of the most common procedures performed by paediatric surgeons today. Recently, laparoscopic repair of inguinal hernias has become more popular than open repair in many adult centres. In addition, laparoscopy has become the primary technique employed in many paediatric hospitals for common surgical procedures, which were traditionally performed in an open fashion. Despite widespread experience with minimally invasive techniques for recently trained paediatric surgeons, laparoscopic inguinal hernia repair in children remains a debated topic. A review from a single paediatric surgeon involving 6,361 patients over a 35-years period documented a laparoscopic inspection of the contralateral internal ring has been proven an effective technique to avoid unnecessary open exploration in patients with elevated risk of

contralateral patent processes unidentified on clinical exam. Potential advantages of the purely laparoscopic approach include improved cosmetic outcome, decreased post-operative pain, improved or equivalent operative times, and ease of evaluation of the contralateral groin with repair of a hernia if found. In addition, the ability to inspect the intestine for ischemia in incarcerated hernias and operate via new tissue planes for repair of recurrences from open surgery are possible with laparoscopy. Laparoscopic repairs can be broadly classified based on whether intracorporeal or extracorporeal suturing, and knot tying is required and on the number of trocars placed.

The characteristics of the typical previously reported methods [3–9] are shown in Table 2.

The largest criticism of laparoscopic hernia repair in children remains the potential for higher recurrence rate when compared with open



surgery as documented in several early studies. In one of the largest studies involving 712 hernia repairs in 542 children performed using 3 trocars, an “N-shaped closure,” and intracorporeal knot tying, and a 3.7 % recurrence rate was seen. In a follow-up series including 1,071 hernia repairs, recurrences decreased to 1.9 % in the most experienced surgeon. Other recent studies utilizing

an intracorporeal purse-string with sectioning of the distal sac and extra-corporeal knot tying have documented recurrence rates 1.5 %, similar to patients following open repair.

With proficiency and experience of the surgeon laparoscopic techniques and their outcomes improve.

Table 2 Previously reported single-port laparoscopic techniques for pediatric inguinal hernia

Study	Technique	Complete circuit suturing	Protection of vas deferens and testicular vessels	Subcutaneous tissue inclusion	Double ligation	Knot pusher for obese patients
Harrison et al. [3]	Extraperitoneal	-	Jump over them	-	-	-
Ozgediz et al. [4]	Extraperitoneal	-	Jump over them	-	-	-
Patkowski et al. [5]	Transperitoneal	-	Jump over them	-	-	-
Chang et al. [6]	Transperitoneal	+	Hydrodissection	-	-	-
Chang et al. [7]	Transperitoneal	+	Hydrodissection	+	-	-
Li et al. [8]	Transperitoneal	+	-	-	-	-
Liu et al. [9]	Transperitoneal	+	-	+	+	-
Present series	Transperitoneal	+	Hydrodissection	+	+	+

Cosmesis is a crucial factor when discussing laparoscopic methods. The single 5-mm trocar site scar is hidden very nicely within the umbilicus. Also, subjectively parents have been extremely satisfied with the outward appearance of the repair. We believe the LNAR technique is an excellent alternative to open surgery and a very

effective method for minimally invasive inguinal hernia repair in children. Using laparoscopy allows the surgeon to objectively identify asymptomatic or occult contralateral defects, use smaller incisions, and eliminate dissection of the cord structures potentially reducing the risk of cord injury.

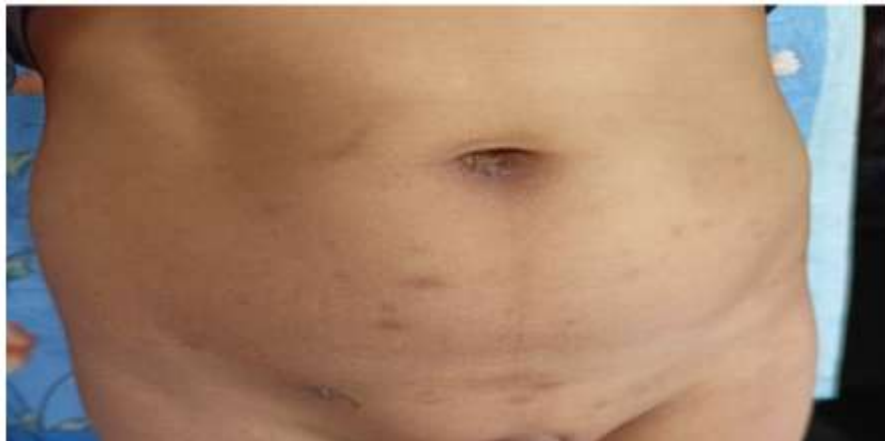

FIG 2 Cosmetic results at follow-up; scars almost not seen.

V. CONCLUSION

LASSO using an epidural needle as a handy technique has proved to be a safe and effective procedure. It is easy to perform with high parent satisfaction, invisible scarring, and good cosmetic results, and therefore is a worthy choice for PIH. This percutaneous ligation could doubly enclose the hernial sac without a peritoneal gap and

inclusion of subcutaneous tissues in the ligature. In our technique a complete circuit of suturing at the internal ring, avoiding trauma to the cord structure, and providing further tension-less knot tying. Single-port laparoscopic hernial repair using this technique is feasible and appears to be safe.



REFERENCES

- [1]. Bharathi RS, Arora M, Baskaran V (2008) Minimal access surgery of pediatric inguinal hernias: a review. *SurgEndosc* 22:1751–1762
- [2]. Chang YT (2010) Technical refinements in single port laparoscopic surgery of inguinal hernia in infants and children. *DiagnTherEndosc* 2010:392847
- [3]. Harrison MR, Lee H, Albanese CT, Farmer DL (2005) Subcutaneous endoscopically assisted ligation (SEAL) of the internal ring for repair of inguinal hernias in children: a novel technique. *J PediatrSurg* 40:1177–1180
- [4]. Ozgediz D, Roayaie K, Lee H et al (2007) Subcutaneous endoscopically assisted ligation (SEAL) of the internal ring for repair of inguinal hernias in children: report of a new technique and early results. *SurgEndosc* 21:1327–1331
- [5]. Patkowski D, Czernik J, Chrzan R et al (2006) Percutaneous internal ring suturing: a simple minimally invasive technique for inguinal hernia repair in children. *J Laparoendosc Adv Surg Tech* 16:513–517
- [6]. Chang YT, Wang JY, Lee JY et al (2008) One-trocar laparoscopic transperitoneal closure of inguinal hernia in children. *World J Surg* 32:2459–2463
- [7]. Chang YT, Wang JY, Lee JY, Chiou CS (2009) A simple singleport laparoscopic-assisted technique for completely enclosing inguinal hernia in children. *Am J Surg* 198(1):e13–e16
- [8]. Li B, Nie X, Xie H, Gong D (2012) Modified single-port laparoscopic herniorrhaphy for pediatric inguinal hernias: based on 1,107 cases in China. *SurgEndosc* 26(12):3663–3668
- [9]. Liu W, Wu R, Du G (2014) Single-port laparoscopic extraperitoneal repair of pediatric inguinal hernias and hydroceles by using modified Kirschner pin: a novel technique. *Hernia* 18(3):345–349
- [10]. Bharathi RS, Dabas AK, Arora M, Baskaran V (2008) Laparoscopic ligation of internal ring-three ports versus single-port technique: are working ports necessary? *J Laparoendosc Adv Surg Tech A*. 18(6):891–894
- [11]. Saranga Bharathi R, Arora M, Baskaran V. Minimal access surgery of pediatric inguinal hernias: a review. *SurgEndosc* 2008;22(8):1751–62.
- [12]. Harrison MR, Lee H, Albanese CT, et al. Subcutaneous endoscopically assisted ligation (SEAL) of the internal ring for repair of inguinal hernias in children: a novel technique. *J PediatrSurg*2005;40:1177–80
- [13]. Yonggang H, Changfu Q, Ping W, Fangjie Z, Hao W, Zicheng G, et al. Singleport laparoscopic percutaneous extraperitoneal closure of inguinal hernia using "two-hooked" core needle apparatus in children. *Hernia*. 2019;23(6): 1267–73. <https://doi.org/10.1007/s10029-019-01933-9>.
- [14]. Li S, Liu X, Wong KKY, Liu L, Li Y. Single-port laparoscopic herniorrhaphy using a two-hooked cannula device with hydrodissection. *J Pediatr Surg*. 2018;53(12):2507–10. <https://doi.org/10.1016/j.jpedsurg.2018.08.009>.
- [15]. Yilmaz E, Afsarlar CE, Senel E, Cavusoglu YH, Karaman I, Karaman A, et al. A novel technique for laparoscopic inguinal hernia repair in children: singleport laparoscopic percutaneous extraperitoneal closure assisted by an optical forceps. *PediatrSurg Int*. 2015;31(7):639–46. <https://doi.org/10.1007/s00383-015-3722-z>.
- [16]. Li S, Li M, Wong KK, Liu L, Tam PK. Laparoscopically assisted simple suturing obliteration (LASSO) of the internal ring using an epidural needle: a handy single-port laparoscopic herniorrhaphy in children. *J Pediatr Surg*. 2014; 49(12):1818–20. <https://doi.org/10.1016/j.jpedsurg.2014.09.027>.
- [17]. Liu W, Wu R, Du G. Single-port laparoscopic extraperitoneal repair of pediatric inguinal hernias and hydroceles by using modified Kirschner pin: a novel technique. *Hernia*. 2014;18(3):345–9. <https://doi.org/10.1007/s10029-013-1181-9>.
- [18]. Chang YT, Lin JY, Lee JY, Tsai CJ, Chiu WC, Chiu CS. Comparative mid-term results between inguinal herniotomy and single-port laparoscopic herniorrhaphy for pediatric inguinal hernia. *SurgLapascEndoscPercutan Tech*. 2012;22(6):526–31. <https://doi.org/10.1097/SLE.0b013e3182680842>.