



## Maxillary Sinus Lifting Procedures

Dr. Madhusudhan Amudalapalli, Dr.Ch.Siddesh kumar, DR.K.Jagadish ,  
Dr.L.Srikanth, Dr.B.Rajasekhar, Dr.M.Sai Bhargav  
*MDS, Sree Sai Dental College and Research Institute, Srikakulam*  
*Corresponding Author: Dr. Madhusudhan Amudalapalli MDS*

Date of Submission: 10-03-2025

Date of Acceptance: 20-03-2025

**ABSTRACT:** The maxillary sinus, a pyramidal cavity with a volume of 12-15 mL, is located between the nasal cavity and orbital floor, extending towards the zygomatic bone. Its ostium, crucial for drainage, is positioned in the upper inner wall, minimizing blockage risk during augmentation. The sinus floor's height varies with tooth loss, being level with the nasal floor in dentate individuals and about 1 cm lower in edentulous patients. Septa are present in 25%-31.7% of sinuses and are more common in atrophic ridges. The Schneiderian membrane's thickness is critical for presurgical assessment; a thickness up to 2 mm is normal, while  $\geq 5$  mm may indicate obstruction. Tooth loss leads to alveolar ridge resorption and increased sinus pneumatization, heightening the risk of membrane perforation. Sinus augmentation is indicated for inadequate bone height and atrophic arches but contraindicated in cases of recent radiation, uncontrolled diseases, and significant sinus pathologies. Minimally invasive techniques, including balloon elevation, hydraulic pressure, piezoelectric systems, and osseodensification, reduce risks associated with conventional sinus lifts. Direct sinus augmentation involves creating a buccal bone window, placing autogenous bone grafts, and potentially inserting implants simultaneously. Postoperative complications can include discomfort, inflammation, and infection, with advanced techniques helping to mitigate these risks and improve outcomes.

### I. INTRODUCTION:

The maxillary sinus, an air-filled cavity in the maxillary bone, is crucial in dental implant procedures, particularly in the posterior maxilla where bone volume may be compromised. Sinus augmentation, or sinus lift surgery, is performed to create adequate bone height for implant placement by elevating the sinus membrane and adding a bone graft.<sup>[1,3,9]</sup>

Recent advancements in minimally invasive techniques, such as balloon elevation, hydraulic pressure, and piezoelectric systems, have enhanced the safety and effectiveness of these procedures. Understanding the sinus anatomy, membrane characteristics, and proper case selection is essential for successful outcomes in implant dentistry.<sup>[6,7,10]</sup>

### ANATOMY:

The maxillary sinus holds approximately 12-15 mL of air in adults. It has a pyramidal shape, with its base near the nasal cavity, the upper part serving as the orbital floor, and the tip toward the zygomatic bone. An oval or slit-shaped drainage opening, known as the ostium, functions as an overflow opening and is positioned in the upper part of the inner wall. The space between the semilunar hiatus and the nasal floor can range from 18 to 35 mm, with an average of 25.6 mm. The position of the ostium minimizes the chances that it will be blocked during augmentation procedures. The base of the maxillary sinus extends from the premolar or canine region anteriorly and to the maxillary tuberosity posteriorly, often reaching its lowest point near the first molar area. In dentate adults, the maxillary sinus floor is the thickest of its walls and lies approximately at the same level as the nasal floor. However, in patients who have lost their teeth (edentulous), it is typically situated about 1 cm below the nasal floor. Septa within the sinus is composed of cortical bone and can be found both horizontally and vertically within the sinus floor. Some studies have observed septa in approximately 25%-31.7% of maxillary sinus and these septa can range from 2.5 to 12.7 mm in length and be in various locations within the maxillary sinus. Notably, there tend to be more septa in edentulous or atrophic (reduced in size) ridges than in partially edentulous or non atrophic arches.<sup>[11, 2, 16, 19, 20]</sup>

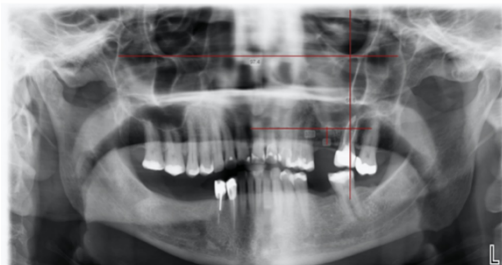
### THE SCHNEIDERIAN MEMBRANE:



The Schneiderian membrane is an important parameter during the presurgical analysis. Membrane thickness of up to 2 mm is considered physiological and favorable; however, thickness exceeding 5 mm is associated with sinus ostium obstruction. Recent CBCT studies indicate that 1 mm is a physiological value and 4 mm is pathological [1,2, 19, 20]

#### PRESENCE OF TEETH:

The resorption of the alveolar ridge and the maxillary sinus pneumatization are both profoundly influenced by the loss of posterior teeth. When a close relation between the sinus membrane and tooth roots has been detected, especially in the case of a single posterior missing tooth, the perforation risk increases. However, the probability of perforation decreases when two adjacent teeth are missing. This decreased probability could be due to the presence of sinus pneumatization in a small area with an irregular sinus floor shape. Shows the relationship between the extraction of the teeth and pneumatization of the maxillary sinus. [2,19]



#### Criteria for case selection:

Based on the amount of bone available below the antrum and the ridge width, Misch in the year 1987, proposed a classification for the treatment of edentulous posterior maxilla.

1. SA1: It has an adequate vertical bone for implants, that is, 12 mm. No manipulation of the sinus is required.
2. SA2: It has 0–2 mm less than the ideal height of bone and may require surgical correction.
3. SA3: It has just 5–10 mm of bone below the sinus.
4. SA4: It has <5 mm of bone below the sinus. [18,]

#### The following are indications for sinus augmentation [18]:

1. Patients with no history of sinus pathosis
2. Inadequate residual bone height (<10 mm of bone height)
3. Severely atrophic maxillary arch

4. Poor quality and quantity of bone in the maxillary posterior region.

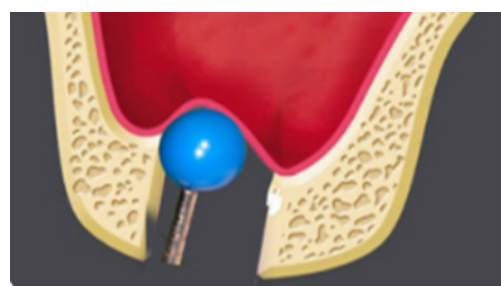
#### Sinus augmentation is contra-indicated in patients [18]:

1. Recent history of radiation therapy in maxilla
2. Uncontrolled systemic diseases such as diabetes mellitus
3. Acute/chronic maxillary sinusitis
4. Heavy smoking habit
5. Alcohol abuse
6. Psychosis
7. Severe allergic rhinitis
8. Tumour or large cyst in the maxillary sinus
9. Oro-antral fistula.

#### Minimally Invasive Techniques For Sinus Floor Elevation:

To overcome the drawbacks of conventional sinus lift procedures and minimize the risk of membrane perforations, various minimally invasive techniques were introduced. They include: Balloon elevation, Hydraulic pressure, Gel pressure, Piezoelectric system, Reamer mediators, Using CPS putty, Using osseodensification burs and CAD-CAM.

Minimally invasive antral membrane balloon elevation technique was introduced by Kfir et. al. to overcome certain disadvantages like buccal window preparation and larger incisions, a crestal osteotomy through conventional drills and osteotomes. The membrane elevation is achieved using barometric balloon inflator. [12,17, 18,19]

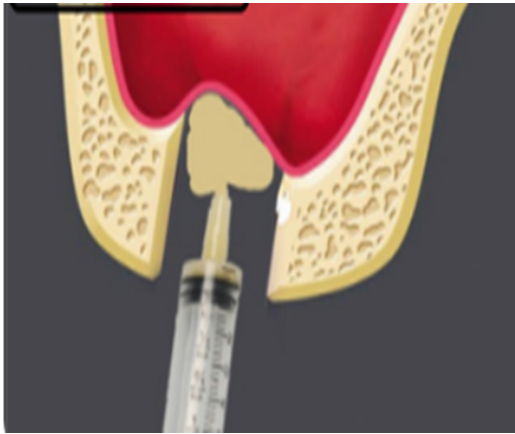


#### Hydraulic pressure to elevate sinus membrane:

Hydraulic pressure to elevate sinus membrane was introduced by Chen & Cha in the year 2005. A 2mm of round bur is used to create a pinhole on the sinus floor & membrane separation is achieved through hydraulic pressure delivered by the high speed hand piece. Sotirakis & Gonshor in the same year, suggested the use of a syringe filled with saline adjusted at an airtight interface to the osteotomy site and membrane elevation was

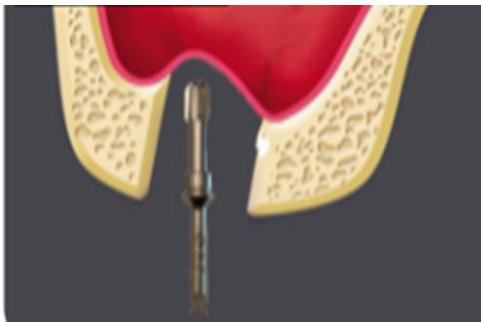


obtained through hydraulic pressure created by depression of the plunger of the syringe.<sup>[11, 12, 18, 21]</sup>



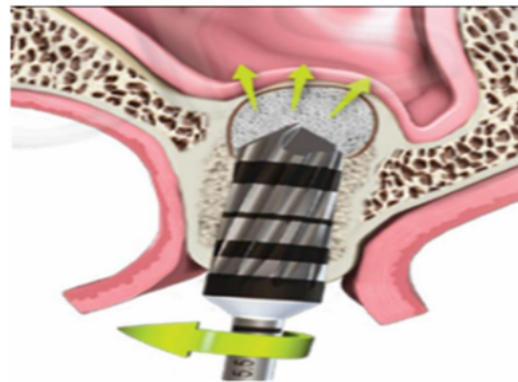
#### **Reamer mediated sinus floor elevation:**

They used specially designed reamers with one cutting edge (CE) at 85 degree cutting angle to prepare the osteotomy site and at a lower speed of 30-50 rmp along with bone graft material to elevate the sinus membrane. The flat end of the RE provides a light vertical pushing action on the sinus floor during the remaining that enables separation and elevation of sinus membrane<sup>[12, 18, 21]</sup>



#### **Indirect sinus elevation with osseodensification:**

The technique was introduced by Huwais in 2013. They used specially designed bur called Densah bus in counter clockwise direction at a speed of 800-1500 rpm to achieve osseodensification. The tip of these burs is designed to achieve apical condensation of bone enabling an indirect sinus elevation with reduced chances of perforation.<sup>[4, 13, 15, 18]</sup>



#### **Direct Sinus Augmentation Technique :**

Direct sinus augmentation is performed when the residual alveolar bone (RAB) height is 5 mm or less. The procedure includes:

##### **Preparation:**

Assess RAB height via imaging.

Harvest and grind autogenous bone from the mandibular ridge or chin<sup>[5, 15]</sup>

##### **Surgical Steps:**

##### **Apply local anesthesia:**

Incise along the RAB crest and create vertical releasing incisions.

Raise full-thickness labial and palatal flaps<sup>[4, 16]</sup>

##### **Sinus Exposure:**

Elevate the sinus membrane to access the maxillary sinus.

Create a buccal bone window and carefully elevate the membrane.<sup>[4, 18]</sup>

##### **Grafting and Implant Placement**

##### **Place and pack the bone graft:**

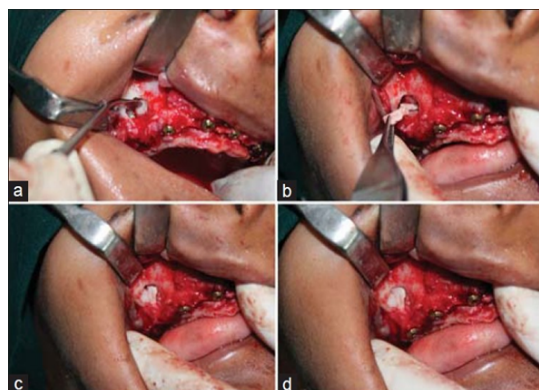
Position the implant using a stent, drill a pilot hole, and enlarge the site.

Insert the implant with a torque wrench.<sup>[5, 18]</sup>

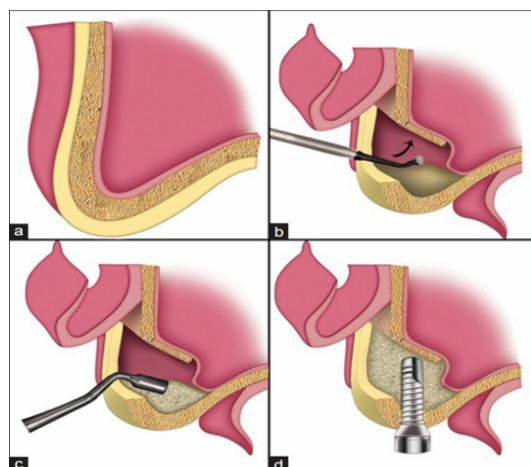
##### **Close with 3-0 Vicryl sutures:**

Provide antibiotics, painkillers, and nasal decongestants.

Monitor the patient clinically and radiologically.<sup>[5, 15]</sup>



Direct sinus lift with simultaneous implant placement with use of autogenous bone graft (a) In-fracturing and lifting of lateral window of right maxillary sinus, (b) Autogenous bone harvested from donor site being placed in newly created space, (c) Bone packed in the window, (d) Sinus floor augmented and implant placed.



Line diagrams illustrating direct sinus lift with simultaneous implant placement, (a) Atrophic posterior maxilla with residual bone height between sinus floor and alveolar crest inadequate for placement of dental implant, (b) Lateral wall of sinus in-fractured and membrane is elevated, (c) Grafted bone is densely packed in space created after lifting the membrane, (d) Augmented maxillary sinus with implant placed.

#### Acute Postoperative Complications:

Immediate postoperative complications include discomfort, inflammation, swelling, infection affecting both the surgical area and the sinus, sinusitis, bone loss, bleeding, bruising around the mouth and nose, and hematoma (particularly hemosinus). Other potential issues include the presence of emphysema, wound

opening, graft loss, fixture displacement or loss, the formation of an oroantral fistula, benign paroxysmal positional vertigo, and transient or permanent numbness in the palate.<sup>[8, 14, 16]</sup>

#### Chronic Postoperative Complications:

While implant periapical lesions are infrequent in the maxilla, they can arise in clinical situations in which excessive heat is generated during the drilling process. When the bone is assessed as hard, a longer time gap (at least one minute) between drilling stages is advised. Additionally, utilizing chilled saline instead of the standard room-temperature saline solution can be beneficial.<sup>[8, 14, 16]</sup>

#### Direct vs. indirect sinus lift procedure: A comparison :

This study evaluated the outcomes of direct (lateral antrostomy) and indirect (crestal approach) sinus lift techniques for dental implant placement. Key findings<sup>[5]</sup>:

**Pain and Swelling:** Both groups experienced mild pain and swelling initially, which resolved within a week. Post-operative discomfort was minimal and consistent with past studies.<sup>[5]</sup>

**Gingival Health:** Mild inflammation was noted initially but subsided in both groups by the end of the first week.<sup>[5]</sup>

**Bone Height Gain:** Direct lift showed a significantly greater bone height increase (8.5 mm) than Indirect lift, 4.4 mm, attributed to the larger surgical access in the direct approach.

**Implant Stability:** Stability rates were 100% in both groups across follow-ups, with no significant difference between techniques

#### A New Simplified Autogenous Sinus Lift Technique

Rehabilitating an atrophic maxilla typically requires bone augmentation due to limited bone availability. Standard sinus augmentation techniques often involve multiple stages, increasing risks when the sinus membrane is ruptured.

The bioactive kinetic screw (BKS) implant introduces a streamlined approach by enabling simultaneous grafting, sinus augmentation, and implant fixation in one step. For areas with less than 4 mm of vertical bone, additional bone is harvested from the mandibular retro-molar region. Experimental trials in synthetic maxillary models demonstrated the feasibility and effectiveness of the BKS implant, offering a simpler alternative for maxillary sinus



augmentation with specific benefits and limitations.<sup>[19]</sup>

## II. CONCLUSIONS:

Sinus augmentation is a procedure that plays a large role in maxillary implant placement in the posterior maxilla. Arriving at a diagnosis and treatment plan for the augmentation is paramount to the success of the graft and future implant placement. A variety of surgical maneuvers are used. The direct techniques offer the best visualization and control. The indirect techniques are good options when 3mm or less augmentation is required. The decision to place implants at the time of augmentation should be based on the availability of approximately 5mm of native bone to produce primary stability. When considering grafting material, autogenous bone has the best chance of success; however in areas of small grafting demands or if it is not possible to obtain sufficient autogenous bone, other materials heal well with good success. The use of non - autogenous materials in the office setting will continue to be the main choice for the practitioners. In spite of various techniques discussed in this article, the choice of specific technique depends on the case selection, posterior maxillary bone height, and measurements of maxillary sinus & associated pathologies.

## REFERENCES:

- [1]. Tiwana PS, Kushner GM, Haug RH. Maxillary sinus augmentation. *Dental Clinics*. 4.2006 Jul 1;50(3):409-2
- [2]. Woo I, Le BT. Maxillary sinus floor elevation: review of anatomy and two techniques. *Implant dentistry*. 2004 Mar 1;13(1):28-32.
- [3]. Garofalo GS. Autogenous, allogenic and xenogenic grafts for maxillary sinus elevation: literature review, current status and prospects. *Minerva Stomatologica*. 2007 Jul 1;56(7-8):373-92.
- [4]. Pal US, Sharma NK, Singh RK, Mahammad S, Mehrotra D, Singh N, Mandhyan D. Direct vs. indirect sinus lift procedure: A comparison. *National journal of maxillofacial surgery*. 2012 Jan 1;3(1):31-7.
- [5]. Balaji SM. Direct v/s Indirect sinus lift in maxillary dental implants. *Annals of maxillofacial surgery*. 2013 Jul 1;3(2):148-53.
- [6]. Lee JE, Jin SH, Ko Y, Park JB. Evaluation of anatomical considerations in the posterior maxillae for sinus augmentation. *World Journal of Clinical Cases: WJCC*. 2014 Nov 11;2(11):683.
- [7]. Mohan N, Wolf J, Dym H. Maxillary sinus augmentation. *Dental Clinics*. 2015 Apr 1;59(2):375-88.
- [8]. Patil PS, Bhongade ML. Sinus Augmentation Complications: Part-I Associated with Lateral Technique (Direct Approach): A Review. *Reviews of Complications from Lateral and Crestal (Direct Approach): A Review. Reviews of Complications from Lateral and Crestal Sinus Lifts*. 2016:6.
- [9]. Kim GS, Lee JW, Chong JH, Han JJ, Jung S, Kook MS, Park HJ, Ryu SY, Oh HK. Evaluation of clinical outcomes of implants placed into the maxillary sinus with a perforated sinus membrane: a retrospective study. *Maxillofacial plastic and reconstructive surgery*. 2016 Dec;38:1-6.
- [10]. Bathla SC, Fry RR, Majumdar K. Maxillary sinus augmentation. *Journal of Indian Society of Periodontology*. 2018 Nov 1;22(6):468-73.
- [11]. Yildiz H, Barbaros R, Bagis N. Maxillary Sinus Lifting. *International Journal of Experimental Dental Science*. 2019 Mar 1;7(2):91-7.
- [12]. Kumar VS, Swetha MS, Reddy KS. A consolidated review on sinus lift procedures. *Saudi J Oral Dent Res*. 2019;4:176-87.
- [13]. Barbu HM, Iancu SA, Jarjour Mirea I, Mignogna MD, Samet N, Calvo-Guirado JL. Management of Schneiderian membrane perforations during sinus augmentation procedures: a preliminary comparison of two different approaches. *Journal of Clinical Medicine*. 2019 Sep 19;8(9):1491.
- [14]. On SW, Cho SW, Yang BE. A review of rare complications of maxillary sinus floor augmentation. *Journal of the Korean Association of Oral and Maxillofacial Surgeons*. 2019 Dec 1;45(6):351-6.
- [15]. Shenoy SB, Talwar A, Thomas B, Ramesh A, Raghavendra A. Direct vs Indirect Sinus Elevation: A Literature Review. *MJDS*. 2020;5(2):15-21.
- [16]. Devameena S, Dinesh DS, LakshmiDevi G, Shanmugavadeivel G. Sinus lift procedures in dental implants: A



- literature review on techniques, recommendations, and complications. Indian Journal of Dental Sciences. 2020 Jul 1;12(3):180-6. Review. MJDS. 2020;5(2):15-21.
- [17]. Devameena S, Dinesh DS, LakshmiDevi G, Shanmugavadivel G. Sinus lift procedures in dental implants: A literature review on techniques, recommendations, and complications. Indian Journal of Dental Sciences. 2020 Jul 1;12(3):180-6.
- [18]. Gill HS, Nagpal A, Vaidya S, Jindal V. Maxillary Sinus Floor Elevation Techniques. International Journal Of Drug Research And Dental Science. 2020 Aug 18;2(3):29-44.
- [19]. Sinus floor elevation techniques- A review IP International Journal of Maxillofacial Imaging : IJMI, 2022 Oct 8; (3) : 96 – 100.
- [20]. Andreucci CA, Fonseca EM, Jorge RN. A new simplified autogenous sinus lift technique. Bioengineering. 2023 Apr 23;10(5):505.
- [21]. Alshamrani AM, Mubarki M, Alsager AS, Alsharif HK, AlHumaidan SA, Al-Omar A. Maxillary Sinus Lift Procedures: An Overview of Current Techniques, Presurgical Evaluation, and Complications. Cureus. 2023 Nov;15(11).
- [22]. Chittoria A, Malviya Y, Adurti A. Sinus Savvy: Exploring the Current Techniques of Maxillary Sinus Augmentation. Cureus. 2024 Jun 8;16(6).
- [23]. Wadhawan R, Khandelwal V, Mishra S, Bansal S, Bhattacharya S, Parambil AT. Cutting-edge methods and new frontiers in maxillary sinus lifting for enhanced dental restoration and implants: An analytical review. Journal of Advanced Medical and Dental Sciences Research. 2024 Aug;12(8).