



Metastatic choriocarcinoma to the cervical spine: A Case report

Dr. Pankaj Kumar, Dr. Dhananjaykumar, Dr. Om Prakash
Gupta

Submitted: 05-07-2022

Accepted: 18-07-2022

ABSTRACT

Background

Spinal metastasis of choriocarcinoma is very rare. Here we present a case of metastatic choriocarcinoma in the cervical spine. A 24-year-old woman was admitted to the hospital with complaints of progressive weakness and numbness in the all four limbs for 1 month and low-grade fever on & off for 1 month. She delivered a normal child 7 months back. MRI showed compressive myelopathy at C6-C7 vertebra. Surgical resection was performed by laminectomy to remove the vertebral lesion. Choriocarcinoma was diagnosed after histological examination. After surgery and six courses of adjuvant chemotherapy and physiotherapy, she was able to walk again. One year after diagnosis and treatment, she is now healthy without any evidence of disease.

Conclusion

Choriocarcinoma with spinal metastasis is an unusual phenomenon. Early diagnosis and surgery plus chemotherapy is highly effective for treatment of this condition.

Key words

choriocarcinoma; spinal cord compression; metastases; quadriplegia.

I. INTRODUCTION

It has been estimated that 5% of cancer patients have spinal extradural metastases although all extradural metastases are not clinically evident.¹ In general metastatic invasion of the spinal axis is mainly osseous secondarily extradural. According to many published series, the majority of the metastases originate from lung, breast and lymphoma but in some cases the original site of the tumour could not be detected.^{1,2,3} Choriocarcinoma is a malignant disease characterized by the secretion of human chorionic gonadotropin (hCG). It is highly malignant form of gestational trophoblastic neoplasia (GTN), arising in any type of pregnancy and is more common in patients with a history of hydatidiform mole.^{4,5} Choriocarcinoma is composed of abnormal cytotrophoblast and

syncytiotrophoblast with hyperplasia and anaplasia, and characterized by absence of chorionic villi, haemorrhage, and necrosis. The direct invasion into the myometrium and vascular invasion resulting in spread of choriocarcinoma into distant sites, most commonly to the lungs, vagina, brain and liver.^{4,5,6}

The occurrence of choriocarcinoma with spinal metastasis is extremely rare.^{7,8,9} We present a rare case of a patient who primarily presented with symptoms of compressive cervical myelopathy caused by metastasis of choriocarcinoma to cervical vertebrae. The patient was then successfully treated with laminectomy and decompression with biopsy for confirmation of diagnosis, followed by chemotherapy. We also present a review of the literature with particular emphasis on the diagnostic and therapeutic issues related to the choriocarcinoma.

Case Presentation

A 24 years old female with complaints of weakness of all four limbs for one month, numbness in both upper limbs for one month. She also had complaints of low grade fever on & off for one month, for which antitubercular treatment started by local physician. History of excessive bleeding per vagina for 4 days.

The patient was P3L2A3. The three pregnancy was terminated as spontaneous abortions, 4th and 5th pregnancies were delivered spontaneously at term. Age of youngest child was seven months and was on regular breast feedings.

On initial examination revealed upper motor neuron type quadriplegia, power both lower limbs 2/5 and both upper limbs 3/5, an impaired sensation below the level of T1. Increased Urinary frequency and urgency noted. MRI discovered epidural soft tissues around C6-C7 cervical canal with compressive myelopathy, this epidural mass contained multiple flow voids and heterogenous enhancement, which suggests hypervascularity (Figure 1).

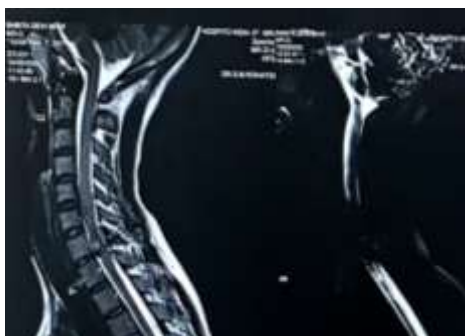

Figure 1: MRI showing epidural soft tissues mass with flow voids at C6-C7 level with compressive myelopathy.

She underwent a laminectomy to remove the epidurally located soft tissue mass, which was causing compression of the spinal cord. Intraoperatively tumour was greyish and highly vascular. Pathological examination revealed blackish brown coloured tumour mass consisting of multinuclear syncytiotrophoblastic cells with large eosinophilic cytoplasm around the mononuclear cytotrophoblastic cells (Figure 2). These findings were consistent with choriocarcinoma.

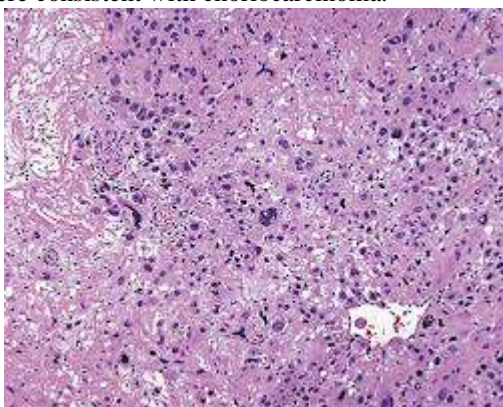


Figure 2: Histopathology slide suggestive of choriocarcinoma.

After histopathological report patient was further evaluated for choriocarcinoma. On local per speculum examination there were **4 irregular growths**, each ~ **2 cm x 2 cm**: 1 in sub-urethral area, 2 in upper right lateral part of anterior vaginal wall & 1 in middle 1/3rd of posterior vaginal wall, **bleed to touch**, cervix normal, slight bleeding present from os (Figure 3). The CT scans of the chest and abdomen showed multiple variable size nodules, about 2-5 mm, in both lungs and liver that were most likely metastases. The CT scan of brain was normal. USG lower abdomen showed bulky uterus with polypoidal mass lesion in uterus (Figure 4).

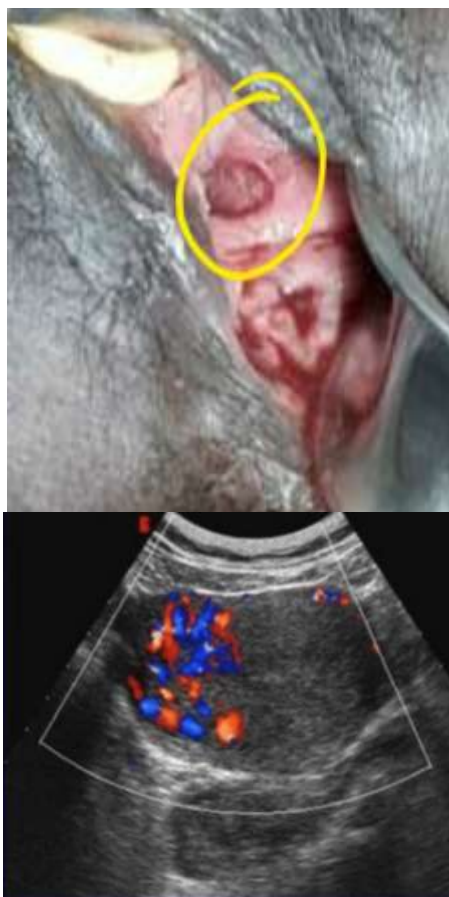


Figure 3 & 4: per speculum examination of genitalia & ultrasonography of uterus.

Postoperative laboratory investigation revealed β -hCG level of 80,000 mIU/ml with other normal blood studies. The patient then underwent multi-agent chemotherapy in the form of six courses of EMA-CO (etoposide, methotrexate, actinomycin D, cyclophosphamide, and vincristine). Her β -hCG level in serum was normal (< 1 mIU/mL) after a total of 3 courses of EMA-CO. At the end of chemotherapy, the marrow infiltration at C6 and C7 bodies were markedly decreased. The surrounding soft tissue and epidural soft tissue disappeared and could not be seen on the subsequent MRI examination. She was sent for rehabilitation and physiotherapy. She showed improvement in her neurological status, and she was able to walk again. She is now in tumour remission 12 months after diagnosis.

II. DISCUSSION

Approximately 30% of choriocarcinoma patients show metastasis at the time of diagnosis.¹⁰ Early hematogenous and widespread metastasis is well documented.¹¹ The most common sites of



metastasis are the lungs and the vagina whereas metastasis within the bony system, especially in the spine is extremely rare, as also evident from our case.

To our knowledge, from the published literature, only five to six cases of spinal bone metastasis from choriocarcinoma have been reported.^{7,8,9}

In reported cases, the age at diagnosis has ranged from 21 to 45 years. Symptoms arising due to the spread of cancer to coexisting organ(s) were the presenting complaints, such as central nervous system symptoms of headache or visual field defect or paraplegia or rarely as pulmonary system symptom of dyspnoea. Our case presented with quadriplegia due to cancer in the epidural sac with compression of cervical spine.

Although choriocarcinoma can follow any type of pregnancy, approximately 50% of the cases of choriocarcinoma are preceded by a hydatiform mole.

The remaining 50% are equally distributed between normal antecedent term gestational and abortion or ectopic pregnancy.^{4,5,6,9} In our case, the patient was diagnosed with choriocarcinoma following normal antecedent term pregnancy.

The diagnosis was made by clinical history, imaging, hCG level, and histopathologic examination.^{7,8,9} Imaging such as CT scan or MRI is useful in diagnosis and planning of surgery. MRI in our case revealed epidural soft tissues around C6-C7 cervical canal with compressive myelopathy, this epidural mass contained multiple flow voids and heterogeneous enhancement, which suggests hypervascularity. At the time of diagnosis, serum hCG levels are usually elevated, like in our case, levels ranged from 15,000 to more than 100,000 mIU/ml.^{7,8,9}

Choriocarcinoma is one of the malignant tumours that is most sensitive to chemotherapy.^{5,6} A patient with spine metastasis, as our case, is classified as "high risk" and is improbable to respond to single chemotherapy. Naito found that a choriocarcinoma patient who has spine and lung metastasis did not respond to 3 courses of methotrexate. However, the patient was successfully treated by total en bloc spondylectomy and radiotherapy.⁹ To date it is agreed that patients with high risk GTN should be treated initially with multiagent chemotherapy especially EMA-CO with or without adjuvant surgery or radiotherapy. Cure rates for high risk GTN of 80-90% are now achievable with intensive multimodality.^{5,6} However, the best treatment for patients with spinal metastasis has not been established because of its rarity.

Surgery for a case of spinal metastasis of choriocarcinoma was firstly reported by Naito et al. in 2009.⁹ Surgery is indicated when a massive mass effect is due to tumour mass or hematoma. In this situation, spine surgery such as spondylectomy or laminectomy is required to provide acute decompression or to control bleeding [6-7]. Because choriocarcinoma is extremely haemorrhagic, it is quite possible the surgical procedures may have exacerbated the invasive and metastatic potential of this tumour.

Thus, preoperative angiographic embolization, or at least angiography of the tumour should be used to reduce perioperative haemorrhages and evaluate vascularity of the tumour site, respectively.^{9,12} Lee reported a good course for choriocarcinoma with a patient with spine, epidural, lung and brain metastasis who was managed successfully by embolization of the lesion of the lumbar spine, followed by an injection of polymethylmethacrylate in the L3 vertebral body, total laminectomy of L3, subtotal removal of the epidural mass, screw fixation of L2 and L4, and multiagent chemotherapy (EMA-CO).¹²

When central nervous system metastases are present, radiotherapy (whole brain irradiation) is usually given simultaneously with the initiation of systemic chemotherapy.^{5,6} Radiotherapy was performed as adjuvant treatment in four previous cases of spine metastasis of choriocarcinoma.^{7,8,9} This therapy can also be utilized when spine metastases are present. In our case, the patient was successfully treated by 6 courses of EMA-CO after laminectomy without radiotherapy. Despite improvements in treatment modality and the use of combined modality treatment with chemotherapy, surgery and radiation, the prognosis for these choriocarcinoma cases with spinal metastasis is unfavourable. Earlier diagnosis and multimodality treatment is crucial for significant reduction in mortality.

III. CONCLUSION

We have reported an uncommon case of metastatic choriocarcinoma to the cervical spine, lung and liver, which was successfully treated by laminectomy with multiagent chemotherapy. The neurological symptoms, history of a hydatidiform mole or normal pregnancy, and the possibility of metastatic GTN should always be considered especially in fertile females. In our case, the diagnosis was made by clinical history, imaging, and hCG levels. The treatment involved multiagent chemotherapy with or without surgery or radiotherapy.



REFERENCES

- [1]. Brihaye J, Ectors P, Lemort M, Houtte PV. The management of spinal epidural metastases. *Advances and Technical Standards in Neurosurgery* 1988; 16: 121 ± 176.
- [2]. Dunn RC, Kelly WA, Wohns RNW, Howe JF. Spinal epidural neoplasia. A 15 years review of the results of surgical therapy. *J Neurosurg* 1980 52: 47 ± 51.
- [3]. Young RF, Post EM, King GA. Treatment of Spinal Epidural Metastases. Randomized prospective comparison of laminectomy and radiotherapy. *J Neurosurg* 1980; 53: 741 ± 748.
- [4]. Scott JR, Di Saia PJ, Hammond CB. Gestational trophoblastic neoplasms. 8th edn. In: Scott JR, DiSaia PJ, Hammond, editors. *Danforth's Obstetrics and Gynecology*. Philadelphia, PA: Lippincott Williams & Wilkins. 1999: 927-937.
- [5]. Seckl MJ, Sebire NJ, Berkowitz RS. Gestational trophoblastic disease. *Lancet*. 2010; 376: 717-729.
- [6]. Lurain JR. Gestational trophoblastic disease I: epidemiology, pathology, clinical presentation and diagnosis of gestational trophoblastic disease, and management of hydatidiform mole. *Am J Obstet Gynecol*. 2010; 203: 531-539.
- [7]. Vani R, Kuntal R, Koteswar RK. Choriocarcinoma following term pregnancy with bone metastasis. *Int J Gynaecol Obstet*. 1993; 40: 252- 253.
- [8]. Menegaz RA, Resende AD, da Silva CS, Barcelos AC, Murta EF. Metastasis of choriocarcinoma to lumbar and sacral column. *Eur J ObstetGynecolReprod Biol*. 2004; 113: 110-113.
- [9]. Naito Y, Akeda K, Kasai Y, Matsumine A, Tabata T, Nagao K, et al. Lumbar metastasis of choriocarcinoma. *Spine (Phila Pa 1976)*. 2009; 34: E538-543
- [10]. Sierra-Bergua B, Sánchez-Marteles M, Cabrerizo-García JL, Sanjoaquin- Conde I. Choriocarcinoma with pulmonary and cerebral metastases. *Singapore Med J*. 2008; 49: e286-288.
- [11]. Ko JK, Cha SH, Lee JH, Choi CH. Intramedullary spinal cord metastasis of choriocarcinoma. *J Korean Neurosurg Soc*. 2012; 51: 141-143.
- [12]. Lee JH, Park CW, Chung DH, Kim WK. A case of lumbar metastasis of choriocarcinoma masquerading as an extraosseous extension of vertebral hemangioma. *J Korean Neurosurg Soc*. 2010; 47: 143-147.