



## “Observational Study of Combined Femoral and Sciatic Nerve Block for Lower Limb Surgeries”

‘Dr. Dharmendra Mishra(M.D), Dr. Bansari Kantharia (M.D.)

*Anaesthesiologist, medical officer, chc zankhvav,surat,gujarat*

*Professor (additional), department of anaesthesiology, government medical college, surat,gujarat,india.*

Submitted: 01-07-2022

Accepted: 08-07-2022

### I. INTRODUCTION

Among the regional anaesthetic techniques adopted for lower limb surgeries, peripheral nerve block are gaining popularity because they reduce the possibility of complications and side effects such as hypotension, bradycardia, meningitis, postdural puncture headache, neurological deficit etc. associated with central neuraxial blocks<sup>1,2</sup>. Also no preoperative fasting, special preparation or preoperative optimization, is required due to peripheral location of surgical site and potential to block pain pathway at multiple levels<sup>2</sup>.

Combined femoral and sciatic nerve block is useful technique for providing anaesthesia and postoperative analgesia for many operative procedures for below knee and foot surgeries<sup>3</sup>. There are different techniques adopted to block sciatic nerve among which Raj approach (posterior approach) is an accurate and simple technique as it depends on identification of two anatomical landmark i.e. greater trochanter and ischial tuberosity which are easily palpable in supine lithotomy position<sup>5</sup>. In addition to the simplicity of needle insertion & site identification, this technique is desirable as patient remains in supine position and moving the patient into Sim's position is not required as sciatic nerve is superficial due to the reduced depth in this position resulting in decreased dose & better quality of nerve blockade<sup>5</sup>.

The use of ultrasound along with peripheral nerve stimulator (Dual technique) having been extensively used in patients undergoing below knee surgeries especially in patients with critical comorbidities not able to tolerate alteration of hemodynamic status, provides greater accuracy and speed of block performance, greater block success rate and faster onset times<sup>4</sup>.

Various local anaesthetic agents in different concentration have been used for combined femoral sciatic nerve block. Ropivacaine, a long acting amide local anaesthetic related structurally to bupivacaine, is less lipophilic

which results in less central nervous system toxicity and cardiotoxicity<sup>1</sup>. Considering large volume of drug needed to block two major nerves of lower limb, lignocaine which has an early onset and short action can be added with ropivacaine to increase volume of drug.

The present prospective study was done to block femoral and sciatic nerve using ‘Dual technique’ (USG+PNS) with 0.75% Ropivacaine, 2% Lignocaine, Dexamethasone (8mg) for patients undergoing below knee orthopaedic surgeries to observe and evaluate quality of block, quality of analgesia and hemodynamic parameters.

### II. MATERIAL AND METHOD

After obtaining approval from the institutional ethics committee, this prospective observational case series study was conducted on forty four adult patient scheduled for lower limb surgeries under combined femoral sciatic nerve block (FSNB) using peripheral nerve stimulator and ultrasound guidance between December 2020 to October 2021.

#### ❖ Inclusion Criteria:

- 1) Patients aged 18-65 years.
- 2) Patient belonging to ASA grade I to III.
- 3) Patients scheduled to receive a FSNB for lower limb surgeries.

#### ❖ Exclusion Criteria:

- 1) Patients refusal.
- 2) Neuromuscular disease and established peripheral neuropathy.
- 3) Major cardio-respiratory disorder or pregnancy.
- 4) Haemostatic abnormalities or on anticoagulant therapy.
- 5) Skin infection at the site of needle insertion.
- 6) Chronic pain syndromes or receiving chronic analgesic therapy.
- 7) Patients with reported history of allergy to any of the study drugs.

- All the patients were subjected to detailed pre-



anaesthetic check-up. Detailed history of each patient was obtained and thorough general & systemic examination was carried out. All the patients were investigated for complete hemogram, random blood sugar, serum creatinine, chest X-ray, and electrocardiography.

- On the day of the surgery, overnight fasting status was confirmed and informed written consent was taken. In the preoperative room and intravenous line was secured and pulse rate, blood pressure and respiratory rate were recorded. In operation theatre pulse oximetry, non-invasive blood pressure and ECG monitoring was done and baseline values were recorded. Following which all patients received dexmedetomidine 1 mcg/kg over 10 minutes.

In supine position, after proper aseptic and antiseptic precautions, femoral nerve was identified lateral to the femoral artery using an 8 to 13MHz linear phased array transducer (E1 EXP; SONOSCAPE) equipped on an ultrasound machine. Under ultrasound guidance, a 20-G 10cm insulated short bevel stimplex<sup>®</sup> needle was attached to PNS and introduced from lateral to medial side toward the femoral nerve perpendicular to the ultrasound beam (In-plane technique) at the level of inguinal ligament. The nerve stimulator was initially set to deliver 1.0 mA. With proper needle position, advancement of the needle was done such to elicit stimulation of femoral nerve i.e. patellar twitch at 0.3-0.5 mA current. After negative aspiration 18 mL of study drugs was slowly injected than firm pressure was applied on the thigh about 2-4 cm below the insertion point of the needle to favour proximal spread of local anaesthetic solution.

#### Femoral block:

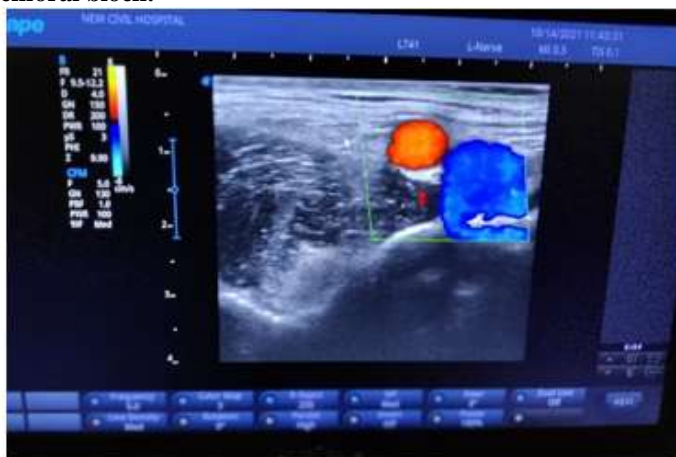


Figure: Doppler mode view of femoral nerve

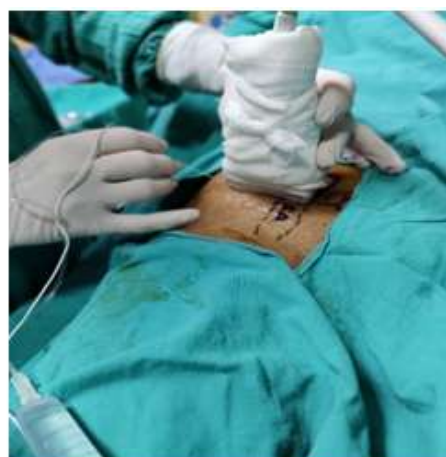


Figure: USG and PNS guided FNB

#### Sciatic Nerve Block:

In supine position hip and knee joints were flexed at 90° (Raj approach). After sterile preparation of nerve block region, curvilinear USG probe (5-8Hz) was placed between the ipsilateral ischial tuberosity and greater trochanter and the sciatic nerve was identified in the intermuscular plane of the gluteus maximus and quadratus femoris muscles. Under ultrasound guidance, a 20-

G 10cm insulated short bevel stimplex<sup>®</sup> needle attached to PNS was introduced from lateral to medial side toward the nerve perpendicular to the ultrasound beam (In-plane technique). The nerve stimulator was initially set to deliver 1.0 mA. With proper needle position, advancement of the needle was done to elicit plantar/dorsi flexion at 0.3-0.5 mA current. After negative aspiration 22 mL of study drugs was slowly injected.

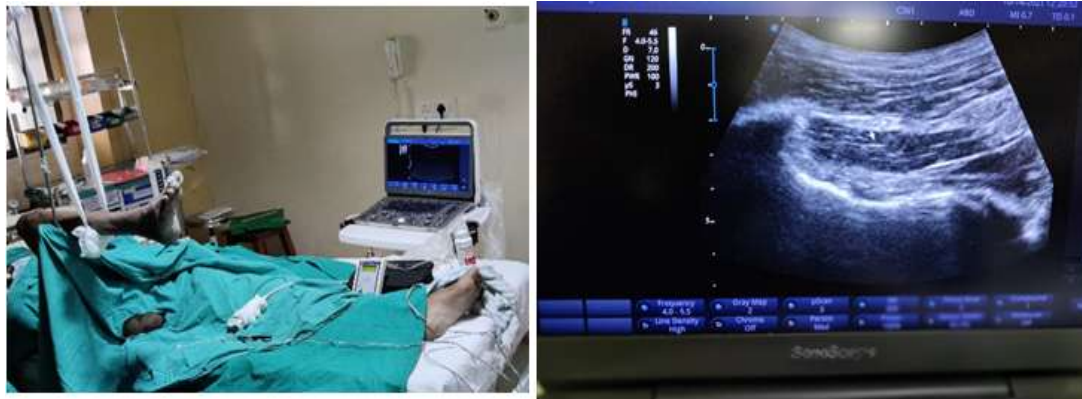

Figure: USG and PNS guided SNB

Pulse rate, systolic blood pressure, diastolic blood pressure, oxygen saturation, sensory and motor blockade and analgesia was monitored every 5 min up to 30 min, then every 15 min up to 2 hrs, there after hourly up to 6 hrs then at 9<sup>th</sup>, 12<sup>th</sup> & 24<sup>th</sup> hour after giving both blocks.

- **Statistical analysis:** Results were statistically analysed by student's t-test using SPSS software version 18.0 and results were expressed as mean  $\pm$  SD using MS Excel 2013. The results were considered significant according to the 'p' value given below:  
p value  $>0.05$  insignificant.  
p value  $<0.05$  significant.  
p value  $<0.001$  highly significant.

### III. OBSERVATION AND RESULTS

This study was conducted in 44 patients undergoing lower limb surgeries under combined femoral and sciatic nerve block. Mean and SD were calculated using MS excel program and statistical analysis was done using student's T-test with SPSS software.  $P < 0.05$  was considered statistically significant.

Total 44 Patients with age ranging from 18 to 65 years scheduled to undergo lower limb surgeries were included in this study. **Mean age was  $42.80 \pm 9.51$  years.**

Patients of either sex were included in this study. From all the patients included in this study, **95.45 % (n=42) were male and 4.55 % (n=2) were female.**

Patients belonging to ASA grade I, II and III were included in this study. In this study from total 44 patients, **1(2%) patients were in ASA grade I, 28(64%) patients were in ASA grade II and**

**15(34%) patients were in ASA grade III** as all patients were middle age and some had well controlled comorbid conditions.

**Time for onset of sensory blockade** was taken as the time from injection of the study drug to loss of pinprick sensation.

**Time for onset of motor blockade** was taken as the time from injection of the study drug to unable to move the foot.

The mean time for onset of sensory blockade was  **$14.86 \pm 5.14$  min.**

The mean time for onset of motor blockade was  **$22.22 \pm 4.70$  min.**

**Total duration of sensory blockade** was defined as the time from onset of sensory blockade to complete restoration of sensation.

**Total duration of motor blockade** was defined as the time from onset of motor blockade to complete restoration of normal muscular function.

The mean total duration of sensory blockade was  **$7.66 \pm 1.83$  hrs.**

The mean total duration of motor blockade was  **$6.94 \pm 2.38$  hrs.**

**Success rate of block was 81.82 % (n=36):** complete block (68.18%, n=30) + Inadequate block (13.64%, n=6).

In case of failed block (n=8) general anaesthesia was given.

The **mean VAS score** upto 12 hours was less than 1.

**Total duration of postoperative analgesia** was taken as time from injection of study drugs to the time when first requirement of rescue analgesic was demanded by patient (VAS  $\geq 4$ ).

The mean total duration of postoperative analgesia was  **$14.83 \pm 2.09$  hrs.**

In this study, 36 successful blocked patients required mean  **$1.28 \pm 0.45$  dose** of injection Tramadol (2mg/kg) as rescue analgesic postoperatively within 24hrs.



In this study, the baseline mean pulse rate was **82.97±15.58 per min**. At 30<sup>th</sup> & 45<sup>th</sup> min, a statistically significant decrease in mean pulse rate was observed while in rest of the period, it was comparable to baseline.

Baseline mean systolic blood pressure was **118.74±15.60 mm of Hg**. There was no statistically significant difference observed in mean systolic blood pressure from the baseline value throughout the observation period.

Baseline mean diastolic blood pressure was **80.89±9.98 mm of Hg**. There was no statistically significant difference observed in mean systolic blood pressure from the baseline value throughout the observation period.

Baseline mean oxygen saturation was **97.97±1.21 %**. No patients developed fall in oxygen saturation less than 95%.

#### Complications:

Patients were observed for complications such as hypotension, hypertension, bradycardia, tachycardia, nausea, vomiting, hematoma, local anaesthetic systemic toxicity and nerve injury during time of giving block & in perioperative period. **No complication** was observed in any of the patients out of 44 patients.

#### IV. DISCUSSION

In our study all the nerve blocks were performed using dual USG and PNS for nerve location and drug deposition. Labat's technique is commonly used but we used Raj approach to block sciatic nerve which is advantageous because:

- 1) It depends only on identification of two landmarks i.e. greater trochanter and ischial tuberosity. Sciatic nerve lies at the midpoint of imaginary line joining these two landmarks where it is superficial as compared to trans gluteal approaches<sup>3</sup>.
- 2) It provides simplicity of needle insertion, site identification<sup>3</sup>.
- 3) This technique is also desirable as patient remains in supine position and moving the patient into Sim's position is not required as in Labat's technique.

As far as we know, there is no publication of a similar study using USG with PNS for blocking both femoral nerve (Inguinal approach) and sciatic nerve (Raj approach) in supine position using ropivacaine and dexamethasone as adjuvant.

Ropivacaine, a long acting amide local anaesthetic related structurally to bupivacaine, is less lipophilic which results in less central nervous system toxicity and cardiotoxicity<sup>2</sup>. Considering the large volume of drugs needed for two major nerves

blocks of lower limb, we combined ropivacaine & lignocaine in its therapeutic dose, as latter has an early onset, to increase the volume of drug and to avoid overdose & toxicity of drugs.

Addition of corticosteroids as adjuvant like dexamethasone to local anaesthetic like ropivacaine prolongs the duration of block by the inhibition of synthesis and/or release of various inflammatory proteins and increases the production of anti-inflammatory proteins (lipocortin-1) receptor antagonist and hence is a very potent and anti-inflammatory and immunosuppressive agents<sup>2</sup>. Perineural injection of steroid is reported to influence post-operative analgesia and it is mediated by attenuation of the inflammatory mediators, reducing ectopic neuronal discharge and inhibiting potassium channel mediated discharge of nociceptive C- fibers<sup>26</sup>. Various steroids have been used for this purpose but dexamethasone, a synthetic glucocorticoid derivative is preferred as it is 25-30 times more potent than hydrocortisone and without any mineralocorticoid activity<sup>4</sup>.

In the present study out of 44 patients, 30(68.18%) patients had complete effect of block with no pain or discomfort during surgery. 6(13.64%) patients had mild pain who required ketamine 0.5mg/kg intravenously during surgery. 8(18.18%) patients, had no effect, were given general anaesthesia. **Success rate of block was 81.82% (n=36)**.

The use of ultrasound along with peripheral nerve stimulator having been extensively as it provides greater accuracy, increases speed of block performance, greater block success rate and faster onset times.

In our study, at 30<sup>th</sup> & 45<sup>th</sup> min a statistically significant decrease in mean pulse rate was observed probably due to the preoperative dexmedetomidine infusion and/or pain relief due to block effect. Dexmedetomidine is a sympatholytic drug that acts as an alpha 2 agonist. It does  $\alpha_2$  receptor stimulation at the spinal cord level and at supraspinal sites. Its non-spinal mechanism is through activation of  $\alpha_{2a}$  receptors and inhibition of conduction of nerve signals through C and A $\delta$  fibers<sup>28</sup>. When used as a premedication produces sedation, anxiolysis, less cardiovascular variability, analgesia and sympatholysis.

Another contributing factor is the use of USG and PNS which helps in guiding the block needle accurately and minimizes the number of needle pricks, thereby causing less discomfort, anxiety and hemodynamic stress response.

With the advancement of newer techniques and the combined use of USG and PNS, multiple pricks are avoided causing less





discomfort to the patients. Use of dexmedetomidine provides sedation, anxiolysis and hemodynamic stability which plays an important role in avoiding complications.

## V. CONCLUSION

Combined FSNB under USG & PNS guidance with 0.75% Ropivacaine 20ml, 2% Lignocaine 10ml, 8mg Dexamethasone diluted with normal saline to make total 40ml volume produces good anesthesia and postoperative analgesia for below knee lower limb surgeries.

1. It provides sensory and motor blockade for approximately 6 to 7 hours.
2. It provides prolonged postoperative analgesia for about 14 hours.
3. It reduces postoperative analgesic requirement in 24 hours.
4. Preoperative dexmedetomidine infusion provides good anxiolysis, sedation, and hemodynamic stability.
5. The combined use of USG and PNS provides accurate drug deposition and avoids multiple pricks causing less discomfort to the patients.

**It is thus, concluded that femoral and sciatic nerve blocks under USG and PNS guidance provides safe& effective anaesthesia,postoperative analgesia without any complications with hemodynamic stability in patients undergoing below knee lower limb surgery.**

## REFERENCES

- [1]. Bansal L, Attri JP, Verma P. Lower limb surgeries under combined Femoral and Sciatic nerve block. *Anesth Essays Res.* 2016; 10(3):432-436. doi:10.4103/0259-1162.177186
- [2]. Kumar, D. P., & Kaushik, D. A. (2018). Orthopedic Surgeries of Lower Limb under Combined Femoral and Sciatic Nerve Block: A Comparative Study in RMCH & RC. *International Journal of Innovative Research in Medical Science*, 3(05), 2024 to 2027.
- [3]. Dr. Bindi B. Palkhiwala, Dr. Pauravi T. Bhatt. Study of combined Femoral and Sciatic nerve blocks for lower limb surgical procedures. *GMJ* 2015; 70(1): 36-40
- [4]. Ibrahim Walash IA, Mostafa AM, Abdel-Maksoud Rayan AA, Sultan WE. Ultrasound-guided femoro-SNB with and without using nerve locator for below-knee surgeries. *Res Opin Anesth Intensive Care* 2020;7:1-7
- [5]. Robards C, Wang RD, Clendenen S, Laddie B, Greengrass R. Sciatic nerve catheter placement: success with using the Raj approach. *Anesth Analg.* 2009 Sep;109(3):972-5. doi: 10.1213/ane.0b013e3181ae0ee7. PMID: 19690275.
- [6]. David L Brown; An Atlas of regional anaesthesia, 4<sup>th</sup> edition, chapter-10 Lower extremity anatomy, page-89-96.
- [7]. Gray's Anatomy. Anatomical basis of clinical practice. Elsevier publication, 39<sup>th</sup> edition, section 8 – pelvic girdle and lower limb.
- [8]. Miller Ronald D. Anaesthesia textbook: Churchill Livingstone 9<sup>th</sup> edition, vol-1, Peripheral Nerve Blocks and Ultrasound guidance for regional anaesthesia. 2020
- [9]. www.nysora.com/foundations-of-regional-anaesthesia/equipment/electrical-nerve-stimulators-localization-peripheral-nerves
- [10]. Stoelting K. et al: Pharmacology and physiology in anaesthesia practice, Anaesthesiology Textbook 4<sup>th</sup> edition (lipincott William and Wilking); Chapter-7.
- [11]. Brunton LL, Lazo JS, Parker KL. Local anaesthetic In: Goodman and Gilman 's. The pharmacological basis of therapeutics. 11edn. 2006; p.369-387.
- [12]. K.D.Tripathi, Essentials of Medical Pharmacology, 8th edition 2019; chapter 26:386-398, chapter 20:306-319.
- [13]. Admir Hadzic ,Textbook of Regional Anaesthesia and Acute Pain Management , 2<sup>nd</sup> edition; Part-2 section -2 chp-7,9,10; Part-2 section -3 chp-12,14; Part-3 section-1 chp-28,30; Part-3 section-4 chp-33; Part-9 chp-60; Part-15 section -3 chp-82.
- [14]. www.nysora.com/foundations-of-regional-anaesthesia/equipment/introduction-ultrasound-guided-regional-anaesthesia
- [15]. Harold Ellis, stanly Feldman, Anatomy for anaesthetic 1997;160-195
- [16]. C.A.Pinnock- Peripheral Nerve blockade 1996;3:76-85
- [17]. Beck G.P: Anterior approach to Sciatic nerve. *Anaesthesiology* 1963;24:222.
- [18]. Raj pp, Parks RI, Watson TD, et al. New single position supine approach to Sciatic - FNB. *Anaesthesia Analgesia* 1975;54:489.
- [19]. Ichiyannagi K: Sciatic nerve block: Lateral approach with the patient supine. *Anaesthesiology* 1959;20:601.



- [20]. Mansour N.Y: "Re-evaluating the SNB-another landmark for consideration". *Reg. Anesth.* 18: 322-323,1993.
- [21]. Casati A, Fanelli G, Borghi B, Torri G. Ropivacaine or 2% mepivacaine for lower limb peripheral nerve blocks. Study Group on Orthopedic Anaesthesia of the Italian Society of Anaesthesia, Analgesia, and Intensive Care. *Anesthesiology.* 1999 Apr;90(4):1047-52. doi: 10.1097/0000542-199904000-00018. PMID: 10201676.
- [22]. Beaulieu P, Babin D, Hemmerling T. The pharmacodynamics of ropivacaine and bupivacaine in combined Sciatic and FNBs for total knee arthroplasty. *Anesth Analg.* 2006 Sep;103(3):768-74. doi: 10.1213/01.ane.0000229652.70488.32. PMID: 16931694.
- [23]. Singh, Apra; Trivedi, Vandana; Kothari, P.U. SNBin Combination with FNB for Below Knee Surgery via the "Classical" Posterior Approach, *Journal of Anaesthesiology Clinical Pharmacology:* Oct-Dec 2008 - Volume 24 - Issue 4 - p 444-446
- [24]. Vieira PA, Pulai I, Tsao GC, Manikantan P, Keller B, Connelly NR. Dexamethasone with bupivacaine increases duration of analgesia in ultrasound-guided interscalene brachial plexus blockade. *Eur J Anaesthesiol.* 2010 Mar;27(3):285-8. doi: 10.1097/EJA.0b013e3283350c38. PMID: 20009936.
- [25]. Akkaya A, Tekelioglu UY, Demirhan A, et al. Ultrasound-guided Femoral and Sciatic nerve blocks combined with sedoanalgesia versus spinal anaesthesia in total knee arthroplasty. *Korean J Anesthesiol.* 2014;67(2):90-95. doi:10.4097/kjae.2014.67.2.90
- [26]. Kawanishi R, Yamamoto K, Tobetto Y, Nomura K, Kato M, Go R, Tsutsumi YM, Tanaka K, Takeda Y. Perineural but not systemic low-dose dexamethasone prolongs the duration of interscalene block with ropivacaine: a prospective randomized trial. *Local Reg Anesth.* 2014 Apr 5;7:5-9. doi: 10.2147/LRA.S59158. PMID: 24817819; PMID: PMC4012348.
- [27]. Kim YM, Kang C, Joo YB, Yeon KU, Kang DH, Park IY. Usefulness of Ultrasound-Guided Lower Extremity Nerve Blockade in Surgery for Patellar Fracture. *Knee Surg Relat Res.* 2015;27(2):108-116. doi:10.5792/ksrr.2015.27.2.108
- [28]. Vermeulen K, De Puydt J, Engelen S, Roofthoof E, Soetens F, Neyrinck A, Van de Velde M. A double-blind randomized controlled trial comparing dexamethasone and clonidine as adjuvants to a ropivacaine Sciatic popliteal block for foot surgery. *Local Reg Anesth.* 2016 May 5;9:17-24. doi: 10.2147/LRA.S96073. PMID: 27226733; PMID: PMC4863693.
- [29]. Yektaş A, Gümüş F, Alagol A. Dexmedetomidine and propofol infusion on sedation characteristics in patients undergoing SNBin combination with FNB via anterior approach. *Rev Bras Anesthesiol.* 2015;65(5):371-378. doi:10.1016/j.bjan.2014.01.003