



## Omental cyst-A rare but important diagnosis in pain abdomen – case report.

Dr. Divya K R- Post graduate

Dr. Karunanithi R- Professor

Dr. Loganathan- Professor

Dr. Mohamed Zakkariya- Assistant Professor

*Department of general surgery, Chettinad Hospital And Research Institute, Kelambakkam, Chennai.*

Submitted: 20-03-2021

Revised: 31-03-2021

Accepted: 02-04-2021

**ABSTRACT:** Omental cyst are rare intra-abdominal masses in the paediatric population and are even rare in adult population. When large, these lesion can mimic large volume ascites (pseudo-ascites) and may not be immediately recognised. Omental cyst are likely to be congenital and occasionally relate to lymphangiomas that occur elsewhere in the body. The majority of the cyst are solitary and maybe unilocular or multilocular on imaging. This is maybe filled with serous, chylous, haemorrhagic, or infected fluid. This can lead to a delay in appropriate treatment.

The rarity of these lesions, with the incidence of only about 1 in 2,50,000 hospital admissions, and the absence of characteristic clinical findings makes diagnosis difficult. Computed tomography (CT) was the diagnostic method of choice. A single Omental cyst was most common. The most common treatment was simple excision. Other differential diagnosis of Omental cyst include Mesenteric cyst, Neoplastic Lesion (i.e., cystic mesothelioma, cystic spindle cell tumor, cystic teratoma), pancreatic pseudocyst, non-pancreatic pseudocyst, ovarian pseudocyst, enteric cyst, Mesothelial cyst, Lymphangioma.

We present a case of Omental cyst in a 24 years old female with no characteristic clinical findings in favour of omental cyst, with emphasis on imaging findings that can help diagnose this rare, but important entity.

**Keywords:** Lipoma, Omentum, gastrocolic ligament.

### I. INTRODUCTION:

Omental cysts are rare, benign intra-abdominal lesions primarily identified in children under the age of 10 years (68%), although they have been reported in adults. Omental cysts have an incidents of 1 case per 2,50,000 hospital admission(1). These are most commonly serous-filled cysts encased by a fibrous wall, lined by

cuboidal epithelium. They can range in size from a few millimetres to few centimetre in diameter, however, at times maybe so large that it may mimic tubercular ascites(2). Exact aetiology of Omental cyst has yet to be ascertained, but failure of lymph nodes to communicate with the lymphatics or venous systems or blockage of the lymphatics as a result of trauma, infection, and neoplasm are said to be contributing factors.

They most frequently present as chronic abdominal distension. The most common presenting symptoms being abdominal distension (71%), pain(50%), vomiting (50%), and pain and distension (43%)(3). They less frequently present as an abdominal mass with pain, fatigue, or pallor; in these cases, surgical evaluation and cyst resection can be undertaken at the discretion of the patient or family. Omental cyst may rarely present as an acute abdomen requiring surgery in cases of torsion of these cyst or an enlarging cyst that compromises the respiratory or urinary system.

Complications from an enlarging omental cyst may include bleeding, infection, rupture, And torsion. In these cases, emergent complete surgical excision is warranted. Secondary complications associated with omental cyst include volvulus, spillage of infected fluid, herniation of bowel into an abdominal defect, and obstruction.

Because of variable and non-specific clinical symptoms and signs, they are discovered either accidentally during an abdominal radiological examination for other reason or during laparotomy for the management of one of the complications. The aetiology of such cysts remains unknown but several theories regarding their development exist. Complete surgical excision of cyst is the treatment of choice. Due to the rarity of this entity and the lack of specific symptoms, correct pre-operative diagnosis is difficult. Knowledge of these lesions is important due to the various complications associated with suboptimal surgical management.



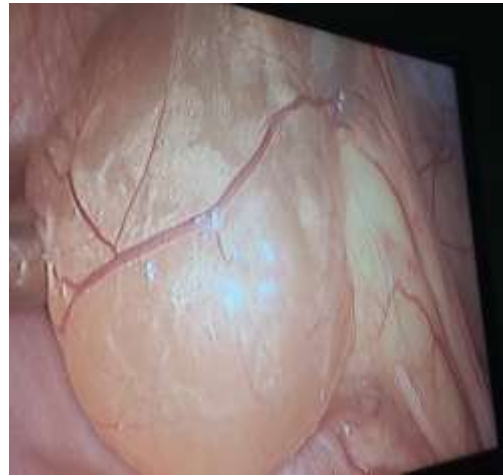
## II. CASE REPORT:

A 24-year old female presented to General Surgery OPD with complaints of dull aching pain in lower abdomen for 1.5 years, which is intermittent in nature, non-radiating, aggravated on food intake, relieved after defecation, and associated with vomiting occasionally when pain is increased, in scanty quantities, containing food particles, non-bilious and non- blood stained.

Patient has no other complaints or illness, and on per abdominal examination, there was mild tenderness over right iliac fossa and infra umbilical region on deep palpation. There are no other findings in favour of abdominal mass or cysts.

All the necessary laboratory investigations were done. Upon Ultrasonography examination, a small of cyst size 4×5 cm was found in right iliac fossa region. Upon further investigation with computed tomogram (CT) of abdomen, an omental cyst of size 8.7×4.3 cms was found in the right iliac fossa region anterior to caecum and ascending colon. There is no evidence of septations/ calcification noted. Normal appendix is made out separately. Bilateral ovarian follicles noted. Possibility of lymphangioma.

Patient was then posted for Diagnostic laparoscopy and proceeded to laparoscopic Omental cyst excision under general anaesthesia and Omental cyst of size 7×10 cms was identified over the right iliac fossa region and white hypochondriac region. The cyst was then dissected from surrounding omental adhesions and was delivered out using an endobag. The specimen was sent for histopathology, in which cyst appear to be multi-loculated, A cystic, gelatinous in consistency, with yellowish serous fluid. This serous fluid is acellular and proteinaceous. This cyst wall appears to be fibro-collagenous. All these features are consistent with Lymphangioma. Post operatively, the patient improved symptomatically over her duration of stay in the hospital and then discharged. Post operative follow-up for three months showed no complaints in correspondence with pain or a recurrence.



## III. DISCUSSION:

Omental cysts are rare, congenital abdominal lesions. Therefore, a complete resection is mandatory because of the high incidence of relapse. Because of variable and non-specific clinical symptoms and signs, they are discovered either accidentally during an abdominal radiological examination for other reason or during laparotomy for the management of one of the complications. The aetiology of such cyst remains unknown but several theories regarding their development exist. Complete surgical excision of the cyst is the treatment of choice. Due to the rarity of this entity and the lack of specific symptoms, correct preoperative diagnosis is difficult. Knowledge of these lesions is important due to various complications associated with suboptimal surgical management. Malignant cysts occur in less than 3% of cases. (4)

Total cyst excision is the therapeutic method of choice. Open method is initially preferred. The advent of laparoscopic surgery has allowed resection of these cysts to be achieved without full laparotomy. Laparoscopic exploration is done using four ports after insufflation with veress needle and excision of the cyst is done using cautery scissors and blunt dissection. Endobags are then used to retrieve the cyst. Laparoscopic excision allows early return of patient to his work.(5, 6)

## REFERENCES

- [1]. Miliaras S, Trygonis S Fau - Papandoniou A, Papandoniou A Fau - Kalamaras S, Kalamaras S Fau - Trygonis C, Trygonis C Fau - Kiskinis D, Kiskinis D. Mesenteric cyst of the descending colon: report of a case. (0001-5458 (Print)).



- [2]. Dulger C, Adali E Fau - Avcu S, Avcu S Fau - Kurdoglu Z, Kurdoglu Z. Large mesenteric cyst mimicking tuberculous ascites. (1687-9635 (Electronic)).
- [3]. Prakash A, Agrawal A, Gupta R, Sanghvi B, Parelkar S. Early management of mesenteric cyst prevents catastrophes: A single centre analysis of 17 cases. *African Journal of Paediatric Surgery*. 2010;7(3):140-3.
- [4]. Kurtz Rj Fau - Heimann TM, Heimann Tm Fau - Holt J, Holt J Fau - Beck AR, Beck AR. Mesenteric and retroperitoneal cysts. (0003-4932 (Print)).
- [5]. Kwan E, Lau H Fau - Yuen W-K, Yuen WK. Laparoscopic resection of a mesenteric cyst. (0016-5107 (Print)).
- [6]. Mason J, Soper N, Brunt LM. Laparoscopic Excision of Mesenteric Cysts. *Surgical Laparoscopy, Endoscopy & Percutaneous Techniques*. 2001;11:382-4.