



Pedunculated Type: An Unusual Clinical Presentation of Lipoma over Thigh

Dr.Pavan Lanjewar^{*}, Dr.Sarojini Jadhav[#], Dr.FaiyyazAli⁺, Dr.VishakhaIyer[^]

^{*}Junior Resident

[#]Professor and Head

⁺Associate Professor

[^]Lecturer

Department of General Surgery,
Government Medical College and hospital,
Aurangabad-431001.
Correspondence- Dr.Pavan Lanjewar

Submitted: 15-07-2022

Accepted: 27-07-2022

ABSTRACT:

Lipomas are one of the commonest soft tissue benign tumours, but few cases of it as pedunculated type over thigh being reported. The present case is 45 year old lady presented with swelling over right upper thigh gradually increased in size over 5 years; with soft, mobile 7 x 5 cm swelling on clinical examination suggestive of pedunculated lipoma. Case managed by complete excision with histopathological examination suggestive of lipoma.

Keywords: Lipoma, Pedunculated, Excision.

I. INTRODUCTION:

Lipomas are the most common benign mesenchymal neoplasms. Most patients affected by lipomas are in their 5th to 6th decade.⁽¹⁾ They consists of mature adipocytes. They tend to grow in the areas of fat cells, most commonly arises in the subcutaneous plane and are freely mobile under the skin. Generally, lipomas are encapsulated by the fibrous capsule. Lipomas occurs due to differentiation of multipotent mesenchymal cells in fat tissue which is triggered by mechanical, endocrine, and inflammatory influence.⁽²⁾ Histopathologically, lipomas consists of mature adipocytes without cellular atypia.⁽³⁾ Lipomas are managed by open surgical excision. Postoperatively, patients should be followed for any recurrence, recurrence rate being 3-62.5%.^(4,5)

II. CASE REPORT:

A 45-year-old lady presented with chief complaints of a swelling over right lower since 5 years. The swelling was initially small peanut shape to begin with but gradually increased over the past 5 years to reach the present size. The swelling was spontaneous in onset and was not preceded by any type of injury or trauma. There

were no associated complaints of weakness, numbness, difficulty in limb movements, loss of sensations or overlying skin colour changes. There was no history of any other swellings over the body. Patient was not having any associated comorbidities. On clinical examination, a pedunculated swelling of size 7x 5cm over right anterolateral aspect of upper thigh was present. No tenderness or local rise in temperature was present. Swelling was mobile in nature and was not fixed to overlying skin or underlying muscle or bone. Ultrasonography of local swelling was suggestive of lipoma. Patient underwent an elective open excisional surgery for the swelling under local anaesthesia. Patient tolerated the procedure well. Histopathology reports were confirmatory for lipoma. Patient was discharged uneventfully (Figures 1-6).

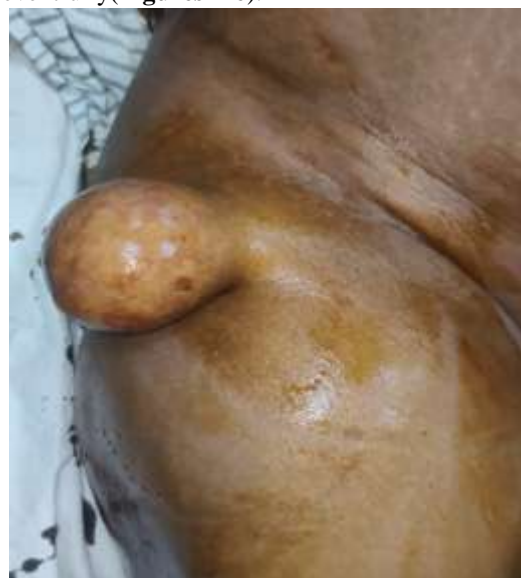

Figure 1: Pedunculated lipoma over anterolateral aspect of right thigh

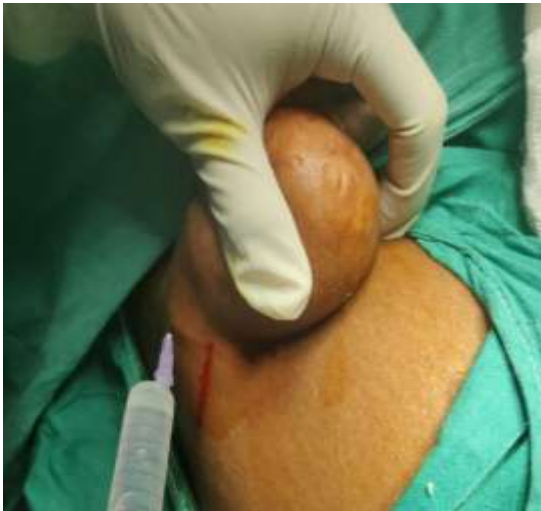

Figure 2: Infiltration of local anaesthesia for operative procedure

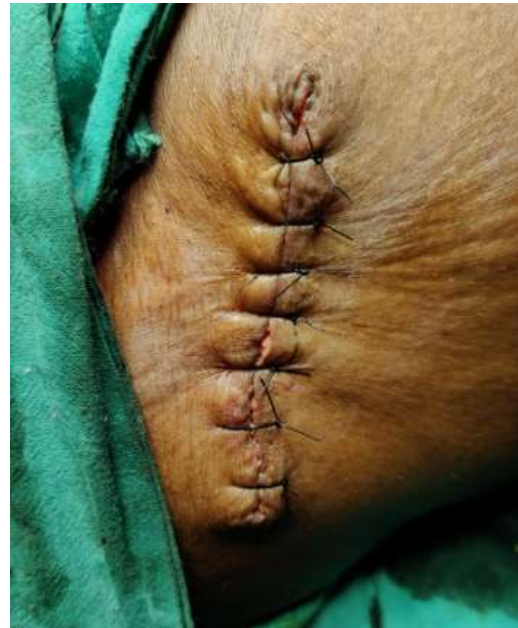

Figure 5: Skin closure after excision of lipoma

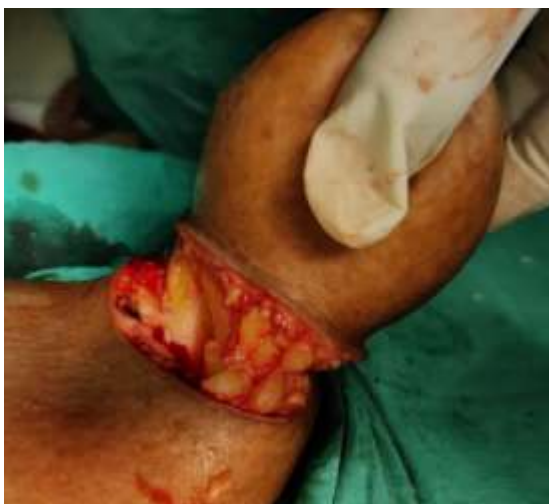

Figure 3: Intraoperative evidence of lipoma

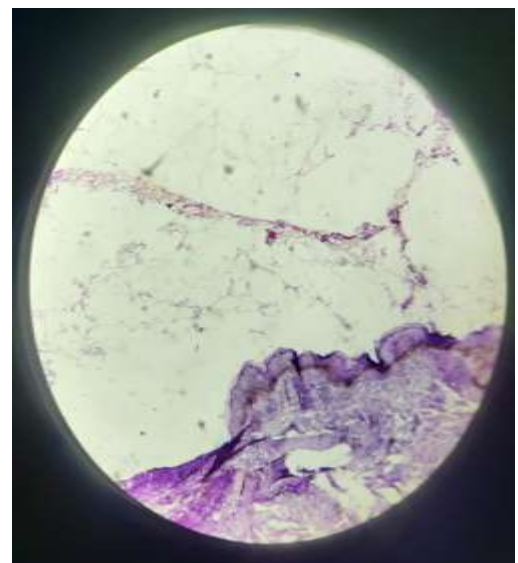


Figure 6: Histopathological evidence of excised specimen of lipoma

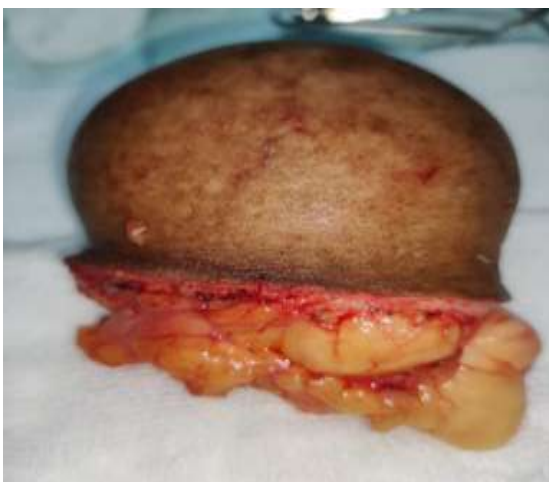

Figure 4: Excised specimen

III. DISCUSSION:

Lipomas are the commonest soft tissue tumours with general population having awareness and knowledge about the condition. But condition being slow in progression and don't generally cause any discomfort, patient does not seek medical advice till the lipomas attains a size which cause cosmetic problems to the patient or getting complicated secondary to trauma or skin ulceration or causing functional problems. Although lipomas being common, only few cases of it as pedunculated type over thigh are being reported.



Pedunculated lipomas also can get complicated by ulceration of overlying skin.⁽¹⁾ Also, pedunculated lipomas at the site of systemic organs like hypopharynx, oesophagus, colon, etc. are being reported.^(6,7,8) Lipomas on long run may undergo malignant transformation into liposarcoma with potential risk of 1% and risk factors being large size, rapid growth rate, calcification in swelling and invasion into surrounding structures.⁽⁹⁾ Definitive management of the condition is complete surgical excision. Recurrences are also reported after excision of lipoma, hence adequate surgical excision is must⁽¹⁰⁾, and post-operative follow up can be considered.

IV. CONCLUSION:

Though lipomas are the most common benign soft-tissue tumours, pedunculated lipoma is a rare entity. Pedunculated lipomas are occasionally complicated by ulceration or can cause functional discomfort to the patient. Surgical excision is the definitive management method for such lesions. Complete excision of the lesion is essential to prevent recurrence.

Conflict of Interest: No competing interests.

Funding: No funding agency.

REFERENCES:

- [1]. Umesh Yadav, Abhishek Garg, Ashish Devgan, Ajay Sheoran, Mayank Dutta, Ayush Gupta, Abhishek Singh, Mudit Nemani . A Rare Case Report of Pedunculated Fibrolipoma in Thigh with Review of Literature. *Mediterranean BioMedical Journals Integrative Journal of Medical Sciences* 2020, Volume 7, ID 257 DOI: 10.15342/ijms.7.257.
- [2]. Adoga AA, Nimkur TL, Manasseh AN, Echejoh GO. Buccal soft tissue lipoma in an adult Nigerian: A case report and literature review. *J Med Case Rep.*2008; 2:382. DOI: 10.1186/1752-1947-2-382.
- [3]. Hakim E, Kolander Y, Meller Y, Moses M, Sagi A: Gigantic lipomas. *Plast Reconstr Surg.*1994; 369- 371. DOI: 10.1097/00006534-199408000-00025 ture review. *J Med Case Rep.*2008; 2:382. DOI: 10.1186/1752-1947-2-382.
- [4]. Bjerregaard P, Hagen K, Daugaard S, et al. Intramuscular lipoma of the lower limb. *J Bone Joint Surg* 1989; 71B(5):812±5. DOI:10.1302/0301-620X.71B5.2584252
- [5]. Dionne GP, Seemayer TA. Infiltrating lipomas and angioliipomas revisited. *Cancer* 1974; 33:732±8. PMID: 4815576. DOI: 10.1002/1097-142(1974)03.
- [6]. Qiang Sun, Chun-Lin Zhang, and Zhao-Hui Liu. An extremely rare pedunculated lipoma of the hypopharynx: A case report. DOI: 10.12998/wjcc. v7.i17.2652.
- [7]. Chih-HsinLiuHuang-ChouChangYih-GangGoan. Large Pedunculated Lipoma of the Esophagus. [https://doi.org/10.1016/S0929-6646\(08\)60109-6](https://doi.org/10.1016/S0929-6646(08)60109-6).
- [8]. Ghanem OM, Slater J, Singh P, Heitmiller RF, DiRocco JD. Pedunculated colonic lipoma prolapsing through the anus. *World J Clin Cases* 2015; 3(5): 457-461 [PMID: 25984520 DOI: 10.12998/wjcc.v3.i5.457].
- [9]. Milgram JW. Malignant transformation in bone lipomas. *Skeletal Radiol.*1990; 19 (5): 347–52. DOI: 10.1007/BF00193088.
- [10]. Jessica Rauh1 , Alexander Klein , Andrea Baur-Melnyk, Thomas Knösel, Lars Lindner, Falk Roeder, Volkmar Jansson and Hans Roland Dürr . The role of surgical margins in atypical Lipomatous Tumours of the extremities. Rauh et al. *BMC Musculoskeletal Disorders* (2018) 19:152 <https://doi.org/10.1186/s12891-018-2053-3>.