



## Primary papillary carcinoma in thyroglossal duct cyst: A case report

Dr. Madhu Dethariya<sup>1</sup>, Dr. Prakash Pampaniya<sup>2</sup>, Dr. Vali Karmur<sup>3</sup>, Dr. Shamim Sheikh<sup>4</sup>, Dr. Dhairy Boghani<sup>5</sup>

(1: Senior resident, Shree M. P. Shah government medical college, Jamnagar;

2 Senior resident, Shree M. P. Shah government medical college, Jamnagar;

3. Tutor, Shree M. P. Shah government medical college, Jamnagar,

4. Associate Professor, department of pathology; Shree M. P. Shah government medical college, Jamnagar,

5: Junior resident, Shree M. P. Shah government medical college, Jamnagar)

Submitted: 25-03-2022

Accepted: 04-04-2022

**ABSTRACT:** Most common anomaly in thyroid gland is thyroglossal duct cyst. Occurrence of malignancy in a thyroglossal duct cyst is considered a rare condition, forming 1% of all cases of thyroglossal duct cyst. Here, in the current report we presented a rare case of primary papillary carcinoma which arise in a thyroglossal duct cyst. Fine needle aspiration cytology followed by anterior neck swelling excision under general anaesthesia. Our case is a 25-year female patient, presented with a painless multiple cystic mass in anterior neck. After initial physical examination, we have performed fine needle aspiration cytology of the cyst which revealed benign cystic lesion? Thyroglossal duct cyst. The patient underwent surgical excision of thyroglossal duct cyst and excision of the cervical lymph node. Histopathology of the specimen revealed a thyroglossal duct cyst which contains a primary invasive papillary carcinoma that infiltrate the cyst wall. All cervical lymph nodes are free from malignancy. Primary papillary carcinoma of thyroglossal duct cyst is a rare condition that should be considered in patients with cystic anterior neck masses. Surgical excision is the optimal patient management to improve survival.

**KEY WORDS:** Papillary carcinoma; Thyroglossal duct cyst

### I. INTRODUCTION:

Most common anomaly in thyroid gland is thyroglossal duct cyst. Occurrence of malignancy in a thyroglossal duct cyst is considered a rare

condition, forming 1% of all cases of thyroglossal duct cyst [2]. Here, in the current report we presented a rare case of primary papillary carcinoma which arise in a thyroglossal duct cyst.

### II. CASE REPORT:

A 25-year-old female patient, presented with a painless recurrent multiple cystic mass in anterior neck since 2 months.

On physical examination, ill-defined multiple cystic swellings were present in anterior neck with normal overlying skin, largest of size 3x3 cm.

Ultrasonography of neck was showing three well defined hypoechoic cystic lesions noted in midline of neck along with conglomerated necrotic lymphnode in left level Ib. Both lobes and isthmus of thyroid gland were appeared to be normal in size, shape and echotexture. CT scan report was suggestive of solid cystic mass lesion with internal areas of calcification and associated cervical lymphadenopathy.

After initial physical examination, fine needle aspiration was performed which revealed benign cystic lesion. The patient underwent surgical excision of the lesion with excision of the cervical lymph node. Histopathology of the specimen revealed a thyroglossal duct cyst with primary invasive papillary carcinoma infiltrating the cyst wall.

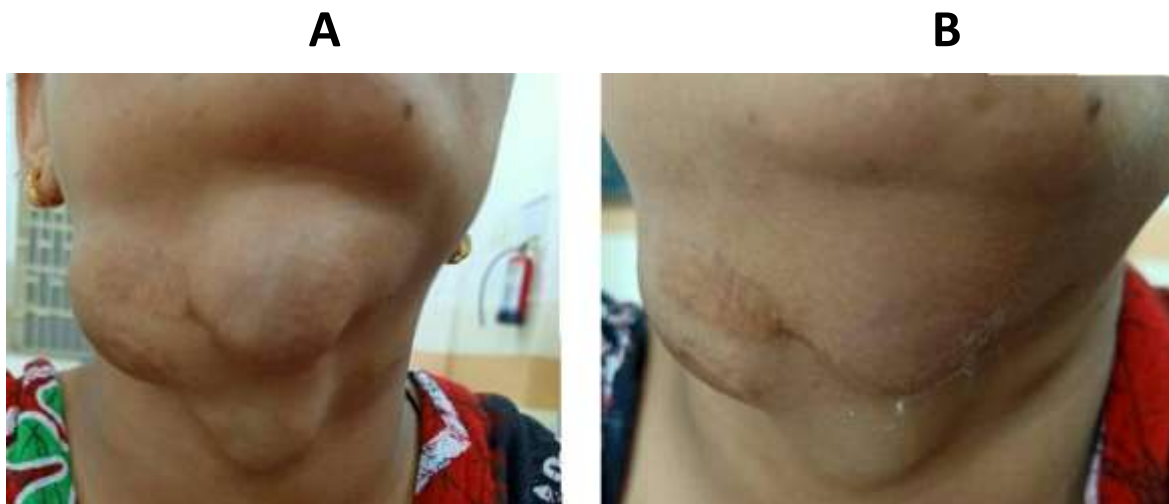

Figure- 1: Image A is showing multiple cystic neck swellings.  
Image B shows reduction in size of the swellings after fineneedle aspiration.

### III. GROSS DESCRIPTION:

We received multiple tissue structures for histopathological examination containing 8x5x2 cm sized globular cystic mass with greyish brown in colour and 2x2x1 cm sized solid structure with firm

consistency and greyish in colour. On cut section brownish coloured fluid came out. Appropriate sections from representative areas were taken for microscopic examination.

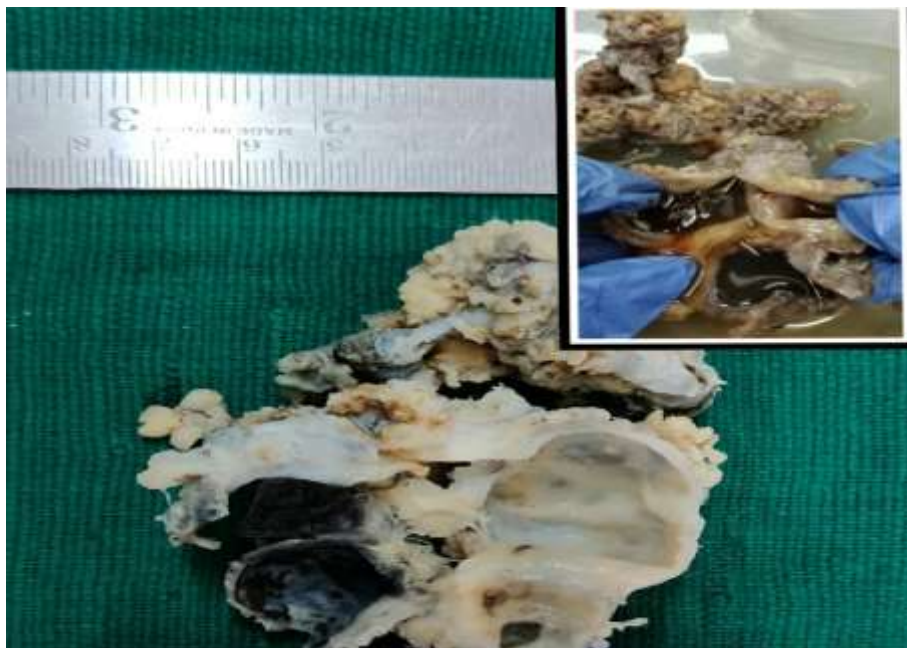

Figure- 2: Excised globular cystic neck mass showing papillary projections and brownish fluid filled cavity.

### IV. MICROSCOPIC EXAMINATION:

H &E-stained sections from cystic mass revealed branching true papillae with fibrovascular core having complex architecture with thyroid follicles in between. Lining cuboidal cells of papillae are arranged in single or occasional multiple layers with round to oval nuclei. These

cells are showing nuclear crowding, overlapping, optically clear chromatin (Orphan-Annie nuclei) with nuclear groove (represents infolding nuclear membrane) [1]. Surrounding areas show fibrosis, mitotic figures and calcification.



Sections from excised solid mass showed infiltration of papillary carcinoma in lymphnode

that was seen in thyroglossal duct cyst.

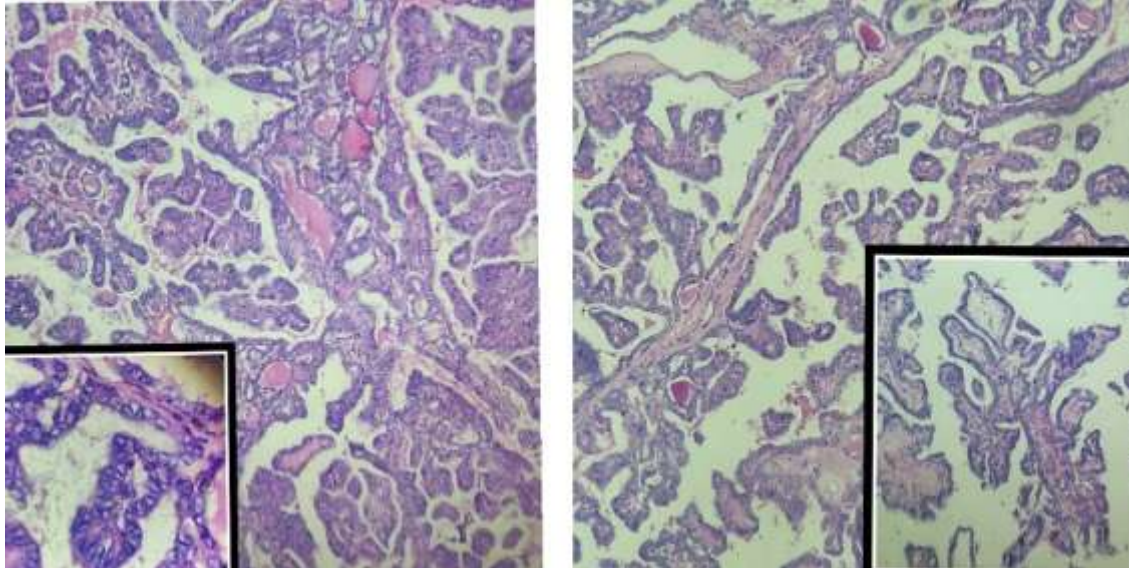


Figure- 3: H&E-stained section shows complex papillary architecture with nuclear features of PTC.

#### DIAGNOSIS:

Classical papillary thyroid carcinoma in thyroglossal duct cyst.

#### V. SUMMARY:

Primary papillary carcinoma of thyroglossal duct cyst is a rare condition that should be considered in patients with cystic anterior neck masses. Surgical excision is the optimal patient management to improve survival.

#### REFERENCES:

- [1]. Rosai and Ackerman's surgical pathology; eleventh edition; vol.1; pg:280-281.
- [2]. Loay M. Gertallah, Eman Eltokhy, Taha A. Baiomy; Invasive primary papillary carcinoma in a thyroglossal duct cyst: A case report and review of the literature; www.Elsevier.com; human pathology: case reports; 2018.