



Rapid Maxillary Expansion ---A Review

Manash Jyoti Borah, Deeksha Bhanotia, Ananthu S Kumar

Consultant Orthodontist and Dentofacial Orthopaedician, Oral & Dental Surgeon

MDS Orthodontics and Dentofacial Orthopaedics, Post Graduate Resident

MDS Orthodontics and Dentofacial Orthopaedics, Post Graduate Resident

NIMS Dental College and Hospital, Jaipur, Rajasthan

Corresponding Author: Manash Jyoti Borah

Consultant Orthodontist, Oral & Dental Surgeon

Submitted: 10-07-2022

Accepted: 23-07-2022

ABSTRACT: Rapid maxillary expansion also sometimes known as the Rapid Palatal Expansion is an orthopaedic expansion of maxillary arch by opening the mid palatal suture with the help of the orthodontic appliances. This procedure is commonly undertaken in the mixed dentition period when the palatal sutures remains unfused. It is a non extraction method of space gaining to alleviate crowding and space deficiency in upper arch as well as correct any transverse discrepancy. This review article is undertaken to highlight various modalities of the rapid maxillary expansion, its effect on craniofacial complex and management of certain craniofacial deformities with Rapid Maxillary Expansion.

KEY WORDS: Rapid maxillary expansion, Rapid palatal expansion, sutures, Expansion Appliances, Surgically Assisted Rapid Maxillary Expansion (SARME), Mini implant supported Rapid Maxillary Expansion (MARPE), Rapid Maxillary Expansion of Cleft Lip and Palate.

INTRODUCTION

Rapid maxillary expansion (RME) is a dramatic procedure with a long history. E. H. Angell' reported on the procedure in 1860, and since then it has gone through periods of popularity and decline. In the late 1940s, Graber' advocated RME for the treatment of cleft lip and palate patients. Since then clinicians have increasingly included RME in the treatment of their patients. Although clinicians agree about many of the indications for and outcomes of RME, a review of the literatures indicates that numerous disagreements persist about the procedure. Haas, Isaacson and Murphy, and Wetz advocated splitting

of the midpalatal suture to widen narrow maxillary arches. On the other hand, Graber believed that the technique was originally dropped because of development of open bites, relapse, and the fact that improvement of nasal breathing was only temporary. Furthermore, orthodontic appliances routinely achieve the needed maxillary intercanine and intermolar expansions.[1]

Anatomy

- The tenacity of circummaxillary attachments due to buttressing is strong postero-superomedially and postero supero laterally.
- A palatine bone forms an intimate relationship with maxilla to form complete hard palate (or) floor of nose and greater part of lateral wall of nasal cavity.
- It articulates anteriorly with maxilla through transverse palatal sutures and posteriorly through pterygoid process of the sphenoid bone.
- The interpalatine suture joins the two palatine bones at their horizontal plates and continuous as inter maxillary sutures.
- These sutures forms the junction of three opposing pairs of bones: the premaxillae, maxilla, and the palatine. The entire forms mid-palatal suture.

SUTURES:

Mid Palatine Suture plays a key role in R.M.E

- i. Infancy - Y-shape
- ii. Juvenile - T-shape
- iii. Adolescence - Jigsaw puzzle²

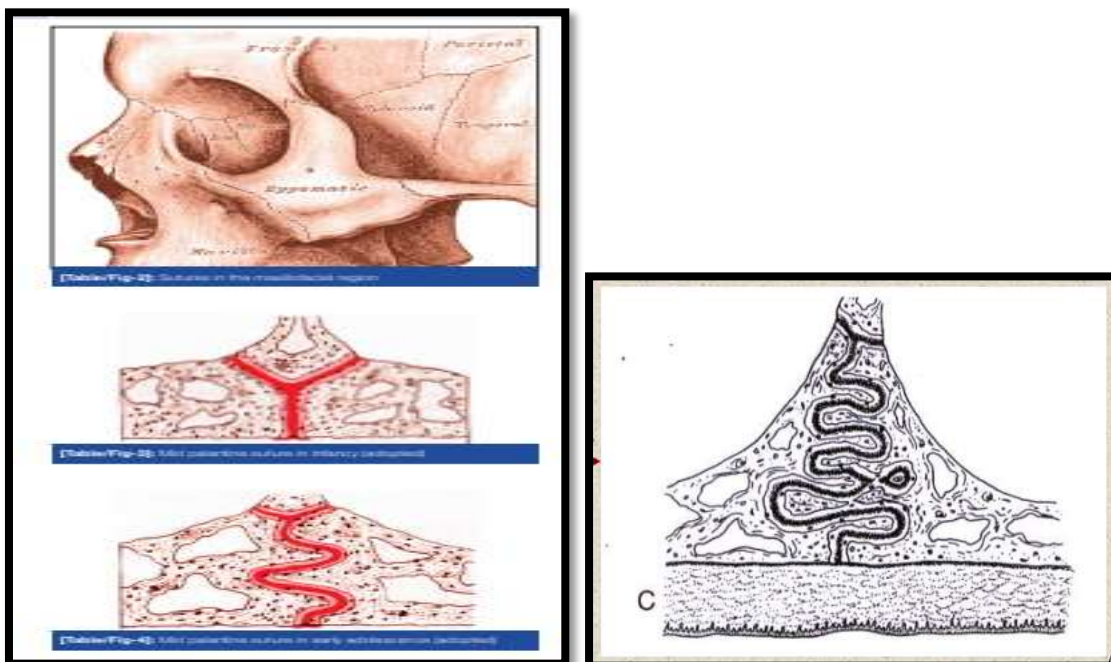
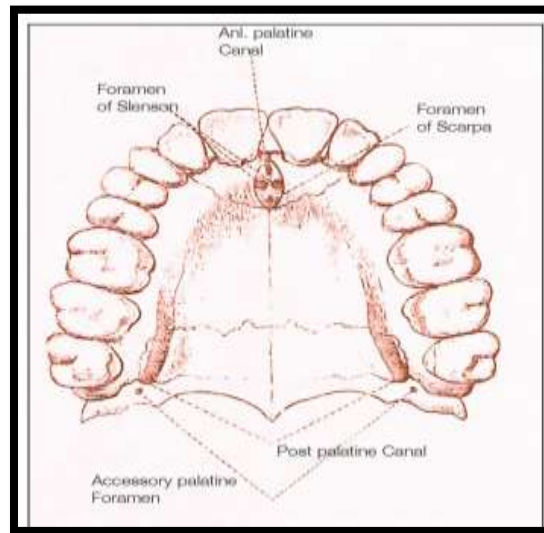


Figure 1: Various Sutures in various stages of life

Indications for RME.

- Patients who have lateral discrepancies that result in either unilateral or bilateral posterior crossbite involving several teeth are candidates for RME.
- The constriction may be skeletal (narrow maxillary base or wide mandible), dental, or a combination of both skeletal and dental constriction.
- Anteroposterior discrepancies are cited as reasons to consider RME.
- Cleft lip and palate patients with collapsed maxillae are also RME candidates.

Contradictions for RME

- Patients who cannot cooperate with the clinician are not candidates for RME.
- Patients who have a single tooth in crossbite probably do not need RME.
- Patients who have anterior open bites, steep mandibular planes, and convex profiles are generally not well suited to RME.
- Patients who have skeletal asymmetry of the maxilla or mandible, and adults with severe anteroposterior and vertical skeletal discrepancies are not good candidates for RME.[2]



Factors need to be considered during treatment planning to determine whether to expand the dental arches conventionally or with RME:

- The magnitude of the discrepancy between the maxillary and mandibular first molar and premolar widths; if the discrepancy is 4 mm or more, one should consider RME.
- the severity of the crossbite, that is, the number of teeth involved,
- the initial angulation of the molars and premolars-when the maxillary molars are buccally inclined, conventional expansion will tip them further into the buccal musculature; and if the mandibular molars are lingually inclined, the buccal movement to upright them will increase the need to widen the upper arch.

ETIOLOGY

- Buccolingual discrepancies could be either genetic or environmental.
- Graber, Harvold, Cheirici, stated that many constricted maxillary dental arches are the result of abnormal function.
- Harvold in his experimental work created narrow maxillary dental arches in rhesus monkeys by converting them from nasal to obligatory oral respiration.
- All patients considered for RME should be examined for nasal obstruction and, if obstruction is found, they should be referred to an otolaryngologist before orthodontic treatment for examination and treatment of the problem.

DIAGNOSIS:

- The following measurements will help clinicians estimate how much expansion is needed:
Measure the distance between the most gingival extension of the buccal grooves on the mandibular first molars or, when the grooves have no distinct terminus on the buccal surface, between points on the grooves located at the middle of the buccal surfaces.
- measure the distance between the tips of the mesiobuccal cusps of the maxillary first molars
- subtract the mandibular measurement from the maxillary measurement.
- The average differences in persons with normal occlusion are +1.6 mm for males and +1.2 mm for females
- The discrepancy between the maxillary and mandibular measurements is a good estimate of how far the maxillary molars must be expanded.

- One should overexpand the molars 2 to 4 mm beyond the required distance to allow for the expected postfixation relapse.

The expansion screw should provide, at least, this calculated amount of expansion

- These estimates assume a Class I molar relationship. If the malocclusion will be corrected to a Class II or III molar relationship, the corresponding arch segments should be measured when estimating the amount of expansion necessary.
- In treating Class II patients, unless a buccal overjet is present, correction of the anteroposterior discrepancy without maxillary arch expansion will result in various degrees of buccolingual malrelationships of the posterior segments.
- To avoid such an occurrence, it is necessary to expand the maxillary arch either conventionally or with RME
- Similarly, in Class III patients one has to differentiate between a crossbite created by the anteroposterior discrepancy and the crossbite that is present even after the correction of the molar relationship.

Rapid Maxillary Expansion

Expansion of the upper jaw is termed 'rapid' when expansion appliance is activated at a rate of 0.5–1 mm/day which is made possible by either two quarter turns of the screw/day or two quarter turns twice in a day.

- Rapid maxillary expansion (RME) results in rapid correction of the cross-bite occurring in 2–6 weeks.
- A midline diastema may appear which is suggestive of the mid-palatal split.
- This diastema would close spontaneously due to the recoil of the stretched trans-septal group of gingival fibres.
- Slight over expansion of the maxilla whereby lingual slopes of maxillary lingual cusps touch mandibular buccal cusps is a desired clinical practice.
- This over-expansion makes allowance for the relapse particularly of the buccal tipping of the molars.
- Following the completion of the expansion, the appliance is left passive to serve as a retainer for another 6 months
- After the treatment of RME, the mid-palatal suture seems to undergo recalcification, so the expansion of the mid-palatal suture is stable.
- The osteogenic reaction in the expanded mid-palatal suture and orthodontically induced osteogenesis in the PDL of adjacent incisors show different reactions.



- The widened PDL resulted in direct osteogenic induction of new bone, whereas the adjacent expanded suture experienced haemorrhage, necrosis and a wound healing response. Vascular invasion of the blood clot in the expanded suture is a prerequisite for new bone formation. [3]

CLINICAL MANAGEMENT OF RME

- The patient/parent should be informed in advance about the upper midline diastema during the expansion phase. This is likely to close spontaneously during the retention period. Patients should be instructed to turn the expansion screw one-quarter turn twice a day (am and pm). This may be associated with minor discomfort. Force levels tend to accumulate following multiple turns and can be as high as 10 kg following many turns. Patients should be reviewed weekly and some clinicians recommend that an upper occlusal radiograph be taken one week into treatment to ensure that the midpalatal suture has separated. If there is no evidence of this, it is important to stop appliance activation as there is a risk of alveolar fracture and/or periodontal damage. Active treatment is usually required for a period of 2-3 weeks, after which a retention period of three months is recommended to allow for bony infilling of the separated suture. [4]

Types of appliances used:

- Removable appliances
- Fixed appliances

tooth borne

tooth and tissue borne

Tooth and tissue borne appliances

include:

1. Derichsweiler type

2. Haas type

Tooth borne appliances include:

1. Isaacson type

2. Hyrax type

Expansion screws

Hyrax expansion screw:

- For mid palatal suture separation by means of fixed appliance without the need for acrylic plate.
- Metal frame work used in combination with performed band which are soldered to the retention arm.

JACKSCREW TURN SCHEDULES

- Zimmring and Isaacson (1965) recommend the following turn schedules:
- Young growing patients two turns each day for the first 4 to 5 days, one turn each day for the remainder of RME treatment:
- Adult (non growing) patient – because of increased skeletal resistance, two turns each day for the first 2 days, one turn each day for the next 5 to 7 days, and one turn every other day for the remainder of RME treatment
- Timms
- 1. **Up to 15 yrs:** 90° rotation once in the morning & once in the evening.
- 2. **15-20 yrs :** 45° activation 4 times a day.

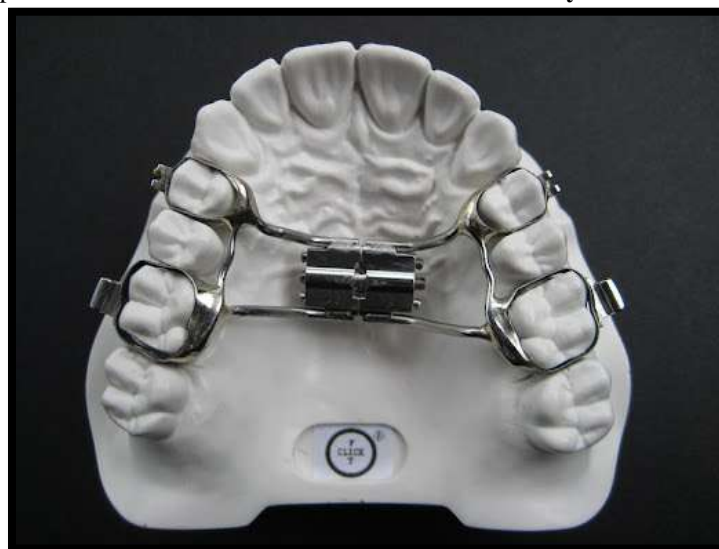

Fig 2 : Hyrax Appliance

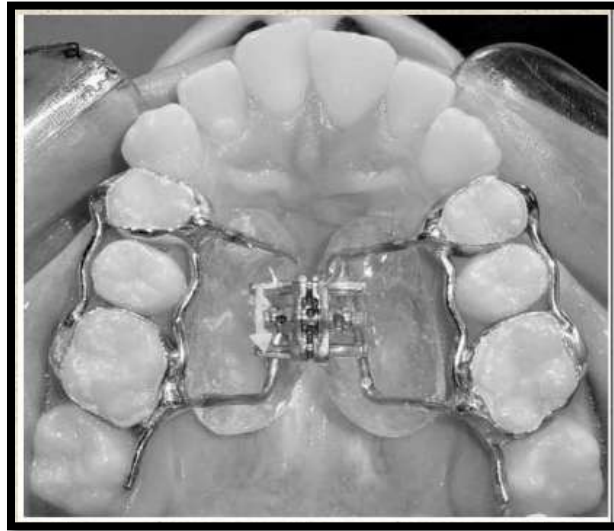


Fig 3 : Hass Appliance

Hyrax Appliance

- The more commonly used type of banded RME appliance is the hyrax type expander.
- It is entirely made from stainless steel.
- Bands are placed on the maxillary first molars and first premolars.
- The expansion screw is located in the palate in close proximity to the palate contour.
- Buccal and lingual support wires also may be added for rigidity.
- The maxilla opens as if on a hinge, with its apex at the bridge of the nose.
- The suture also opens on a hinge anterioposteriorly, seperating more anteriorly than posteriorly.
- The design of the cemented HYRAX appliance is extremely critical:

the acrylic component of the plate should cover the crowns of the teeth, leaving only 1 mm of clearance at the gingival margins along the buccal and palatal aspects.

This ensures a maximum surface area for retention and sufficient clearance at the gingival margins to allow maintenance of good oral hygiene.

- The acrylic extensions should have a chamfer finish to minimise food retention.
- Acrylic occlusal coverage does not need to be more than 1–2 mm in thickness and holes should be drilled into it to allow excessive cement to escape.
- With the introduction of contemporary glass ionomer cement, the retention of cemented expanders has improved significantly, and there is no longer need to use composite or acrylic-based materials that require acid-etching procedures.

Hass appliance

The first type of expansion screw popularized by Haas in 1961. [5]

It consists of bands placed on maxillary 1st premolars and molars.

A midline jackscrew is incorporated into the acrylic pads that closely contact the palatal mucosa.

0.045inch SS wire soldered to palatal aspect of the appliance.

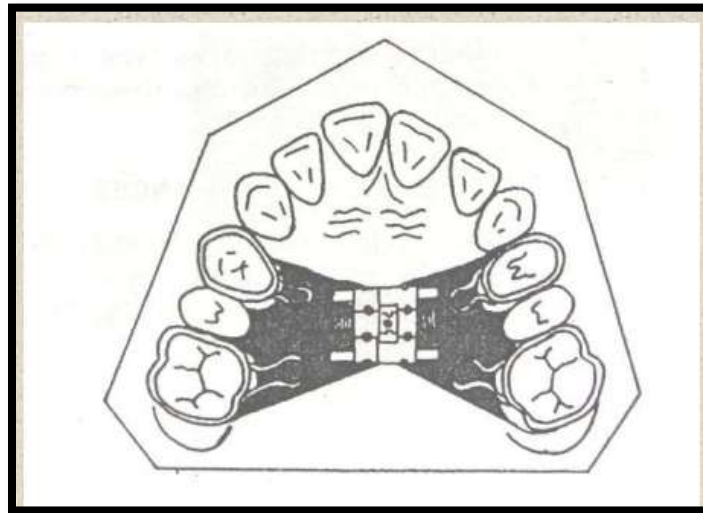


Fig 4: Derischweiler appliance




Fig 5: Issacson Appliance

- Support wire extend along the buccal and lingual surfaces of the posterior teeth, to add rigidity to the appliance.
- Haas in 1961 stated that more bodily movement and less dental tipping is produced when acrylic palatal coverage is added to support the appliance, thus pertaining forces to be generated not only against the teeth but also against the underlying tissue.

Derischweiler appliance (1953)

- Tags are welded & soldered to palatal aspect of bands to provide attachment for acrylic which is extended to palatal aspect of non-bonded teeth.

Issacson Appliance: (1971)

- This is a tooth borne appliance with out any acrylic palatal covering

- Mini expander (developed by university of minnesota ,dental school) soldered directly to the bands.
- Screw reduced in length for narrow arches.

NiTi expander

- Wendell V. Arndt introduced NiTi expander to orthodontic profession.
- Its central component is fabricated from a thermally activated NiTi alloy and rest of the appliance, including lateral palatal arms are made of stainless steel.
- The action of the NiTi is made possible by harnessing nitanium's properties of shape memory and transition temperature
- Nickel-titanium expanders do not require activation once fitted into the lingual tubes.
- The activated appliance produces effective derotation of the unfavourable rotated molars and simultaneous expansion .



- The nickel titanium expander has a transition temperature of 94 °F.
- When it is chilled before insertion, it becomes flexible and can easily be bent to facilitate placement.
- As the mouth begins to warm the appliance, the metal stiffens, the shape memory is restored, and the expander begins to exert a light, continuous force on the teeth and the mid-palatal suture.
- A 3 mm increment of expansion exerts only about 360 g of force. [6]

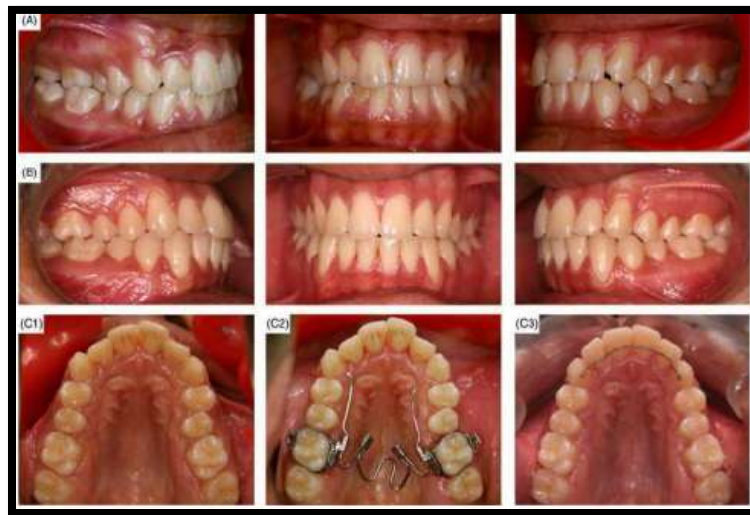

Fig 6 : NiTi Expander

SURGICALLY ASSISTED RAPID MAXILLARY EXPANSION

- Procedures to correct a maxillary transverse deficiency in adult individuals have conventionally been grouped into two categories;
- segmenting the maxilla during a Le Fort 1 osteotomy to reposition the individual segments in a widened transverse dimension and surgically assisted rapid maxillary expansion (SARME).

Indication for surgically assisted rapid maxillary expansion (SARME)

- To increase the maxillary arch perimeter and to correct posterior cross-bite.
- To widen the maxillary arch as a preliminary procedure, even if further orthognathic surgery is planned.
- To provide space for a crowded maxillary dentition when extractions are not indicated.
- To widen hypoplastic maxilla associated with clefts of the palate.

- To reduce wide black buccal corridors when smiling.
- Alternate to failed orthopaedic maxillary expansion.
- Adult OSA patients with narrow maxillae and deep palatal vault.
- Hyrax appliance, either implant supported, banded or bonded is the recommended expansion device to be used with SARME.
- Some boneborne distractors are now available commercially. The force is generated by a jackscrew in all these appliances.
- The Hyrax has a metal frame-work that is less irritating to the palatal mucosa and is more hygienic.
- Expansive growth occurs in the direction of the force applied, and the change is volumetric.
- The tooth-borne appliance should be placed preoperatively, and the appliance key must be in the operating room to allow intra-operative activation.

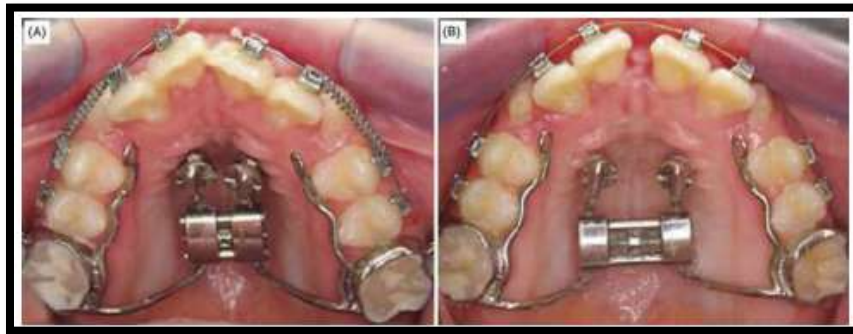


Fig 7: Mini-implant attached rapid palatal expansion

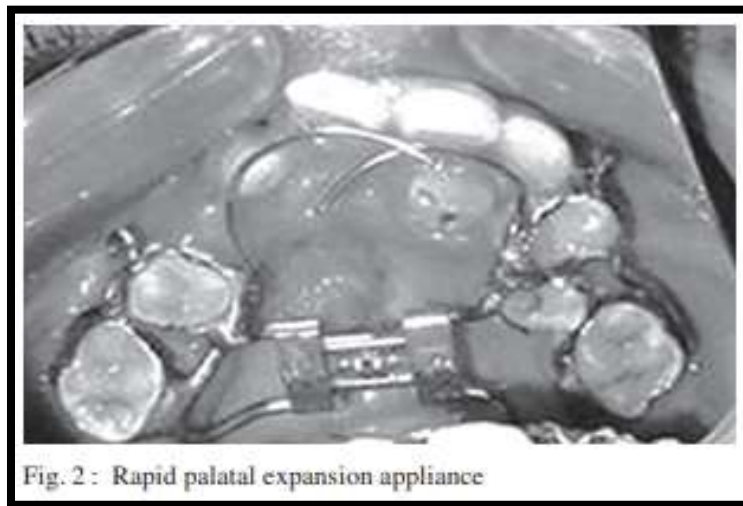


Fig. 2 : Rapid palatal expansion appliance

Fig 8 : Expansion in cleft

Mechanism of SARME:

- An 'artificial suture' is created by performing a LeFort 1 osteotomy with mid-palatal osteotomy.
- A hematoma forms around the fracture sites due to vascular disruption.
- Once the clot has formed, a reorganisation process takes place as a result of invading capillaries.
- By the fifth to seventh day after the osteotomy, inflammatory granulation tissue of the initial soft callus is converted into an organised fibrous connective zone, when the traction can be started.
- The expansion schedule should be tailored, depending on the symmetry of the bony fracture and the health of the gingival attachments.
- The activation varies between 0.25 and 1 mm per day.
- SARME is a predictable technique when followed with surgical protocol and guidelines on expansion.

- Once traction stops, ossification and concomitant remodelling occur, leaving a stable increase of bone in the transverse dimension.

MINI IMPLANT SUPPORTED RAPID MAXILLARY EXPANSION

- Mini-implant supported expander appliance is both tooth and bone born; it can be designated a hybrid hyrax.

The skeletal anchored expansion appliance is capable of splitting mid palatal suture in adults and therefore this procedure has become popular with increasing demand for orthodontics in adult patients.⁶

RAPID MAXILLARY EXPANSION OF CLEFT LIP AND PALATE

- Orthodontic treatment plays an important part in the overall rehabilitation of the child with cleft palate. For maxillary expansion in cleft lip and palate (CLP), children orthodontic's use both rapid and slow palatal expansion.



- Maxillary transverse deficiency can either be treated by RPE or SPE.
- High magnitude forces used in RPE maximize skeletal separation of midpalatal suture by overwhelming the suture before any dental movement or physiological sutural adjustment can occur.
- Hence, advocates of rapid maxillary expansion believe that it results in minimum dental movement (tipping) and maximum skeletal movement.
- The disadvantage of using rapid palatal expanders include discomfort due to traumatic separation of the midpalatal suture, inability to correct rotated molars, requirement of patient or parent cooperation in activation of the appliance, bite opening, relapse, micro trauma of the temporomandibular joint, root resorption, tissue impingement, pain and laborintensive procedure in fabrication of the appliance. [7]

EFFECT OF R.M.E. ON THE MAXILLARY AND MANDIBULAR COMPLEX

- Rapid maxillary expansion occurs when the force applied to the teeth and the maxillary alveolar processes exceeds the limits needed for orthodontic tooth movement.
- The applied pressure acts as an orthopedic force that opens the midpalatal suture.
- The appliance compresses the periodontal ligament, bends the alveolar processes, tips the anchor teeth, and gradually opens the midpalatal suture.

Viewed occlusally

- Inoue found that the palatine processes of the maxillae separated nonparallel— that is, in a wedge-shaped manner. (75% to 80% of the cases observed.)

Viewed frontally:

- Wertz's study of three dry skulls, one adult and two in the mixed dentition, also indicated that the shape of the anteroposterior palatal separation was nonparallel in all three skulls.
- The maxillary suture was found to separate supero inferiorly in a nonparallel manner. It is pyramidal in shape with the base of the pyramid located at the oral side of the bone.
- The magnitude of the opening varies greatly in different individuals and at different parts of the suture. In general, the opening is smaller in adult patients. The actual measurement ranges from practically no separation to 10 mm or more.
- Maxillary anterior teeth. From the patient's point of view, one of the most spectacular changes accompanying RME is the opening of a diastema between the maxillary central incisors

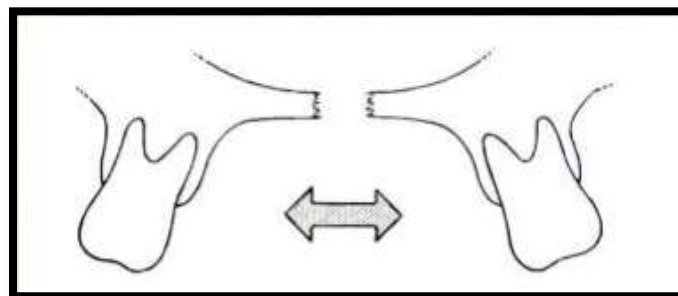


Fig 9 : Correction Of Posterior tooth inclination

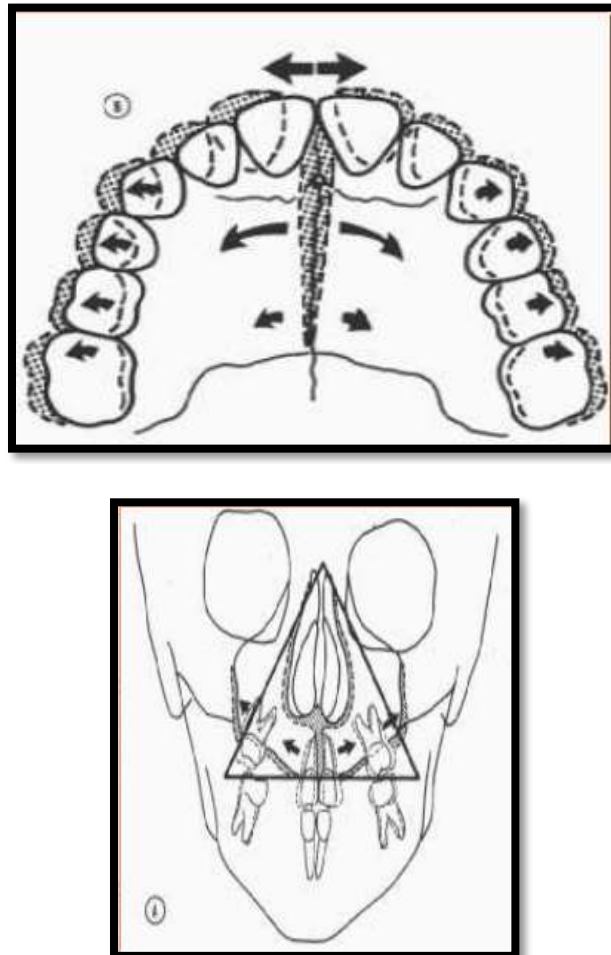


Fig 10 : Various effects of RME on Maxillofacial complex

Relation between amount of sutural separation and extent of molar expansion.

- Krebs studied maxillary expansion with metallic implants. He placed implants in the alveolar process lingual to the upper canines and along the infrazygomatic ridge, buccal to the upper first molars.
- He found that the mean increase in intermolar distance measured on casts was 6 mm, while the mean increase in infrazygomatic ridge implants was 3.7 mm.
- In 20 of 23 patients examined, the amount of sutural opening was equal to or less than one half the amount of dental arch expansion.
- He also found that the sutural opening was on average more than twice as large between the incisors than it was between the molars.

Changes during fixation and retention.

- Kerbs noted that although dental arch width was maintained during fixed retention, the distance between implants in the

infrazygomatic ridges decreased during the 3 months of fixed retention by an average of 10% to 15%.

- This relapse continued during retention with removable appliances. After an average period of 15 months, approximately 70% of the infrazygomatic maxillary width increase was maintained.
- **Maxillary halves.**
- Krebs showed that the two halves of the maxilla rotated in both the sagittal and frontal planes. Haas and Wertz found the maxilla to be more frequently displaced downward and forward.
- The final position of the maxilla, after completion of expansion, is unpredictable and it has been reported to return, partially or completely, to its original position.
- **Palatal vault.**
- Fried and Haas reported that the palatine processes of the maxilla were lowered as a



result of the outward tilting of the maxillary halves.

- On the other hand, Davis and Kronmani' reported that the palatal dome remained at its original height.

Alveolar processes.

- Because bone is resilient, lateral bending of the alveolar processes occurs early during RME.
- Most of the applied forces tend to dissipate within 5 to 6 weeks. After stabilization is terminated, any residual forces in the displaced tissues will act on the alveolar processes causing them to rebound.

Maxillary anterior teeth.

- From the patient's point of view, one of the most spectacular changes accompanying RME is the opening of a diastema between the maxillary central incisors.
- One can understand how the opening of such a space would patient and parents. It is estimated that during active suture opening, the incisors separate approximately half the distance the expansion screw has been opened," but the amount of separation between the central incisors should not be used as an indication of the amount of suture separation.

Maxillary posterior teeth.

- With the initial alveolar bending and compression of the periodontal ligament, there is a definite change in the long axis of the posterior teeth.
- Hicks found that the angulation between the right and left molars increased from 1 degree to 24 degree during expansion.
- Not all of the change, however, is caused by alveolar bending, but is partly due to tipping of the teeth in the alveolar bone. This tipping is usually accompanied by some extrusion.

Palatal mucoperiosteum, periodontal tissues, and root resorption.

- As the maxillae separate, the palatal mucoperiosteum is stretched. Cotton suggested that the postexpansion angular changes of the maxillary first molars may be related to the stretched fibers of the attached palatal mucosa.
- He found that all maxillary molars in his animal study demonstrated an average 10 degree decrease in angulation after active expansion and this decrease occurred regardless of whether an actual increase in molar angulation had occurred during the treatment period.
- Maguerza and Shapiro attempted to relieve the stretch of the mucoperiosteum after "slow" expansion by making incisions along the palate

down to the cortical bone, 3 mm away from the teeth.

- The incisions did not effectively reduce the relapse tendency. Whether such incisions might be effective with RME expansion or whether the incision wound itself causes contraction is yet to be determined.

Effects of RME on the mandible.

- It is generally agreed that with RME there is a concomitant tendency for the mandible to swing downward and backward.
- There is some disagreement regarding the magnitude and the permanency of the change.
- The fairly consistent opening of the mandibular plane during RME is probably explained by the disruption of occlusion caused by extrusion and tipping of maxillary posterior teeth along with alveolar bending.
- RME should be cautiously performed on persons with steep mandibular planes and/or open bite tendencies.
- Effects of RME on the mandibular teeth. Following RME, the mandibular teeth have been observed to upright or to remain relatively stable over the short period of treatment.
- Gryson recorded changes in maxillary and mandibular intercanine and intermolar widths before and after expansion in 38 patients.
- The ages of the groups ranged between 6 and 13 years. The mean increase in the mandibular intermolar width was 0.4 mm; most patients either had no change or showed an increase of up to 1 mm.

Effects of RME on adjacent facial structures.

An examination of occlusal films showed that the opening of the midpalatal suture extends through the horizontal plates of the palatine bones, but the distance between the two expanded halves is very narrow.

- Kudlick in a study on a human dry skull that simulated in vivo response of RME, concluded the following:

(1) all craniofacial bones directly articulating with the maxilla were displaced except the sphenoid bone,

(2) the cranial base angle remained constant,

(3) displacement of the maxillary halves was asymmetric, and

(4) the sphenoid bone, not the zygomatic arch: was the main buttress against maxillary expansion.

RME and nasal airflow.



- Anatomically, there is an increase in the width of the nasal cavity immediately following expansion, particularly at the floor of the nose adjacent to the midpalatal suture.
- As the maxillae separate, the outer walls of the nasal cavity move laterally.
- The total effect is an increase in the intranasal capacity.
- The nasal cavity width gain averages 1.9 mm, but can widen as much as 8 to 10 mm at the level of the inferior turbinates, while the more superior areas might move medially. [1]

REFERENCES

- [1]. Bishara SE, Staley RN. Maxillary expansion. Clinical implications. *Am J Ortho Dentofacial Orthopaedics* 1987;91:3-14.
- [2]. Kumar SA, Gurunathan D, Muruganandham, Sharma S. *Journal of Clinical and Diagnostic Research*. 2011 August.5(4): 906-911
- [3]. Timms DJ. A study of basal movement with rapid maxillary expansion. *Am J Ortho Dentofacial Orthopaedics* 1980;77:500-507.
- [4]. Gill D, Naini F, McNally M, Jones A. The management of transverse maxillary deficiency. *Dent Update* 2004 Nov;31(9): 516-523
- [5]. Hass AJ. Palatal expansion: Just the beginning of dentofacial orthopedics. *Am J Ortho Dentofacial Orthopaedics* 1970;57:219-255.
- [6]. Kharbanda OP. Orthodontics diagnosis and management of malocclusion and dentofacial deformities. *elsevier*.2020(3);67-82
- [7]. Vasant MR, Menon S, Kannan S. Maxillary Expansion in Cleft Lip and Palate using Quad Helix and Rapid Palatal Expansion Screw. *MJAFI* 2009;65:150-153.