



## Rare Demographic Presentation of Epidermoid Cysts in Postauricular Region: A Case Series

Dr.Smit Shah, Dr.Vaishali Sangole, Dr.Jubina PP, Dr.Janvikansagra, Dr. Neha Deshmukh

Submitted: 18-12-2022

Accepted: 28-12-2022

### I. INTRODUCTION

Compared with other cutaneous cysts of the head and neck region, postauricular epidermoid cysts are rare, asymptomatic benign swellings. Epidermoid cysts are developmental cutaneous cysts derived from trapped pouches of ectodermal, neural tube and surface ectodermal separation failure<sup>(1)</sup> and from traumatic implantation of squamous epithelium<sup>(2)</sup>. Only 7% epidermoid cyst occur in the head and neck region<sup>(1, 3)</sup>. For site distribution of these cysts, postauricular location is a very rare occurrence<sup>(1, 4-6)</sup>. Most common out of the two is the dermoid type. Because of the location and the painless nature of the cyst, patients may take a long time to seek medical intervention<sup>(6, 7)</sup>.

### AIMS AND OBJECTIVES

The aim is to describe the clinical profile of postauricular epidermoid cysts. The objectives are to describe the demographic characteristic, symptoms duration and histological diagnosis in patients.

### II. MATERIALS AND METHODS

A descriptive study was conducted in 5 patients between 1-18 years in a period of 1 year. The clinical records were analyzed for age, sex, duration, histological types, post-auricular side involved (right or left), symptom(s) presentation, reasons for seeking medical intervention, and the recurrence after treatment. Inclusion criteria included patients between 1-18 years with post-auricular epidermoid cyst. Excluded from this study were patients older than 18 years and the other developmental cyst(s) in the other sites of the head and neck region. Data were analyzed by simple statistical analysis. On clinical examination of all the patients, swelling was soft, cystic, globular, and non-tender with restricted motility. Margins were well defined. Skin over the swelling was normal and not attached to it. There was no discharging sinus or pointing abscess. Bruit or any pulsations were absent. There was no

history trauma, fever, loss of appetite, discharging ear, difficulty in hearing, etc. The patient had no other complaints or other constitutional symptoms. There was no history of such lesions in his family members. A preliminary diagnosis of epidermoid cyst, dermoid cyst, or sebaceous cyst was proposed. Fine Needle Aspiration Cytology (FNAC) was done and revealed the presence of yellowish thick material, which was sent for cytological examination. The treatment consisted of total surgical removal of the lesion.

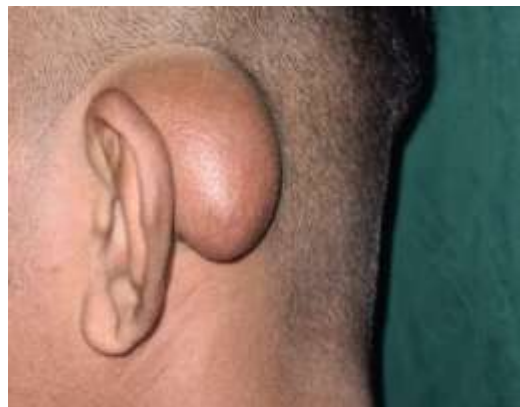

Fig 1: left epidermoid cyst in a 9 year old male.

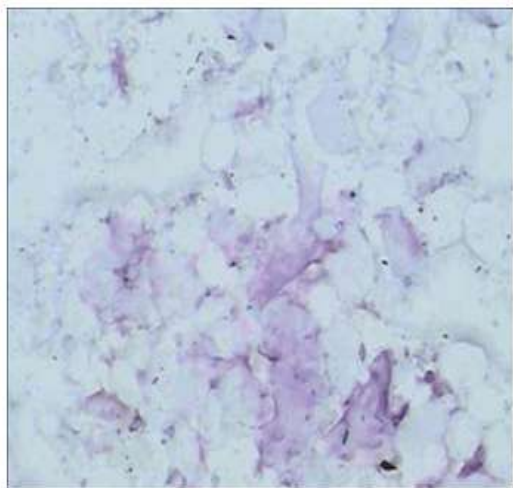


Fig 2: post auricular epidermoid cyst seen in an 18 year old male since 5 years

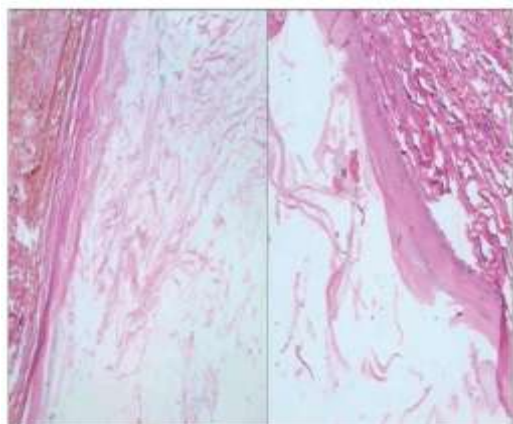


### III. RESULTS

Cytological examination revealed presence of desquamated epithelial cells and lots of keratin flecks. Histopathological examination confirmed the diagnosis of epidermoid cyst by presence of cystic lumen lined by stratified squamous epithelium with orthokeratin production. A total of five patients were reviewed: three males and two females. All the patients presented with asymptomatic postauricularextracranial cysts at the left postauricular side. Most patients sought medical intervention because of cosmetic reasons. There was no record of malignant transformation of the postauricular cysts. Complete surgical excision of the postauricularextracranial cysts was carried for all the lesions. No recurrence of the lesion was observed.



**Fig 3: Cytological examination revealed presence of desquamated epithelial cells and lots of keratin flecks**



**Fig 4: cystic cavity lined by stratified squamous epithelium with presence of keratin flecks supported by connective tissue stroma**

### IV. DISCUSSION

Epidermoid and dermoid cysts of the head and neck region are uncommon<sup>(1-7)</sup>, the usual site is commonly around the orbit<sup>(1,8,9)</sup>. Developmental cyst(s) rarely occur at the postauricular site<sup>(1-7)</sup> and this could explain why we had few cases during the study period.

Studies on the head and neck epidermoid and dermoid cysts irrespective of the sites showed that they could occur at any age<sup>(1-3, 10)</sup>. This study involves age group between 0-18 yrs. Studies have shown that in the postauricular region, epidermoid cyst are more common than dermoid cyst<sup>(1,9)</sup>. Unilateral asymptomatic swelling is usually the main complaint of patients with postauricular cysts<sup>(1-10)</sup>.

The cyst may rupture<sup>(11)</sup>, be inflamed, and be painful<sup>(2)</sup>. However, in this present study, all the patients presented with asymptomatic, unilateral, painless, and unruptured postauricular swellings. We routinely do an ultrasound for any postauricular cyst as the first line of radiological imaging, and computed tomographic scanning is requested for any suspicious intracranial extension. All the patients in this study had postauricularextracranial cysts. The main reason for seeking medical intervention was for cosmesis. The need for early presentation and treatment cannot be overemphasized to forestall this risk, as malignant transformation, though rare, carries a poor prognosis<sup>(7,12)</sup>. Recurrence of epidermoid and dermoid cysts may occur after incomplete excision. Hence, there is a need for reasonable follow-up after surgical excision for detection and to treat the recurrent cyst.

### V. CONCLUSION

In conclusion, postauricular epidermoid cysts are rare in the head and neck region. Asymptomatic nature of this condition most probably contributes to the patient's delay in seeking early medical intervention. The need to create medical awareness for any disease conditions especially for asymptomatic conditions such as cutaneous cysts cannot be overemphasized to prevent malignant transformation, which carries a poor prognosis.

### REFERENCES:

- [1]. Jyothi SR, Sathyaki DC, Mohan M, Swaroop DM, Manjunah K, Shah WA, et al. Epidermoid cysts of head and neck. J Evol Med Dent Sci 2013; 2:7533-7536



- [2]. Cho Y, Lee DH. Clinical characteristic of idiopathic epidermoid and dermoid cyst of the ear. *J AudiolOtol* 2017; 21:77–80.
- [3]. De Souza BA, Dey C, Carven N. A rare case of dermoid cyst behind the ear. *PlastReconstrSurg* 2003; 112:1992.
- [4]. Dive AM, Khandekar S, Moharil R, Deshmukh S. Epidermoid cyst of the outer ear: a case report and review of literature. *Indian J Otol* 2012; 18:34-37
- [5]. Awasthi N. Postauriculardermoid cyst: an unusual presentation. *Int J Health Allied Sci* 2017; 6:121–122.
- [6]. Horikiri M, Ueda K, Kato M. Dermoid cyst of the auricle: a raremanifestation. *BMJ Case Rep* 2014; 2014:bcr2014205826.
- [7]. Srivastava A, Mohan C, Agrawal R, Bhardwaj P. Malignant changes in twinepidermoid cyst in neck: a rare case report. *Otolaryngol Online J* 2017;7:146.
- [8]. Sabhalot SS, Shetty LS, Sarve PH, Setiya SV, Bharadwaj SR. Epidermoidand dermoid of the head and neck region. *PlastAesthet Res* 2016;3:347–350.
- [9]. Pryor SG, Lewis JE, Weaver AL, Orvidas LJ. Pediatricdermoid of the headand neck. *Otolaryngol Head Neck Surg* 2005; 132:938–942.
- [10]. Jung HK, Choi JH, Nam HD. Characteristic of dermoid cyst of the auricle. *Arch CraniofacSurg* 2014; 15:22–27.
- [11]. Park SO, Ko KD. A histopathology study of study of epidermoid cyst inKorea: comparison between rupture and unruptured epidermal cyst. *IntClinExpPathol* 2013; 6:242–248.
- [12]. Stephenson GC, Ironside JW. Squamous cell carcinoma arising in a subcutaneous dermoid cyst. *Postgrad Med J* 1991; 67:84–86.