



## Role of Ultrasound in Female Infertility

1Dr.Hetal Ahir, 2Dr.Anjana Trivedi

Resident Doctor ,Department of Radiodiagnosis ,PDU Medical College and  
government hospital,Rajkot

Professor and Head,Department of Radiodiagnosis ,PDU Medical college and  
government hospital,Rajkot

Corresponding Author :Dr.Hetal Ahir

Submitted: 01-08-2021

Revised: 08-08-2021

Accepted: 13-08-2021

**ABSTRACT** : Ultrasound has become an important tool for the diagnosis of female infertility by demonstrating pelvic organs ,growing ovarian follicles and cyclical changes in the endometrium during the menstrual cycle .Ultrasound particularly can demonstrate ovarian flow and resistance of flow and many other parameters affecting the follicular growth .In assisted reproductive technology(ART) ultrasound is indispensable tool for the monitoring of ovarian follicles after hormone stimulation ,ovum pick up ,embryo transfer and also thereafter.The average diameter of follicles is measured. Among the study conducted it is found that ovulation induction will be successful if preovulatory follicular diameter was between 18 to 24 mm.The risk of overstimulation can be assessed with ultrasound.The detection of ovulation is the most important step in management of infertility . Ultrasound is more important for determining the time of ovulation than other methods like basal body temperature or hormonal studies. Ultrasound is also important for visualisation of uterine size-position,fallopian tubes and any congenital anomalies of genitourinary system.In the uterus it has very important role for endometrium ,the physiological changes occurring in endometrium during the menstrual cycle.Female infertility is multifactorial in origin ,ultrasound plays an important role in female infertility work up with hysterosalpingography(HSG) ,sonohysterography and MRI ,each playing a complimentary role in screening ,diagnosis and management of female infertility.

**KEYWORDS:**ultrasound,ovulation,endometrium,fallopian tube

### I. INTRODUCTION:

Ultrasound is useful first line investigation ,it is an effective ,safe ,inexpensive ,radiation free ,noninvasive ,easy to use and easily repeatable approach to evaluate female infertility.Aim of this is to provide clinicians with the role of ultrasonography in the evaluation of female

infertility and management of women who want to achieve pregnancy.Recognise various causes of female infertility and role of ultrasound in management of infertility in assisted reproductive technology (ART).

Causes of female infertility are varied and range from ovarian to tubal and peritubal abnormalities, uterine and cervical disorders.

#### 1. Ovarian Factors

- Polycystic ovarian syndrome (PCOS)
- Hypothalamic amenorrhea
- Luteinized unruptured follicle
- Ovarian infections or tumors

#### 2. Tubal factors:

- Ectopic pregnancy
- Endometriosis
- Pelvic inflammatory disease (PID)

#### 3.Uterine factors

- Developmental anomalies
- Adhesions (Asherman's syndrome)
- Infections
- Tumors

#### 4.Cervical Factors

- Cervicitis
- Abnormal cervical mucus

#### 5.Idiopathic

#### • **Pelvic sonography**

This is the most valuable, an efficient and inexpensive scoring tool to detect developmental or acquired uterine and ovarian pathology. Female infertility that is due to gynecologic abnormalities and/or ovulation disorders requires ultrasound as valuable contributor in its work up.

US offer the following contributions in the investigation and treatment of female infertility.

- To assess the anatomy of the pelvic organs
- Developmentalanomaliesor abnormal mass or fluid collection can be detected by either transabdominal



- sonography (TAS) or Transvaginal Sonography (TVS).
- To monitor the development and evolution of ovarian follicles

US is an efficient cost effective modality for studying the female reproductive organs and monitoring the functional changes during spontaneous and induced cycles. During ovulation induction with clomiphene citrate or human menopausal gonadotropin (hMG), TVS is used to monitor the development of ovarian follicles. This is carried out from day 7 of the patient's cycle, preferably on a daily basis. This allows the clinician to manipulate and adjust the dosage of medication. During the administration of medication, follicular monitoring with serial TVS should be performed. A follicle is considered mature when it measures 15–18 mm in mean diameter. Ovulation is thought to occur when fine echoes are seen in the mature follicle.

#### **To evaluate the endometrium**

Changes in the endometrial thickness and variation in uterine blood flow may be determined with US during the menstrual cycle and during ovulation induction. Ultrasound allows the study of the 3 main implantation markers: endometrial thickness, endometrial volume and endometrial morphological patterns. For measurement of blood flow, the role of color Doppler is required.

#### **To identify congenital uterine anomaly and fallopian tube anomalies:**

Mullerian duct anomalies occur secondary to failure of organogenesis, failure of fusion or failure of reabsorption, causing incomplete development of one or both of the uterine horns. These anomalies are classified by the American Fertility Society (AFS) classification scheme. The scheme is based on the embryologic development of the mullerian ducts and is divided into 7 classes.

Class I: Uterine hypoplasia and/or agenesis

Class II: Unicornuate uterus

Class III: Uterus Didelphys

Class IV: Bicornuate uterus

Class V: Septate uterus

Class VI: Arcuate uterus and

Class VII: Diethylstilbesterol (DES) – related anomalies

#### **Submucous fibroid**

Fibroids, also known as leiomyomas or myomas are benign estrogen-dependent smooth-muscle tumors that originate from the uterine

myometrium, occurring in 20% to 40% of women in their reproductive years. The masses that protrude into the endometrial canal, are described as submucous in location and cause infertility by interfering with embryo implantation. TVS demonstrates a focal heterogeneous mass that is hypoechoic to the myometrium and may have acoustic shadowing.

#### **Endometrial Polyps**

Endometrial polyps are focal overgrowth of the endometrial glands and stroma surrounded by normal endometrium. TVS and/or sonohysterography are the imaging modalities of choice demonstrating a focal echogenic mass protruding into the endometrial lumen from the endometrium.

#### **To identify acquired abnormalities of fallopian tube**

**Hydrosalpinx** It is the dilatation of the proximal tube as a result of blockage of ampullary portion of the fallopian tube taking on a classic sausage-shaped appearance. The condition is often bilateral and is caused by scarring or adhesions of the distal tube from PID, adhesions from previous pelvic surgery or trauma, endometriosis and tubal neoplasm. Ultrasound may show a fluid-filled tubular structure. The imaging characteristics of the fluid vary depending on whether the fluid is simple, hemorrhagic, protein or pus filled.

## **II. MATERIAL AND METHODS:**

We have done prospective study on 120 females referred from gynecology department having complain of infertility between the duration of march 2021 to may 2021 with the use of ultrasound at P.D.U. medical college and civil hospital, Rajkot. Consent for participation in the study was taken from the patient. The indication and details of the ultrasound examination procedure explained to patient. A written consent will be obtained either from the patient or her relatives. Observations will be recorded in patient proformas and analysed statistically. Causes of infertility were divided into ovarian causes, uterine causes, fallopian tube causes. Final possible diagnosis will be made after ultrasound findings and clinical information.

## **III. RESULTS:**

Out of 120 females of mean age between 25 years to 35 years having infertility complaints were evaluated. Ovarian causes were the most common cause (27%) followed by Tubal factors (22%) and uterine factor (11%), cervical causes



(5%) rest was unexplained . Among the ovarian causes anovulation was the most common cause followed by poly cystic ovarian disease.Among the tubal causes tubal block was the most common which was not identified on ultrasound and findings were on the HSG(hysterosalpingo

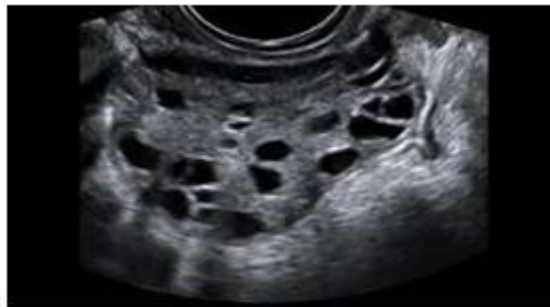graphs).Tubal pathologies which were identified are hydrosalpinx/pyosalpinx.Among the uterine causes adenomyosis was the most common followed endometrial polyp and submucosal fibroid.Rare cases were of mullerian anomalies of uterus ,among many we found sepatate uterus.

TABLE :

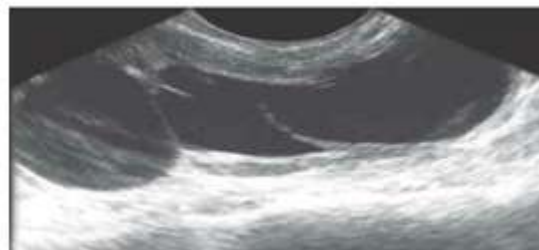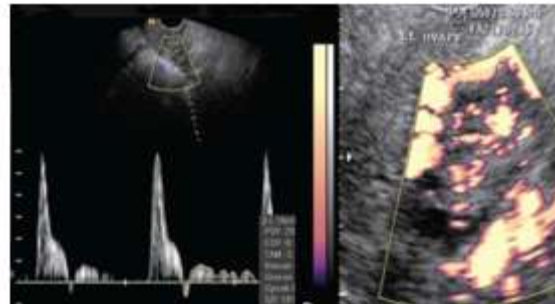
cause	No.of patient	percentage
Ovarian	33	27%
Tubal	26	22%
Uterine	14	11%
Cervical	6	5%
unexplained	41	53.1%

**IMAGES:**

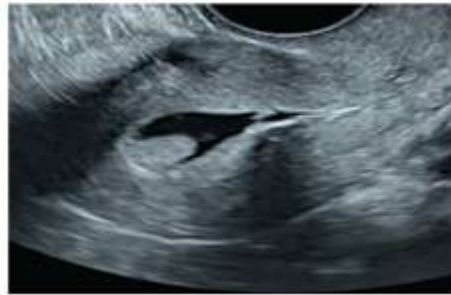- **POLYCYSTIC OVARIAN DISEASE** - Radiological findings include multiple subcentimetric follicles mainly placed peripherally.Doppler findings include increased diastolic flow,increased stromal vascularity.



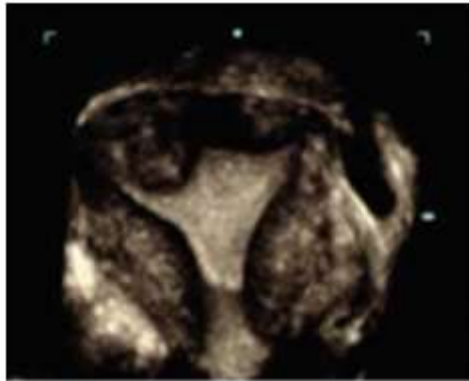
- **HYDROSALPINX** - Dilated fluid filled tubular structure with incomplete septa within traversing from uterus to ovary is visualised.



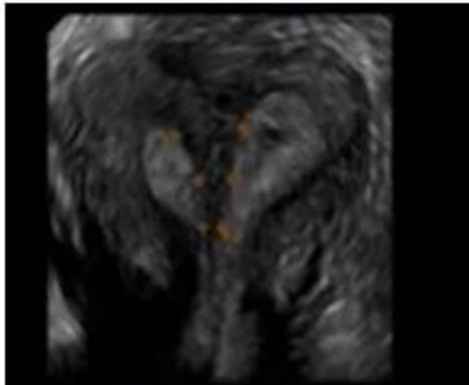
- **UTERINE POLYP** - Well defined echogenic lesion protruding inside the endometrial cavity with evidence of stalk vascularity.



- **SUBMUCOSAL FIBROID-**



- **BICORNUATE UTERUS-**



#### **IV. LIMITATIONS OF STUDY -**

Ultrasonographic limitations broadly include suboptimal visualization of fallopian tubes and broad ligament, failure to delineate small ovaries and inability to obtain images in the surgical plane, limited field of view, interference by obesity or by gaseous bowel loops and subjective errors. US do not play major role in the diagnosis of primary causes of ovarian factor infertility such as nonfunctional ovaries, premature ovarian failure, and gonadal dysgenesis. However, US can play a major role in detecting the secondary causes of ovarian factor infertility such as endometriosis and polycystic ovarian syndrome.

#### **V. CONCLUSION –**

Causes of female infertility are multifactorial in origin with both congenital and acquired problems of the uterus, fallopian tubes and ovaries. Ultrasound plays an important role in female infertility work-up with HSG, sonohysterography and MRI, each playing a complimentary role in the screening, diagnosis, and/or management of female infertility.

#### **REFERENCES –**

- [1]. Seibel MM, McArdle CR, Thompson IE, Berger MJ, Taymor ML. The role of ultrasound in ovulation induction: A



- critical appraisal. *Fertil Steril.* 1981;36:573.
- [2]. Gleicher N, Friberg J, Fullan N, et al. Egg retrieval for in vitro fertilization sonographically controlled vaginal culdocentesis. *Lancet.* 1983;2:508.
- [3]. Dellenbach P, Nisand I, Moreau L, et al. Transvaginal sonographically controlled ovarian follicle puncture for egg retrieval. *Lancet* 1984;2:1467.
- [4]. Schwimer SR, Lebovic J. Transvaginal pelvic ultrasonography. *J Ultrasound Med.* 1984;3:381.
- [5]. Andreotti RE, Thompson GH, Janowitz W, Shapiro AG, Zusmer NR. Endovaginal and transabdominal sonography of ovarian follicles. *J Ultrasound.* 1989;8:555.
- [6]. Steinkeler JA, Woodfield CA, Lazarus E, Hillstrom MM. Female Infertility: A Systematic Approach to Radiologic Imaging and Diagnosis. *Radiographics.* 2009;29(5):1353-70.