



## Superior Mesenteric Artery Occlusion Due to Thrombus Treated Using Interventional Radiology in a Young Patient With COVID-19: A Case Report

Dr. Arif SSheikh<sup>a</sup>, Dr. Dharmik Bhuv<sup>b</sup>, Dr. Prince Surana<sup>c</sup>

<sup>a</sup> Department of Internal Medicine, MPCT Hospital, Navi Mumbai, India

<sup>b</sup> Department of Interventional Radiology, MPCT Hospital, Navi Mumbai, India

<sup>c</sup> Department of Internal Medicine, MPCT Hospital, Navi Mumbai, India

Date of Submission: 20-11-2020

Date of Acceptance: 10-12-2020

**ABSTRACT:** The COVID-19 disease caused by novel severe acute respiratory syndrome coronavirus 2 (SARS-CoV-2). Though this disease primarily presents as a lower respiratory tract infection, multiple digestive manifestations have been reported which are often overlooked. The present case report describes the unusual progression of COVID-19 disease from pneumonia to a procoagulant state leading to superior mesenteric artery thrombosis and subsequent gut ischemia. A thrombus in the superior mesenteric artery (SMA) is a critical condition that requires immediate diagnosis and treatment. We present a COVID 19 Positive case with a thrombus in SMA that was successfully treated by interventional radiology. A 36-year-old male with a history of respiratory symptoms admitted to our hospital. On day 2, he developed abdominal pain, Physical examination of his abdomen revealed tenderness over the upper abdomen without any signs of peritonitis, so ultrasound of abdomen done which showed fatty liver and mildly distended gall bladder, therefore, a proton pump inhibitor was administered and fasting treatment was resumed. On day 3, he presented with recurrent severe upper abdominal pain. Contrast-enhanced computed tomography (CT) was performed, revealing a suspected thrombus in the main trunk of SMA, low molecular weight heparin was subcutaneously administered. On day 4, abdominal angiography was performed, revealing an occluded thrombus in the proximal SMA with developed circulation in peripheral intestinal arteries. Subsequently, the thrombus was successfully resolved by, thrombolysis and thrombus aspiration through interventional radiology (IVR). On day 5, Check DSA abdominal aorta angiography was then performed, it revealed complete recanalization of superior mesenteric artery and its branches with almost complete resolution of thrombosis. The

overall clinical course was uneventful, and oral feeding along with oral administration of aspirin and warfarin was initiated on day 8.

Coagulopathy in COVID-19 is due to an imbalance in the coagulation homeostasis with increase in thrombocytes in contrast to thrombocytopenia documented in cases of dissemination intravascular coagulation and sepsis. Early recognition of abdominal symptoms, diagnosis of pathology and timely intervention radiological or surgical may definitely improve outcome.

**KEYWORDS:** COVID-19, SARS-CoV-2, Acute Mesenteric Ischemia; Superior Mesenteric Artery Thrombosis; Occlusion; Thrombus; Interventional radiology

### I. INTRODUCTION:

Coronavirus disease 2019 (COVID-19), caused by the severe acute respiratory syndrome coronavirus 2 (SARS-CoV-2), has become a global pandemic. SARS-CoV-2 binds to the angiotensin-converting enzyme 2 receptor, which is abundantly expressed in vascular endothelial cells and damages these cells. Besides pneumonia-induced respiratory failure, thrombotic cardiovascular complications are increasingly emerging as a major COVID-19 symptom.(1)

Acute mesenteric artery occlusion is a critical condition with a high mortality rate of 60-80% which requires urgent diagnosis and treatment (2). Acute superior mesenteric artery (SMA) occlusion, if left untreated, may lead to irreversible intestinal ischemia and subsequently, result in intestinal necrosis. The main risk factors are: heart failure, atrial fibrillation, coronary artery disease, arterial hypertension and peripheral arterial occlusion. The risk factors that affect morbidity and mortality in acute mesenteric ischemia are: advanced age, leucocytosis, the time elapsed for



laparotomy and colonic involvement. Therefore, surgical intervention is sometimes required. Recently, with the development of interventional radiology (IVR), thrombus aspiration using a catheter is usually attempted unless the intestinal necrosis is progressive. In SMA occlusion, if a thrombus or emboli is located in the proximal SMA without developing peripheral circulation, intestinal ischemia leads to intestinal necrosis followed by immediate death. Alternatively, if collateral arteries are established after a thrombus in SMA, progression of intestinal ischemia may be alleviated. Here we discuss a case of SMA occlusion by a thrombus that was successfully treated using IVR.

## II. CASE REPORT:

A 36-year-old male, diagnosed as COVID-19 positive (RT-PCR) presented with respiratory symptoms to our hospital, a dedicated COVID-19 Centre. On admission pulse 110 bpm with regular rhythm, body temperature was 36.8 °C, Blood pressure 150/70 mmHg and Saturation on room air 98%. Auscultation of the heart was normal. Bedside chest X-ray and HRCT chest was done which showed pneumonia pattern in the peripheral and basal region. (Fig 1).

Blood chemistry analysis revealed elevated white blood cell counts (11,400 cells/ $\mu$ L), dense red blood (red blood cell count,  $605 \times 10^4$  cells/ $\mu$ L and haemoglobin, 14.0 g/dL), elevated lactate dehydrogenase (347 IU/L), elevated glucose levels (256 mg/dL), mildly elevated fibrin and fibrinogen degradation product (4.7  $\mu$ g/mL), elevated CRP levels (78.0) and D-dimer levels (0.59  $\mu$ g/mL). Liver function test, activated partial thromboplastin time (aPTT) and Prothrombin time (PT) were normal. Treatment was started with tazobactam-piperacillin, prophylactic low molecular weight heparin (enoxaparin), pantoprazole, vitamin C and zinc as per institutional protocol.

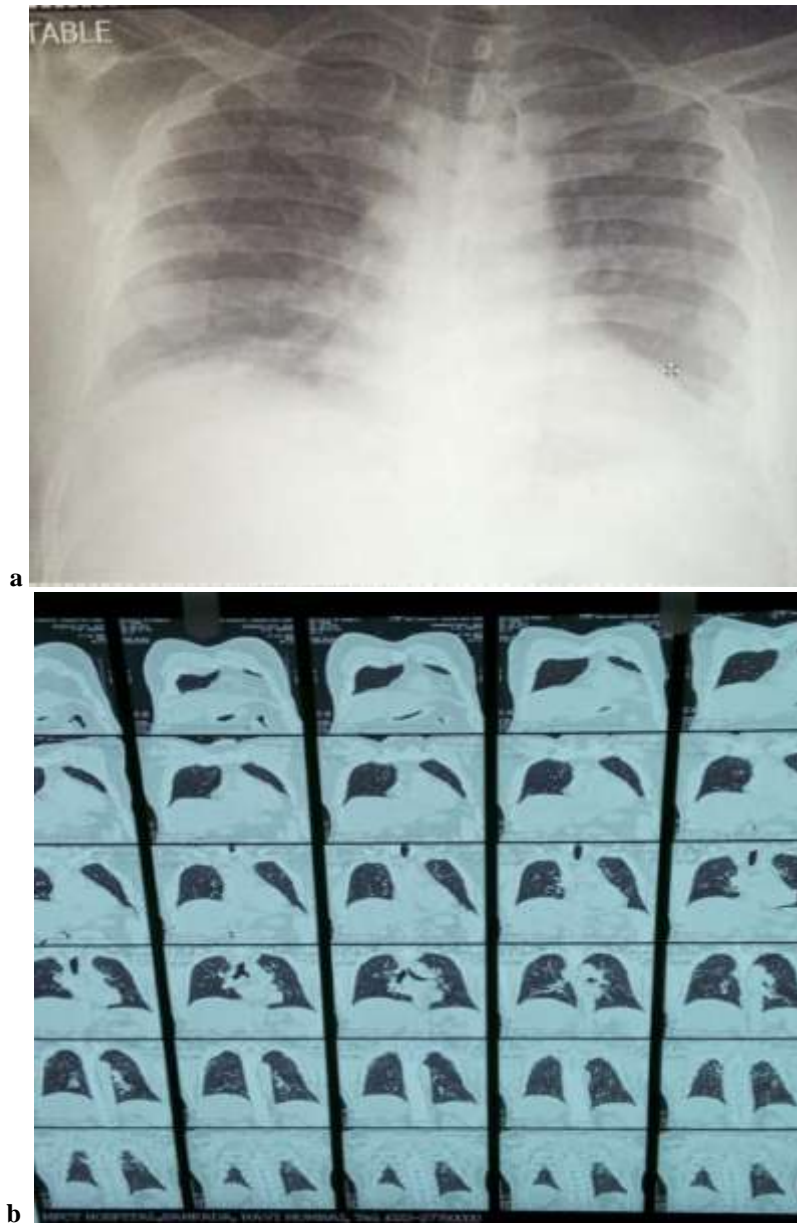
On day 2, he developed abdominal pain, physical examination of abdomen revealed tenderness over the upper abdomen without any

signs of peritonitis and ultrasound of abdomen done which showed fatty liver and mildly distended gall bladder. Therefore, a proton pump inhibitor was administered and fasting treatment was started.

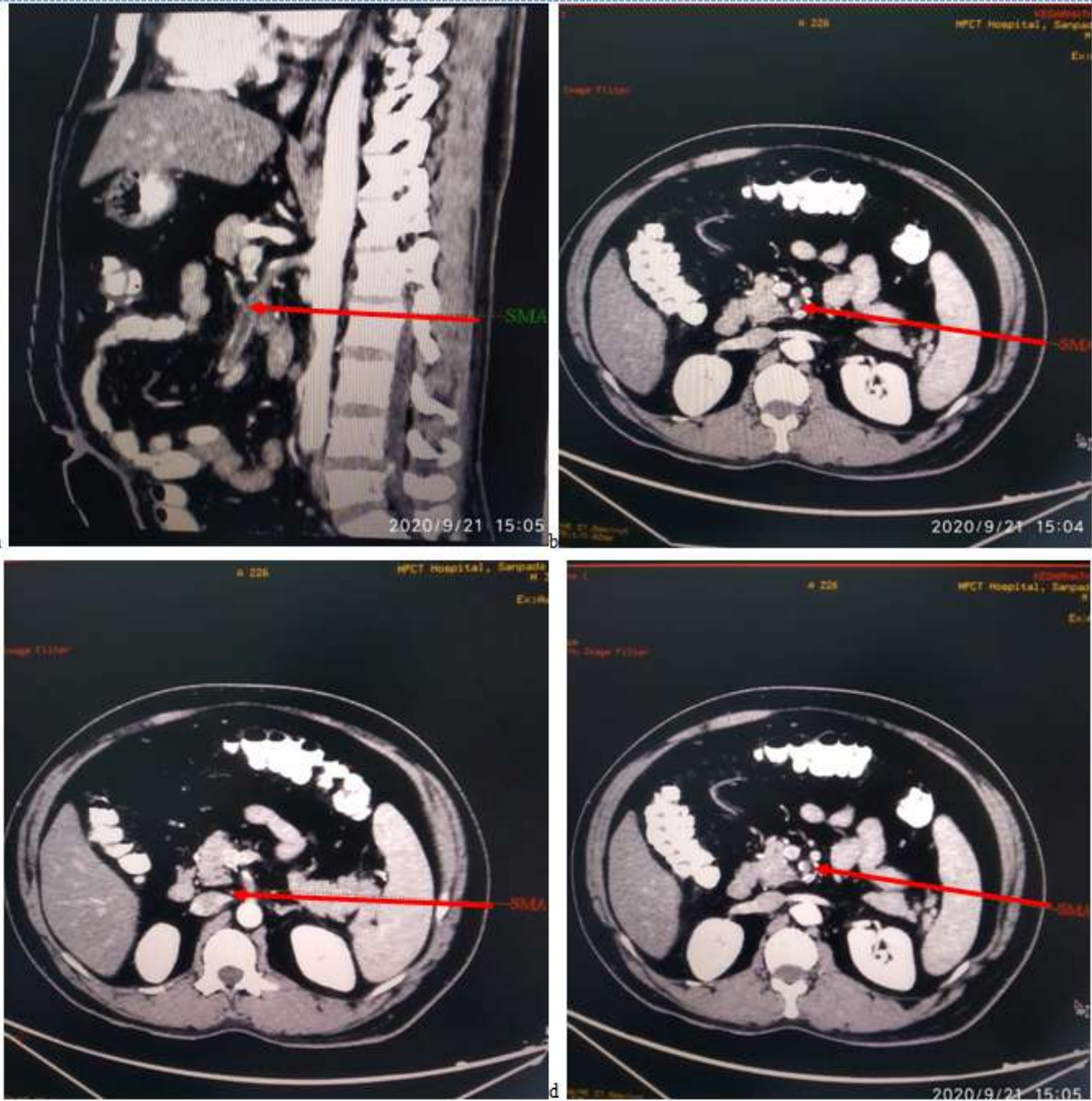
On day 3, he developed recurrent severe upper abdominal pain, contrast-enhanced computed tomography (CT) was performed, it revealed a suspected thrombus in the main trunk of SMA (Fig 2) as well as extensively dilated small bowels (Fig 3). Coronal sections and three-dimensional contrast-enhanced CT indicated that the thrombus was located in the second branch of the jejunal artery. Immediately, low molecular weight heparin (enoxaparin) was administered at therapeutic dose subcutaneously.

On day 4, his abdominal pain persisted, abdominal angiography was performed, it revealed a large filling defect involving proximal and mid part of superior mesenteric artery except for its origin suggestive of thrombus. There is also evidence of complete thrombotic occlusion of its branches. (Fig 4). Subsequently, thrombolysis and thrombus aspiration were performed by interventional radiology (IVR). The thrombotic lesion was crossed using single length guidewire and catheter was then parked distally. Bolus of injection Recombinant Tissue Plasminogen Activator (r-tpa) 3 mg and injection heparin 5000 units was given through the catheter parked in SMA. Mechanical thrombo-aspiration was done using 6F MPA, adequate catheter clots were taken out. Fournain catheter was then parked in SMA and its branches exchanged over double length guidewire and kept for overnight thrombolysis using infusion of injection Recombinant Tissue Plasminogen Activator (r-tpa) @ 1 mg/hour for 24 hours. Infusion of injection heparin was given through right femoral sheath @ 1000 units/hour for 24 hours.

On day 5, check DSA abdominal aorta angiography was performed, it revealed complete recanalization of superior mesenteric artery and its branches with almost complete resolution of thrombosis. (Fig 5).

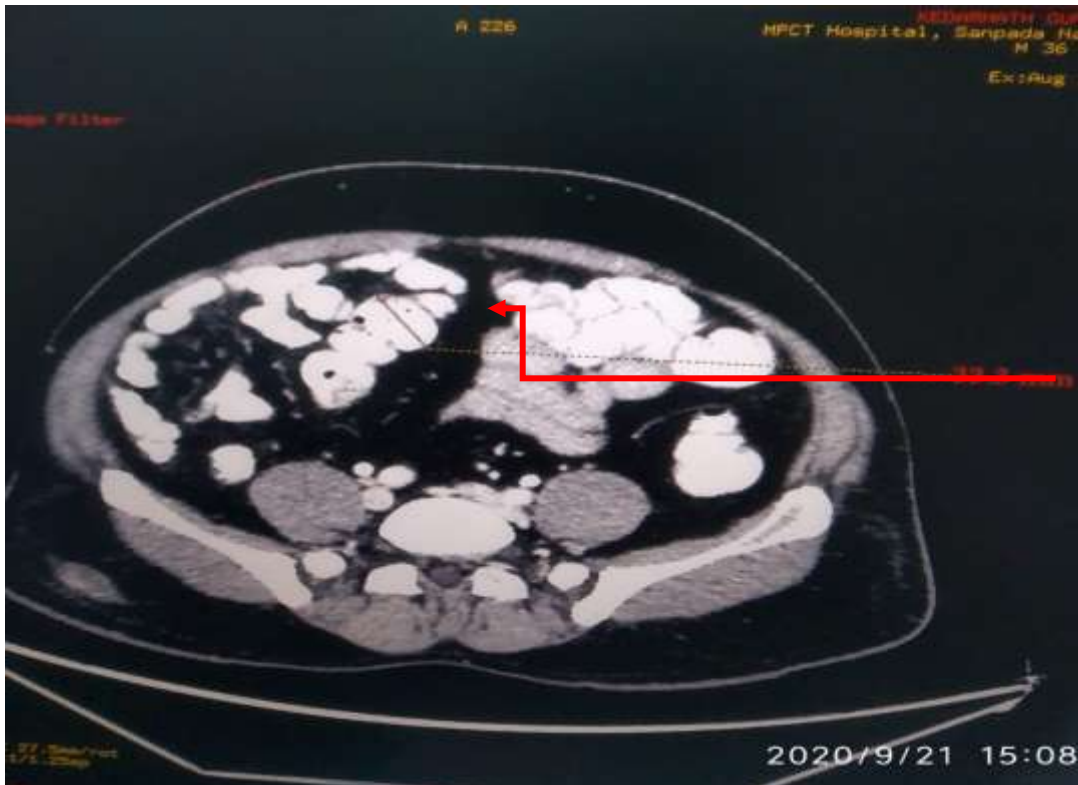

**Figure 1.** (a) chest Xray and (b)HRCT chest was done which showed pneumonia pattern in the peripheral and basal region

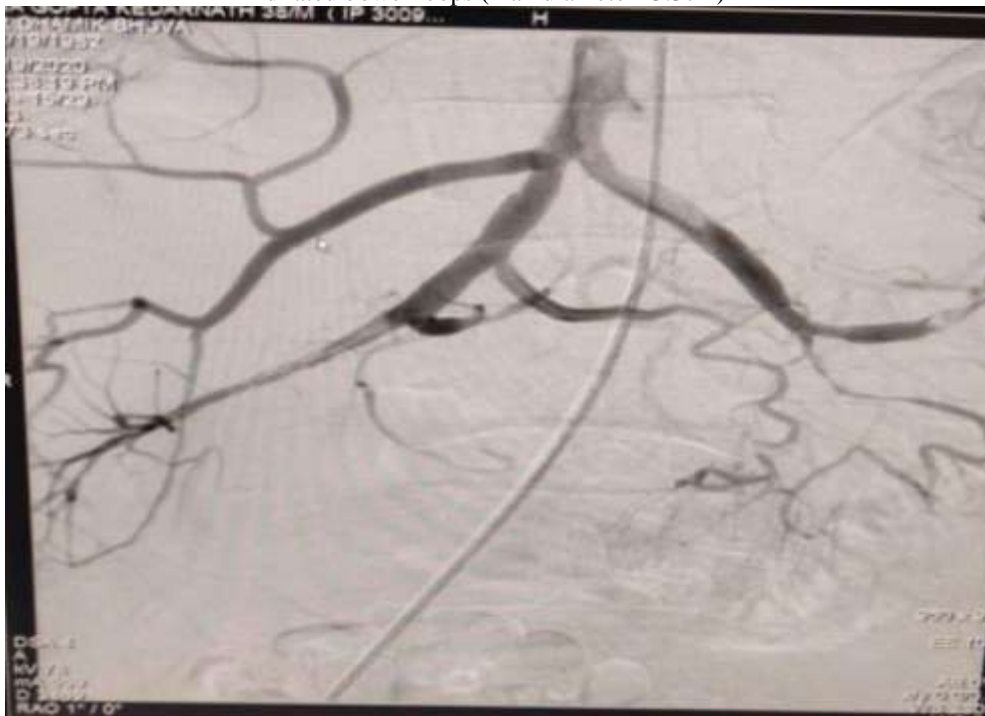

**Figure 2.** Contrast-enhanced computed tomography (CECT) reveals a hypodense lesion, suspected thrombus (arrow) in the main trunk of the superior mesenteric artery (a) in sagittal view. Axial sections (b)(c)(d) suggest that the thrombus is located in the main trunk of the SMA at the level of the second branch of the jejunal artery (arrow).

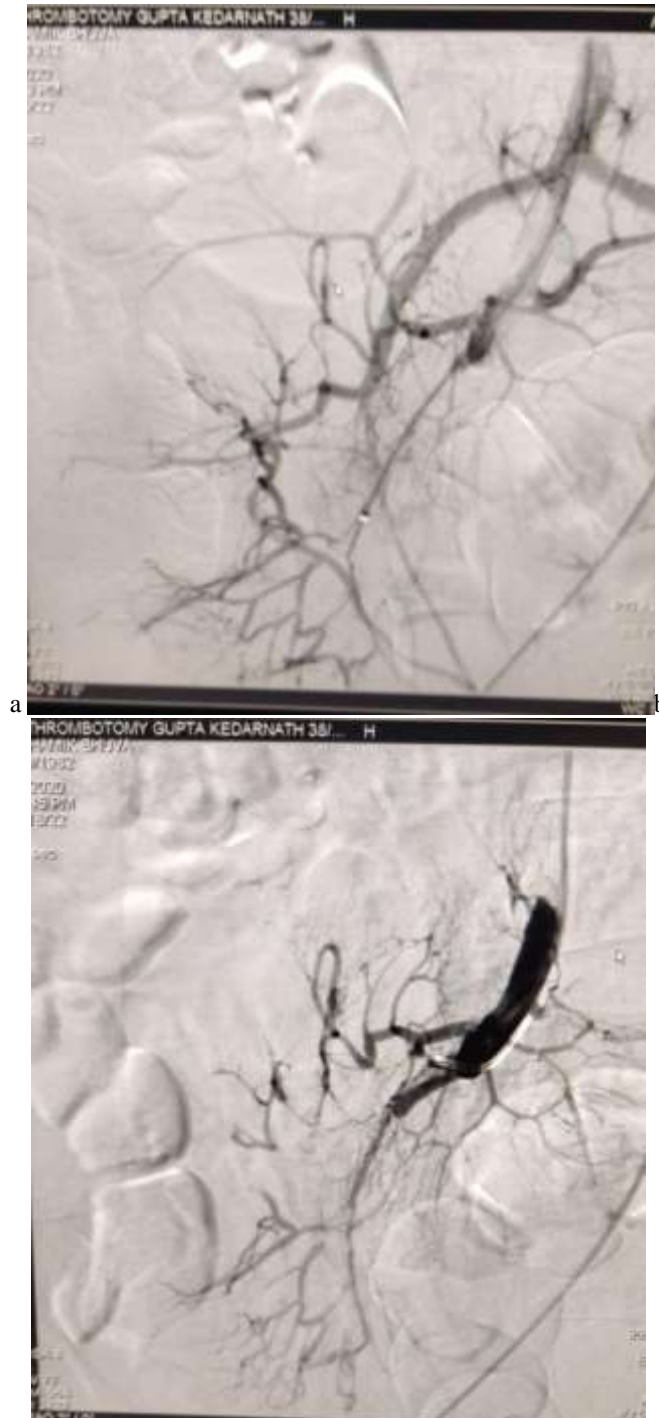




**Figure 3.** Axial section of Contrast-enhanced computed tomography (CECT) abdomen study shows mildly dilated bowel loops (max diameter -3.3cm)



**Figure 4.** Abdominal angiography reveals large filling defect involving proximal and mid part of Superior mesenteric artery except for its origin suggestive of thrombus. There is also evidence of complete thrombotic occlusion of its branches.



**Figure 5. (a)** thrombolysis and thrombus aspiration were performed through interventional radiology (IVR), **(b)** Check DSA abdominal aorta angiography was then performed, it revealed complete recanalization of superior mesenteric artery and its branches with almost complete resolution of thrombosis.

Administration of antibiotics treatment and fasting were continued after thrombolysis. Although the peak C-reactive protein (CRP) levels were severely elevated (111.9 mg/dL), there was no

sign of peritoneal irritation or evidence of intestinal necrosis. CRP levels gradually dropped and clinical symptoms improved. On day 8, oral intake of anti-coagulant and antiplatelet agents was initiated to



prevent reformation of thrombosis. The subsequent clinical course was uneventful.

### III. DISCUSSION:

SMA occlusion is an acute abdomen disease with a high mortality rate of 60-80% (2). Acute SMA occlusion is caused by the occlusion of the mesenteric artery which can lead to extensive intestinal necrosis and pan peritonitis, leading to septic shock and disseminated intravascular coagulation. In the course of COVID-19 disease, SARS-CoV-2 infection induces the production of cytokines, such as interferons and interleukins, resulting in a systemic inflammatory reaction, which eventually causes the so-called cytokine storm(3)(4). Higher cytokine concentrations can lead to systemic thrombus formation, with consequent pulmonary artery thrombosis, cerebral infarction, MI and lower limb arterial thrombosis(5). SARS-CoV-2 uses ACE2 receptor to enter vascular endothelial cells, ACE2 receptor is expressed in other organs, such as the heart, kidneys and intestinal tract, as well as in high concentrations in vascular endothelial cells(6), thereby injuring the vascular endothelium and appear to be involved in COVID-19 thrombogenesis.

In our case, there was serial increase in platelet levels with sustained elevated CRP levels suggesting reciprocity of thrombotic and inflammatory state. Till now, only six cases of SMA thrombosis in COVID-19 positive patients are reported in the world (3 patient in Strasbourg, 2 patient in Paris and 1 patient in Italy, respectively) (7)(8)(9).

Accurate diagnosis rates of SMA occlusion by angiography are much higher than those by contrast-enhanced CT. Angiography is efficient not only for diagnosis but also for the subsequent treatment, including angioplasty or thrombolysis. The application of IVR in SMA occlusion is limited to intestinal ischemia without intestinal necrosis; if SMA occlusion is accompanied by intestinal necrosis, surgical intervention, including vascular revascularization and intestinal resection, is required (10).

However, patients with COVID-19 often present late or treatment of respiratory symptoms is given precedence over abdominal symptoms (11). Mucosal ischemia may further induce massive spread of virus from bowel epithelium leading to vasoplegic shock after surgery

Evidence of intestinal necrosis is supported by clinical presentation (signs of

peritoneal irritation or shock), biochemistry analysis (elevated white blood cell counts, increased aspartate aminotransferase, creatinine phosphokinase levels, lactate dehydrogenase levels, or presence of metabolic acidosis), or radiological findings (pneumatosis intestinalis, intrahepatic portal venous gas, or intraperitoneal free air). In general, the golden time for treating a thrombus in SMA, where intestinal ischemia can be reversed and intestinal resection can be avoided, is deemed to be within 10 - 12 h after the onset (12). However, it has become clear that this principle does not always hold true depending on the site(s), degree(s), or severity of SMA occlusion.

Acute SMA occlusion, unless treated within 10 - 12 h from the onset, is considered to cause irreversible intestinal necrosis. In our patient, thrombolytic therapy was initiated at 72 h after the clinical manifestation. Despite the main trunk of SMA being occluded by a thrombus, blood flow to the small intestines was preserved because of the development of collateral arteries. Acute SMA occlusion has been classified into the following three types, depending on the location of the occlusion (10): type A, where the occlusion is in the origin of the main trunk of SMA or proximal to the middle or right colic artery; type B, where the occlusion is between right colic artery and ileocolic arteries; and type C, where the occlusion is distal to the ileocolic artery. Type A is not expected to establish collateral circulation, thereby developing intestinal necrosis within 5 h and requires a laparotomy rather than thrombolysis. In contrast, type B and type C yield favourable results of revascularization even if treatment is initiated after the golden time. It can be safely said that the indication for thrombolytic therapy can be broadened depending on the causes and locations of ischemia and extent of collateral vessels. In our case, this patient might have chronic stenotic locations at the main trunk of SMA that originated from atherosclerosis, and thromboembolism might occur in those regions.

Several problems may occur after thrombolysis with IVR: 1) reperfusion injury after recanalization (13), 2) chronic thrombosis resistant to thrombotic agents, 3) lack of assessment regarding recovered intestinal circulation, and 4) reformation of thrombosis after recanalization. Reperfusion injury after recanalization remains to be investigated and is currently under research. It is possible, whether SMA is occluded by fresh or chronic thrombosis, to successfully resolve the lesion using a guide wire. Thus far, there are few optimal methods for estimating intestinal perfusion;



however, a combination of laboratory analysis and imaging modalities, including contrast-enhanced CT and Doppler US, improves the assessment of the intestinal circulation. Anti-coagulant therapy after the recanalization is essential to prevent thrombosis from reforming. If acute SMA occlusion is treated with thrombolysis, subsequent intravenous administration of heparin sodium is required.(14)(15)(16)

#### IV. CONCLUSION:

In management of any patient with COVID 19 disease, a holistic approach should be adopted with evaluation of digestive symptoms along with respiratory. SMA thrombosis should be suspected in these patients if one has abdominal distension or pain with increased inflammatory markers. We have presented a case of acute SMA occlusion by a thrombus that was successfully treated by IVR. Endovascular treatment may be possible even after 12 hours have passed since the clinical onset, if collateral blood flow was established. However, immediate diagnosis and treatment is required to prevent further intestinal ischemia. It is also important to note that acute mesenteric artery occlusion is one of the differential diagnosis of upper abdominal pain.

Declarations

Funding: none

Conflict of interest: Authors declare no conflict of interest

Consent: Consent was given by the patient for publication of Case report and use of data for research purposes

#### REFERENCES:

- [1]. Bikdeli B, Madhavan M V., Jimenez D, Chuich T, Dreyfus I, Driggin E, et al. COVID-19 and Thrombotic or Thromboembolic Disease: Implications for Prevention, Antithrombotic Therapy, and Follow-Up. *J Am Coll Cardiol* [Internet]. 2020 Jun;75(23):2950–73. Available from: <https://linkinghub.elsevier.com/retrieve/pii/S0735109720350087>
- [2]. Yasuhara H. Acute Mesenteric Ischemia: The Challenge of Gastroenterology. *Surg Today* [Internet]. 2005 Mar 18;35(3):185–95. Available from: <http://link.springer.com/10.1007/s00595-004-2924-0>
- [3]. Soy M, Keser G, Atagündüz P, Tabak F, Atagündüz I, Kayhan S. Cytokine storm in COVID-19: pathogenesis and overview of anti-inflammatory agents used in treatment. *Clin Rheumatol* [Internet]. 2020 Jul 30;39(7):2085–94. Available from: <http://link.springer.com/10.1007/s10067-020-05190-5>
- [4]. Mehta P, McAuley DF, Brown M, Sanchez E, Tattersall RS, Manson JJ. COVID-19: consider cytokine storm syndromes and immunosuppression. *Lancet* [Internet]. 2020 Mar;395(10229):1033–4. Available from: <https://linkinghub.elsevier.com/retrieve/pii/S0140673620306280>
- [5]. Varga Z, Flammer AJ, Steiger P, Haberecker M, Andermatt R, Zinkernagel AS, et al. Endothelial cell infection and endotheliitis in COVID-19. *Lancet* [Internet]. 2020 May;395(10234):1417–8. Available from: <https://linkinghub.elsevier.com/retrieve/pii/S0140673620309375>
- [6]. Lukassen S, Chua RL, Trefzer T, Kahn NC, Schneider MA, Muley T, et al. <scp>SARS</scp> -CoV-2 receptor <scp>ACE</scp> 2 and <scp>TMPRSS</scp> 2 are primarily expressed in bronchial transient secretory cells. *EMBO J* [Internet]. 2020 May 18;39(10). Available from: <https://onlinelibrary.wiley.com/doi/abs/10.15252/emj.20105114>
- [7]. A Beccara L, Pacioni C, Ponton S, Francavilla S, Cuzzoli A. Arterial Mesenteric Thrombosis as a Complication of SARS-CoV-2 Infection. *Eur J case reports Intern Med* [Internet]. 2020;7(5):1690. Available from: <http://www.ncbi.nlm.nih.gov/pubmed/32399456>
- [8]. de Barry O, Mekki A, Diffre C, Seror M, El Hajjam M, Carlier R-Y. Arterial and venous abdominal thrombosis in a 79-year-old woman with COVID-19 pneumonia. *Radiol case reports* [Internet]. 2020 Jul;15(7):1054–7. Available from: <http://www.ncbi.nlm.nih.gov/pubmed/32351657>
- [9]. Ignat M, Philouze G, Aussenac-Belle L, Faucher V, Collange O, Mutter D, et al. Small bowel ischemia and SARS-CoV-2 infection: an underdiagnosed distinct clinical entity. *Surgery* [Internet]. 2020;168(1):14–6. Available from: <http://www.ncbi.nlm.nih.gov/pubmed/32473831>
- [10]. Moteki K, Ishitobi K, Seki M et al. Acute Superior Mesenteric Arterial Occlusion -





- Occlusion Sites and its Clinical Course. *J Abdom Emerg Med*. 1996;16(2):427–32.
- [11]. Pan L, Mu M, Yang P, Sun Y, Wang R, Yan J, et al. Clinical Characteristics of COVID-19 Patients With Digestive Symptoms in Hubei, China. *Am J Gastroenterol* [Internet]. 2020 May;115(5):766–73. Available from: <http://journals.lww.com/10.14309/ajg.0000000000000620>
- [12]. Batellier J, Kieny R. Superior Mesenteric Artery Embolism: Eighty-Two Cases. *Ann Vasc Surg* [Internet]. 1990 Mar;4(2):112–6. Available from: <https://linkinghub.elsevier.com/retrieve/pii/S0890509606620189>
- [13]. Zimmerman BJ, Granger DN. Reperfusion Injury. *Surg Clin North Am* [Internet]. 1992 Feb;72(1):65–83. Available from: <https://linkinghub.elsevier.com/retrieve/pii/S0039610916456288>
- [14]. Lindblad B, Lindh M, Chuter T, Ivancev K, Surgery V. ENDOVASCULAR AND SURGICAL TECHNIQUES Superior Mesenteric Artery Occlusion Treated with PTA and Stent Placement. 1996;495:493–5.
- [15]. Maleux G, Wilms G, Stockx L, Vancleemput J, Baert AL. Percutaneous recanalization and stent placement in chronic proximal superior mesenteric artery occlusion. *Eur Radiol* [Internet]. 1997 Sep 7;7(8):1228–30. Available from: <http://link.springer.com/10.1007/s003300050280>
- [16]. Bocchini T, Hoffman J, Zuckerman D. Mesenteric Ischemia due to an Occluded Superior Mesenteric Artery Treated by Percutaneous Transluminal Angioplasty. *J Clin Gastroenterol* [Internet]. 1995 Jan;20(1):86–8. Available from: <http://journals.lww.com/00004836-199501000-00023>