



Treacher Collins Syndrome: A Case Report and Review of Literature

Garima Gulati¹, Dr. Puneeta Vohra², Dr. Archana Nagpal³

1. MDS Student, Department of Oral medicine and Radiology, SGT university, Gurugram

2. Professor, Department of Oral Medicine and Radiology, SGT university, Gurugram

3. Professor and Head of Department, Department of Oral Medicine and Radiology, SGT university, Gurugram

Submitted: 15-04-2022

Accepted: 29-04-2022

ABSTRACT

Treacher Collins syndrome (TCS) is a genetic disorder that arises during early embryogenesis and is characterized by abnormality of craniofacial development. It is generally characterized by bilateral symmetrical abnormalities of structures which fall within the first and the second branchial arches. The main clinical findings include midface hypoplasia, micrognathia, microtia, conductive hearing loss, and cleft palate. In this article, a case report of 18-year-old male presenting with TCS is discussed briefly

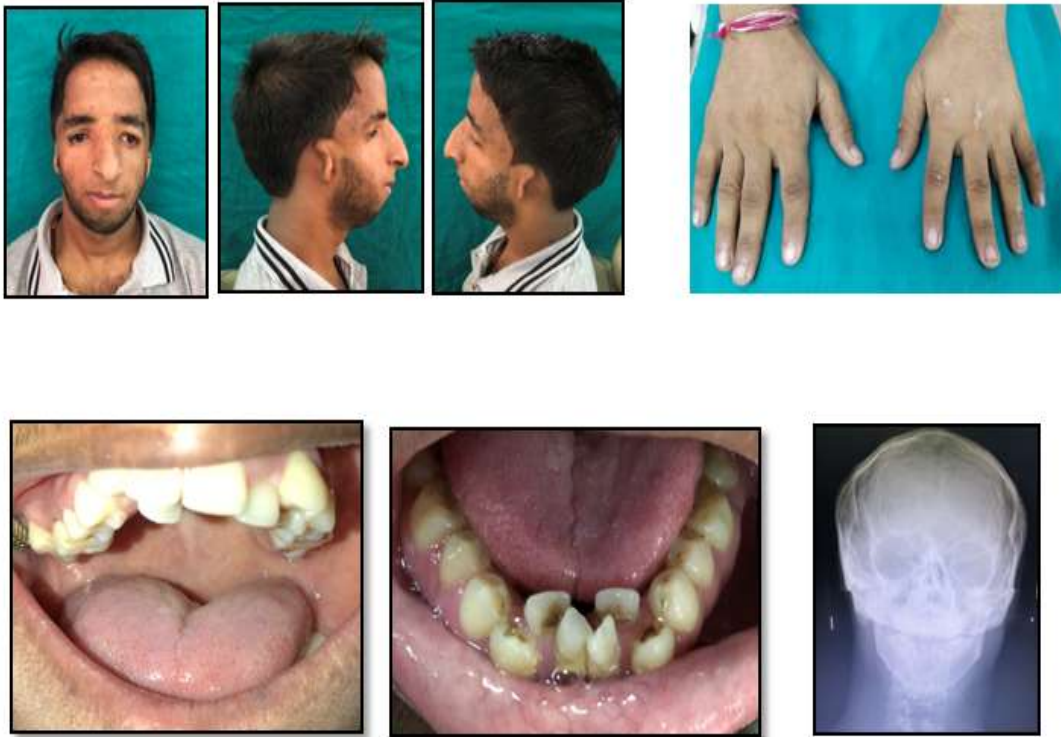I. INTRODUCTION

Treacher Collins Syndrome (TCS) or mandibulofacial dysostosis is an inherited and rare, autosomal dominant condition of craniofacial malformation with varying degrees of penetrance and expression. This term is also called "Berry's Syndrome" and "Franceschetti-Zwahlen-Klein" syndrome because of early recognition by Berry (1889), Treacher Collins (1900) and Franceschetti and Klein (1949). TCS is a result of interference in the development of the first and second branchial arches. An individual with TCS has a 50% chance of passing the syndrome to his or her child. The symptoms of TCS varies among the affected individuals, ranging from mild and therefore undiagnosed symptoms to severe facial involvement and life-threatening airway compromise. Craniofacial abnormalities tend to involve underdevelopment of the zygomatic complex, cheekbones, jaws, palate and mouth which can lead to breathing and feeding difficulties. In addition, affected individuals may also have malformations of the eyes including a downward slant of the opening

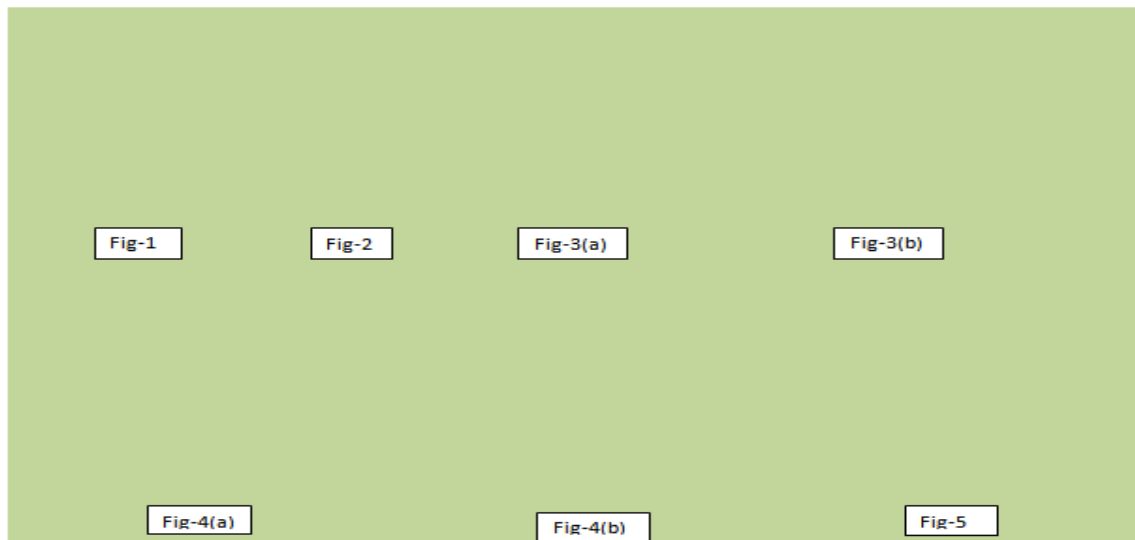
between the upper and lower eyelids (palpebral fissures) and anomalies of external and middle ear structures, which may result in hearing loss. Brain and behavioral anomalies such as microcephaly and psychomotor delay have also been occasionally reported as part of the condition. TCS is primarily caused by changes (mutations) in the TCOF1 gene, but is also associated with mutations in the POLR1B, POLR1C or POLR1D genes. In the case of TCOF1 and POLR1B, the mode of inheritance is autosomal dominant, while for POLR1C it is autosomal recessive. In contrast, both autosomal dominant and recessive mutations in POLR1D have been reported in association with TCS.

II. CASE REPORT

A 18 years old boy with a chief complaint of crowding in upper and lower jaws reported to the Oral medicine and radiology of SGT Dental College. He was born at full term in a healthy family, and the pregnancy of his mother was uncomplicated she had no history of any delinquent habit of alcohol, smoking, and drug abuse. The patient's facial appearance indicated a specific syndrome. On extra oral examination, hypoplasia of the facial bones such as small and malformed jaws, absent or undeveloped cheek bones as well as the floor and side wall of socket of the eye were noted. In addition, the lower jaw was slanting, and small and external ear anomalies, nasal deformity showing shrunken nose, eyes had sparse eyelashes with antimongloid slanting palpebral fissure and lower eyelids were detected. Intraoral examination revealed class 2 malocclusion, mild periodontitis due to poor oral hygiene (Figure 2).



On extraoral examination, the head was dolichocephalic with frontal bossing. Hypertelorism was present [Figure 1]. Ears were rudimentary with tags bilaterally. Maxilla, zygomatic bone, and mandible were hypoplastic, giving the child a "bird-like" appearance [Figure 2]. No evidence of webbing was noted in the hands and feet [Figure 3]a and b). Intraorally, clefting of hard and soft palate was not evident [Figure 4]a). The eruption pattern of the deciduous teeth seemed to be disturbed with the lower second molar erupting before the lower lateral incisor, canine and first molar [Figure 4]b). Posteroanterior (PA) view of skull was taken to confirm the development of orofacial structures. PA skull revealed hypoplastic maxilla and mandible with underdeveloped zygoma, suggestive of "copper beaten" appearance [Figure 5]. The child was referred to the Department of Otolaryngology to determine the hearing status of the patient. Conductive hearing loss was present bilaterally.



Panoramic radiographic examination indicated severe caries, but there were no lesions or abnormalities in the teeth or bones. The patient was then referred to an orthodontist on account of probable crowding due to micrognathia and normal size of permanent teeth. He was rescheduled to visit every three months, because of the high risk of caries[Figure:6]

The TCS maxillomandibular skeleton also has characteristic features. Overall, the facial profile in TCS is dramatically convex due to the pronounced retrognathia . In addition to being retruded, the mandible is often malformed altogether. The mandibular angle can be significantly underdeveloped and may be totally absent. There can be high antegonial notching and decreased height of the lower third of the face. Cephalometric studies

demonstrate that TCS patients have decreased sella-nasion-B point (SNB) angles and generally normal sella-nasion-A point (SNA). These features are further accentuated because of decreased posterior facial height and clockwise rotation of the occlusal plane. The most severe forms of TCS may have significantly deficient proximal mandible or even lacking the ramus/condyle unit altogether. A temporal-bone CT using thin slices makes it possible to diagnose the degree of stenosis and atresia of the external auditory canal, the status of the middle ear cavity, the absent or dysplastic and rudimentary ossicles, or inner ear abnormalities such as a deficient cochlea. Two- and three-dimensional CT reconstructions with VRT and bone and skin-surfacing are helpful for more accurate staging and the three-dimensional planning of mandibular and external ear reconstructive surgery[Figure:7].

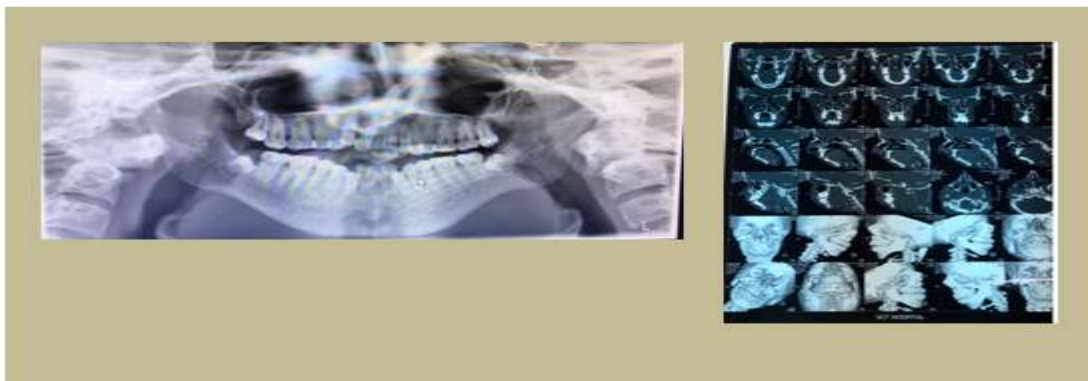

Figure 6 OPG

Figure 7 CT Scan



The patient's medical history was obtained from the parents and showed normal physical and dental development and intelligence quotient with no medical or systemic problems. Although there was no case of TCS in the family history, based on clinical and radiographic findings, the patient was diagnosed with TCS. This syndrome was distinguished from others like Miller, Nager and Goldenhar on the basis of 'bird like' or 'sunk-in' appearance, bilateral involvement of facial structures without limb or vertebral abnormalities, and epibulbar dermoids. After completely reviewing the patient's records and diagnosing the oral and dental problems, the treatment plan was devised. The parents were given instructions for oral hygiene and prophylaxis, fluoride therapy, anterior primary teeth extraction, pulpectomy of primary molars were performed. The patient was then referred to an orthodontist on account of probable crowding due to micrognathia and normal size of permanent teeth. He was rescheduled to visit every three months, because of the high risk of caries.

III. DISCUSSION AND REVIEW OF LITERATURE

TCS is caused by mutations in the TCOF1, POLR1C or POLR1D genes that affect facial development before birth. TCOF1 is located on chromosome 5 and encodes the treacle protein, and mutations in this gene account for 81% to 93% of all TCS cases. POLR1C and POLR1D gene mutations are responsible for 2% of the TCS cases. In individuals without an identified mutation in one of these genes, the genetic cause of the condition is unknown. Only 40% of the mutations are inherited, and the remaining 60% are de novo. The overall incidence of TCS is one in 50000 live births and affects both genders equally.

Most of the features of TCS are bilateral – meaning equally affecting both sides of body – and are already recognizable at birth, including hypoplasia of the facial bones (small and malformed jaw and malocclusion), external ear anomalies (inner ear malformations are rarely described) and conductive hearing loss, eye problems and loss of vision, strabismus, anisometropia, cleft palate, and airway problems which are often a result of mandibular hypoplasia and brachycephaly. Nasal deformities (large, beak-like nose with obstructed or small nasal passages), down-slanting eyes, few eyelashes, lower eyelid notching, eye abnormalities that might lead to loss of vision, high arched palate,

coloboma of the upper lid, ocular hypertelorism, choanal atresia, macrostomia, preauricular hair displacement, absent or underdeveloped cheekbones and the floor and side wall of the eye socket, lower jaw that is often slanting and small, unusual hairline with hair growing across the cheek like a sideburn, malformed or underdeveloped and or prominent ears, middle ear effects leading to loss of hearing in some cases, and very small or missing thumbs are some of the less frequent features of TCS.

Dental anomalies are seen in 60% of TCS patients, and consist of tooth agenesis (33%), enamel deformities (20%), and mal-positioned maxillary first molars (13%). In some cases, dental anomalies in combination with mandibular hypoplasia result in malocclusion which can lead to problems with food intake and the ability to close the mouth. In addition, speaking difficulties and other communication problems are also present. Children with this syndrome have normal intelligence and grow up to be functional adults with normal life spans. The best therapeutic outcomes are therefore achieved with early intervention. The OMENS classification was developed as a comprehensive and stage-based approach to classify the disorder into the complete (presenting all the known features), incomplete (less severe ear, eye, zygoma and mandibular abnormalities), abortive (only lower lid pseudo coloboma and zygomatic hypoplasia), unilateral (anomalies limited to only one side of the face), and the atypical (combined with other abnormalities not usually part of this syndrome) forms. Other diseases that have similar clinical features are acrofacial dysostosis, Nager syndrome, Miller syndrome, hemifacial microsomia and Goldenhar syndrome.

Our patient had a convex facial profile with a prominent dorsum of the nose above a retrusive lower jaw and chin. The eyes were characterized by an antimongoloid slant of the palpebral fissure resulting from coloboma and hypoplasia of the lower eyelids and lateral canthi, including partial absence of eyelid cilia. 'Tongue-shaped' processes of hair frequently extending into the pre-auricular region were observed. The external ears were malformed and malposed, and hearing was impaired. He presented the full expression of TCS with no familial history.

TCS is an example of an autosomal dominant syndrome with incomplete penetrance and variable manifestations. An affected parent of either sex will transmit the defect to 50% of his or her offspring in accordance with the Mendel's laws of



genetics. This emphasizes the importance of genetic counseling to individuals carrying relevant mutations. It is our responsibility as oral physicians to recognize this disorder and to provide close follow-up, appropriate therapy, and counseling. In addition, early diagnosis of TCS allows appropriate treatment of aesthetic and functional deficiencies in these patients. In fact, ameliorating the outward signs gives

these patients the opportunity to have an improved social life. Patients with severe form of TCS usually undergo multiple major reconstructive surgeries that are rarely fully corrective, and stem cell therapy is unlikely to benefit the reconstructive repair of severe craniofacial malformations. Consequently, more research should be directed on the preventive aspects of this syndrome.

S.NO	Writer(s)	Year of Study	Age (Years Old)	Sex	Clinical and Radiographic Features
1	Shapira et al	1996	7.5 yrs	Male	<ul style="list-style-type: none">• No family history• No consanguinity between the parents• The mother used paroxetine (antidepressant drug of the SSRI type) 20 mg daily during the whole pregnancy• He was considered to be small for gestational age• Triangular face• Long and thin hairs• Hypertelorism• Proptosis• Downslant palpebral fissures• Sparse eyelashes• Malar hypoplasia• Dysplastic, small and low-set ears• Atretic External auditory canals• Micrognathia• Unilateral choanal atresia• No abnormality in Chromosomal analysis• Normal visual ability• Bilateral hearing loss• Bilateral unpneumatized mastoid bones and stenotic external auditory canals• Pulmonary atresia, atrial septal defect, ventricular septal defect, and double-superior vena cava• On the 30th day of life, the baby had sudden cardiac arrest and died
2	Eduardo et al	2005	18	Female	<ul style="list-style-type: none">• Antimongoloid slanting of the palpebral fissures



					<ul style="list-style-type: none">• Malar hypoplasia of the zygomatic arch• Mandibular hypoplasia• Bilateral coloboma of the lower eyelids<ul style="list-style-type: none">• Malformations of auricular pinna• Communication deficit and standard school performance• Nasal obstruction• Mouth breathing• Anterior and posterior nasal septum deviation<ul style="list-style-type: none">• Bilateral choanal obstruction and choanal atresia
3	Kasat and Baldawa	2011	18 yrs	Female	<ul style="list-style-type: none">• Positive family history (father and grandmather)• Antimongloid slanting of the palpebral fissures with sparse eyelashes on the lower eyelid• Malar prominence hypoplasia<ul style="list-style-type: none">• Micrognathia (maxilla appeared to be prognathic)• 'Bird like' appearance• Narrow high arched palate<ul style="list-style-type: none">• proclination of maxillary incisors and there was spacing in the maxillary and mandibular anterior teeth• Prominent antigonial notch• Short ramus<ul style="list-style-type: none">• Hypoplasia of the mandible• Proclined upper anterior teeth• Steep occlusal plane• Hypoplasia of zygomatic bone and maxillary sinus
4	Kothari	2012	6 yrs	Male	<ul style="list-style-type: none">• Hypoplastic cheeks,zygomatic arches and mandible• Anti mongoloid slant to the eyes• Colobomas of outer canthus of eyes



					<ul style="list-style-type: none">• Small oral cavity & airway with normal sized tongue and difficulty in eating food• Concave lower border of mandible• Convex profile• Incompetent lip
5	Mohan et al.	2013	17 yrs	Female	<ul style="list-style-type: none">• No history of consanguineous marriage• Narrow face with mandibular hypoplasia along with prominent antgonial notch• Malar hypoplasia along with hypertrophy of both maxillary sinus walls• antimongoloid slant of eyes• Upper dentition to appear protruded• The nose to appear very prominent• Partial absence of lower eyelashes• Coloboma of lower lateral eyelid• Bilaterally External ear malformation in the form of a rudimentary pinna• Atresic canals of external ear• Absence of opening from the external to the internal ear• Conduction deafness with 50% reduction in hearing• Presence of a tongue-shaped process of hair on the lateral side of the face• Anterior open bite
6	Delin et al.	2014	Newborn	Male	<ul style="list-style-type: none">• No family history of congenital defects, especially facial anomaly• Without consanguinity between the parents• The mother used paroxetine (antidepressant drug of the SSRI type) 20 mg daily during the whole pregnancy• Triangular face with long



					<p>and thin hairs</p> <ul style="list-style-type: none">• Hypertelorism and proptosis• Downslant palpebral fissures• Malar hypoplasia• Sparse eyelashes• Dysplastic, small and low-set ears• External auditory atretic canals• Micrognathia• Unilateral choanal atresia• Bilateral hearing loss• Bilateral unpneumatized mastoid bones and stenotic external auditory canals• Pulmonary atresia, atrial septal defect, ventricular septal defect, and double-superior vena cava• On the 30th day of life, the baby had sudden cardiac arrest, and did not respond to resuscitation
7	Renju et al.	2014	10 yrs	Female	<ul style="list-style-type: none">• Positive family history (The child's father also had similar phenotypic features like antimongoloid palpebral fissures; deficient malar prominence and anterior open bite)• Downward slanting of eyes• Depressed zygomatic arches• Sunken cheekbones• Deformed external ears• Coloboma of lower eyelid• Retruded chin giving (bird-like appearance)• Deviated nasal septum• Limited mouth opening (18 mm)• The path of closure was deviated to the right side• Class III molar relationship with anterior open bite• Crowding of maxillary and mandibular anterior



					<p>teeth</p> <ul style="list-style-type: none">• High arched palate with submucosal cleft• With mouth breathing and tongue thrusting• Low birth weight, frequent episodes of fever during childhood and delayed speech• Underdeveloped condylar and coronoid processes, hypoplastic zygomatic arches and short rami• Difficulties in swallowing and hearing and impaired vision• Absence of middle ear on the right side and conductive hearing loss• Reduced anterior cranial base length• Decreased the ramal height and mandibular length
8	Sharma et al.	2016	1 Month	Male	<ul style="list-style-type: none">• The first child of a 22-year-old with non consanguinous marriage• No family history• Hearing deficit as he did not turn his head to sound• There was a history of delayed crying at birth• The skull was normal except for an open anterior fontanelle• Bilaterally symmetrical but abnormal face characteristics• downwardslanting eyes• Malar hypoplasia• Mandibular hypoplasia (micrognathia)• A large fishlike mouth (macrostomia) with a high arched palate• Retropositioned tongue but no difficulty in feeding and swallowing• Malformed and crumpled bilateral pinnae• Right external auditory canal stenosis and left



					<p>external auditory canal atresia</p> <ul style="list-style-type: none">• Pectus carinatum and chest indrawing• Vesicular breath sounds with prolonged expiration• Scaphoid abdomen• Antimongoloid slant of the palpebral fissures• Bilateral lower lid coloboma (lateral one third) with absence of eyelashes in the entire extent of the lower lids• Congested inferior conjunctiva in both eyes with superficial haze of the inferior cornea(exposure keratopathy).• Normal pupils in size with normal reaction to light• Bilateral lower lid coloboma with exposure keratopathy
9	Gopal S	2016	18yrs	Female	<ul style="list-style-type: none">• With history of surgical correction of cleft palate when she was 3 years of age• Asymmetry on left side of the face• Increased inter-canthal distance• Frontal bossing• Deficient/hypoplastic malar bones• Prognathic anterior maxilla• Short upper lip and incompetent lips• Absence of mental groove and retrognathic mandible• Deviation of nasal septum towards left side• Deformity of the left ear with absence o left auditory canal, resulting in loss of hearing ability in the Left ear• High arch palate with evidence of scar



					<ul style="list-style-type: none">• All the permanent teeth were fully erupted with multiple dental caries and andgeneralized enamel hypoplasia• Crowding of lower anterior teeth• Deformed uvula with the bifid morphology (under developed in the left side).• Prominent antigonial notch on the left side• Short ramus• retrognathic mandible• Hypoplasia of the left side of mandible and zygomatic bone• Proclined upper anterior teeth
10	Panta et al	2017	13yrs	Male	<ul style="list-style-type: none">• Absence of consanguineous marriage• Normal three siblings• No family history• Downward obliquity palpebral fissures (antimongoloid slants)• Partially absence of lower eyelashes• Flattening of Temporo-parietal on left side• Mandible hypoplasia• Protruding upper dentition• Bilateral zygomatic and malar hypoplasia• Narrow facial dimension and bird like-appearance to the face• The external ears malformation• Partial hearing loss (conductive type)• A classic hair growth pattern on the cheek region on both sides• Prominent antimongloid notch• Elevated ramus-body angle and short ramus• Dipping on right side and loss of glenoid fossa architecture and small



					condyle on both sides
--	--	--	--	--	-----------------------

REFERENCES

- [1]. Andrade E C, Júnior VS , Didoni ALS, Freitas P Z, Carneiro AF, Yoshimoto FR. Treacher Collins syndrome with choanal atresia: a case report and review of disease features. *Rev. Bras. Otorrinolaringol.* 2005; 71(1):107-10. [DOI:10.1016/S1808-8694(15)31296-9]
- [2]. Kothari P. Treacher Collins Syndrome: A case report. *WebmedCentral DENTISTRY.* 2012; 3(1):WMC002902. [DOI: 10.9754/journal.wmc.2012.002902]
- [3]. Mohan RPS, Verma S, Agarwal N, Singh U. Treacher Collins syndrome: A case report. *BMJ Case Reports.* 2013. [DOI:10.1136/bcr-2013-009341]
- [4]. Reena Sharma, Brahmadeo Sharma, Meenu Babber, Sonali Singh, Gunjan Jain. Treacher Collins syndrome: A case report and review of ophthalmic features. *Taiwan Journal of Ophthalmology.* 2016; 6(4):206-9. [DOI:10.1016/j.tjo.2016.07.002]
- [5]. Gopal S, Kshatri JKS, Ramesh K. Treacher Collin Syndrome: A Clinical Case Report. *International Journal of Research* 2016; 8(5):31814-7.
- [6]. Panta P, Yaga US, Mengji A K, Radhika B, Swetha Rao M. Treacher Collins Syndrome - Case Report and Review. *Oral Health and Dental Management.* 2017; 16(1):1-3.
- [7]. Goel L, Bennur SK, Jambhale S . Treacher Collins Syndrome-A Challenge For Anaesthesiologists. *Indian Journal of Anaesthesia.* 2009; 53(4):496-500. [PMCID]
- [8]. Evans AK , Rahbar R , Rogers GF , Mulliken JB , Volk MS. Robin sequence: A retrospective review of 115 patients. *International Journal of Pediatric Otorhinolaryngology* 2006; 70(6):973-80. [DOI:10.1016/j.ijporl.2005.10.016]