



Versatility of Nasolabial Flaps in Oral Cancer Reconstruction

Dr Jahnavi Arumulla¹, Dr Ravi Naga Vijay Kumar², Dr S. Najma³

Submitted: 01-08-2022

Accepted: 07-08-2022

ABSTRACT:

Background: To study the versatility of nasolabial flap in reconstruction of oral cavity defects.

Materials and Methods: 100 patients in whom this flap was used for reconstruction were analysed.

Conclusion: The nasolabial flap is a versatile flap and can be used to cover medium and large defects and can be a substitute for other major reconstructive options with reduced cosmesis comparatively.

Keywords: Nasolabial flap, oral cancer defects.

I. INTRODUCTION

The 21st century has heralded a tremendous growth of industrialization and urbanization which has, by all odds, raised the standard of life in the recent times. Oral cancers are the sixth most common cancers in the world¹. Surgery is the initial treatment of choice for all squamous cell carcinomas of oral cavity. A variety of regional cutaneous and myocutaneous flaps from various donor sites are available and of course in complex defects micro vascular free tissue transfer is a well accepted surgical option as they give the best aesthetic outcome. In countries like India, where there is excessive case load, resource constraints and poor economic background of the population it may not be feasible to reconstruct the defects with micro vascular free tissue flaps for all patients. There are many local and regional flaps which are described in literature and are in practice⁴. This study aims at showing the versatility of nasolabial flaps in these reconstructions.

II. MATERIAL AND METHODS

A Prospective, observational, analytical study was conducted from May 2015 to March 2017, enrolling the cases which fit into the inclusion criteria.

Inclusion Criteria :

- All patients 18 year or older.
- Both Unilateral and Bilateral Nasolabial flap reconstruction patients
- Patients with single stage and two stage procedures.
- Patients who are willing to give consent to participate in the study.

Exclusion Criteria :

- The patients with Cancers other than Oral cavity.
- The patients with Acute or chronic lesions of oral cavity.
- The Patients who lost follow up atleast for 6 months

Sample Size : 100 patients

Methodology : A prospective, observational, analytical study was performed using data from patient medical records, including data on underlying pathology, defect size and location, surgical technique of flap harvesting. Informed consent was taken from all the patients meeting inclusion criteria.

Intraoperative Technique Adapted:

- Factors which we have taken into account are
 - For base:
 - By the location of defect
 - Superior defects : superior based
 - Inferior defects : inferior based.
 - Variant of flap
 - Remnant thickness of cheek
 - Location of tumor :
 - Superior based flaps are always pedicled (two staged).
 - Inferior based flaps are either islanded, transposed or pedicled(two staged).
 - Dimensions of flap :
 - Size of defect.
- The incision is made all around except at the base of flap irrespective of the variant of the flap.
- The flap is lifted from tip to the base in the plane above the facial muscles.
- Once the flap attains the desired length, the incision at the base is taken, if an island variant is planned. In the other two variants, this step is not done.
- An opening is created into the oral cavity through the buccal space and flap is tunnelled in.
- Suturing begins at the tip and then it is progressed towards the base with one superior and one inferior stitch respectively.
- The external skin defect is closed in two layers.



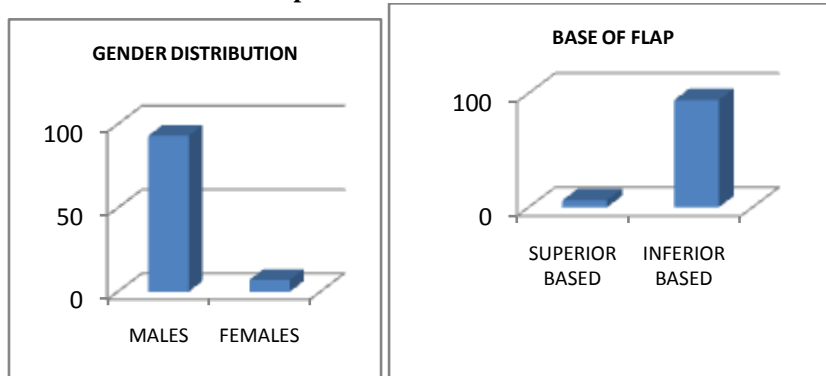
- 8) The timing for division and inset of flap is dependent mainly on whether the patient is requiring adjuvant radiation or not.
- 9) If the patient required no adjuvant therapy, then the division as early as 3 weeks.
- 10) If the patient received adjuvant radiation therapy then the closure of the fistula is

deferred to 6 months after completion of radiation.

- **Postoperative :** The patients are evaluated for post operative healing, complications, starting of the oral feed, improvement of mouth opening.

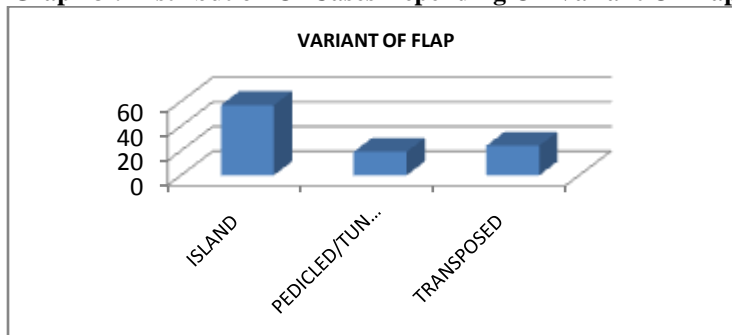
III. OBSERVATION AND DATA ANALYSIS:

Graph 1 : Gender Distribution

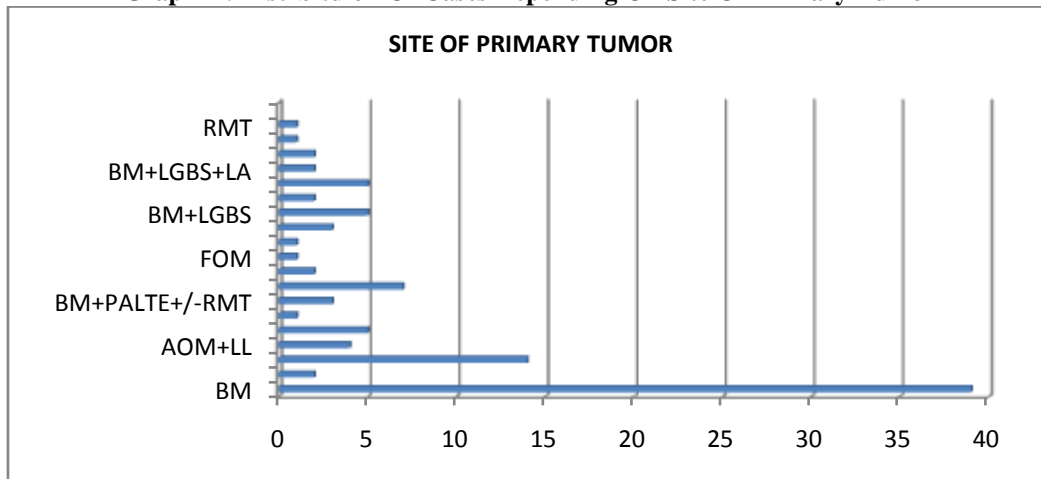


Graph 2 : Distribution Of Cases Depending On Base Of Flap

Graph 3 : Distribution Of Cases Depending On Variant Of Flap

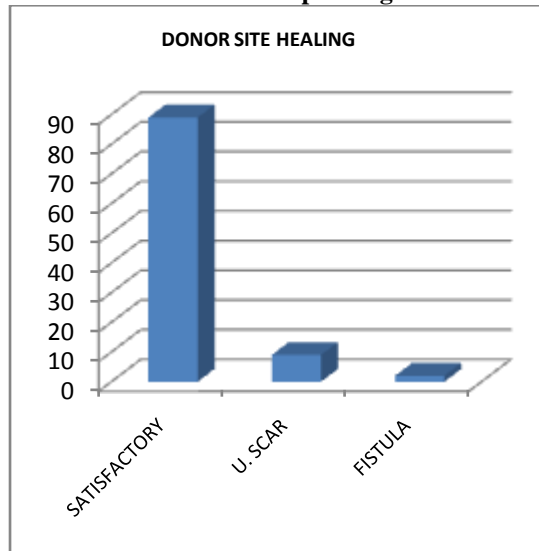


Graph 4 : Distrbituion Of Cases Depending On Site Of Primary Tumor

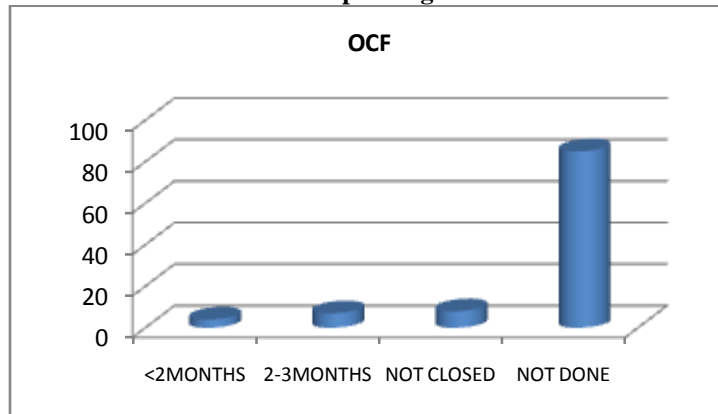




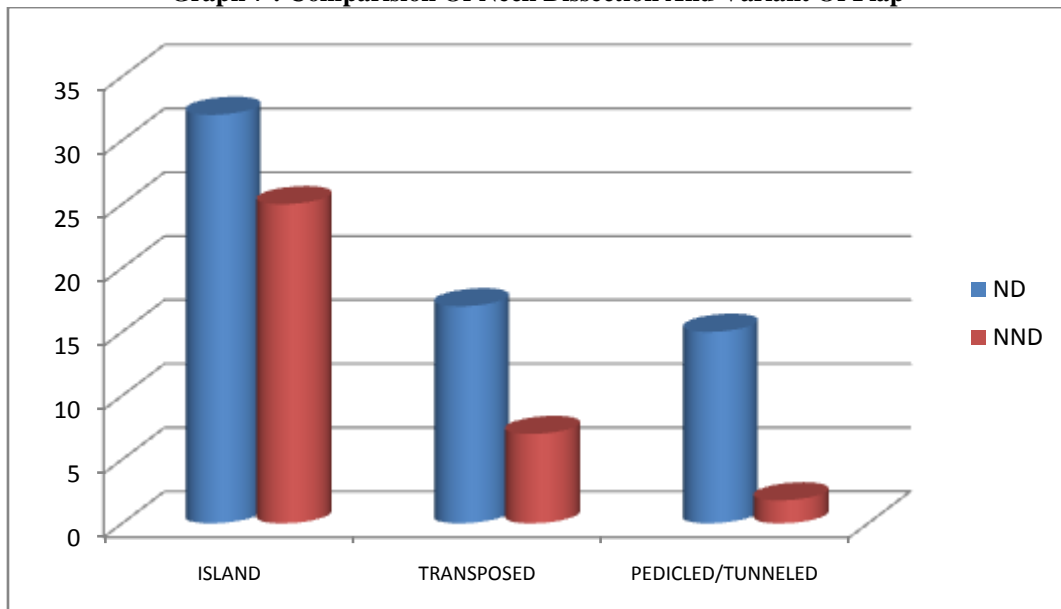
Graph 5 : Distrbituion Of Cases Depending On Donor Site Healing



Graph 6 : Distrbituion Of Cases Depending On The Time OF OCF Closure



Graph 7 : Comparision Of Neck Dissection And Variant Of Flap





Complications

- 1) Necrosis
- 2) Dehiscence
- 3) Oral incompetence

IV. DISCUSSION

Oral and oro-pharyngeal carcinomas are the sixth most common cancers in the world. This study is conducted in the period between 1st May 2015 and 30th April 2017, enrolling the patients who are amenable for a reconstructive procedure by nasolabial flap. A total of 100 patients were taken out of which 93 are men and 7 are women. The preponderance of male cases is likely due to the prevalence of tobacco addiction in male population.

94% of the nasolabial flaps were inferiorly based which can be explained by the fact that most of the cases were either buccal mucosa or lower gingivobuccal sulcus or lower alveolus lesions. Most of the Nasolabial flaps are island (single stage), while the rest are either transposed or pedicled (two staged) type.

The dimensions which were harvested ranged from a minimum of 4 cm in length x 2 cm width at the base to a maximum of 7 cm length x 4 cm width at base. The inset of the flap was most commonly into the buccal mucosa. In case of lower gingivobuccal sulcus lesion with or without marginal mandibulectomy, the floor of mouth is advanced over the bone and sutured to the flap.

Most of the lesions were T2, less common were T1 and T4, and the least common lesions were T3 in our study. The reason for a lesser T3 cases can be attributed to the fact that the lesions which are clinically T3 were found to be pathologically T2 or T4.

The versatility of the flap is shown by that it was used to cover a wide range of defects.

Post operative feeding was started as early as zero day in few patients to as late as 4th post operative day. 47% patients were started with sips of oral fluids from 1st POD, 41% on POD2. Ryles tube was removed as the patients are comfortable with oral sips for one continuous day. 70% of the patients were rid of ryles tube feeding by day 2 or 3.

Neck was addressed in 64% of patients and in 36% it was observed.

Out of the 64 patients who underwent neck dissection, the facial artery was ligated in 62 patients and was preserved in 2 patients. Out of the preserved patients one patient developed partial necrosis, for unknown reasons.

Two patients had a total dehiscence, one of which was due to total necrosis. The other was due to a tight closure in a RMT and tonsil lesion.

Only four flaps have undergone necrosis, one of which has undergone a complete necrosis, the rest were necrosed partially.

Donor site healing was satisfactory at the end of 6 months of followup in about 89% of patients. 9 patients have developed hypertrophic scar and two patients have developed fistula which healed subsequently by the end of 6 months.

67% of patients had 3 finger mouth opening before surgery which improved to 71% at the end of 6 months. This did not have any statistical significance to show that the flap had a role in mouth opening. The probable explanation would be because of the submucous fibrosis on opposite side.

Comparison With Other Studies :

Study	Type Of Flap	Site Of Usage
Ducic Et Al (2000)	Pedicled Flap	Versatile
Varghese Et Al (2001)	Superior And Inferior Flaps	Tongue And Selected Other Areas
Napolitano Et Al (2001)	---	Floor Of Mouth
Joshi Et Al (2005)	---	Palate, Alveolus, Lip, Floor Of Mouth
Rudkin Et Al (2003)	---	Lower Lip
El Marakby Et Al (2005)	---	Anterior Floor Of Mouth, Lip
Imran Saeed (2011)	---	Anterior Tongue
El Marakby Et Al (2012)	Single Stage, Inferior Based, Facial Ligated	Medium Defects Of Oral Cavity - - Versatile
Ngian-Chye Tan	Transposed	Large Lip Defects Good Functional And Esthetic Outcome
Arshad Hakeem (2016)	Inferior Based	Large Lip Defects



Present Study	All Variants, All Types, +/- Facial Ligated.	Versatile (Except Tongue)
---------------	--	---------------------------

In comparison with other studies, the present study also shows that the nasolabial flap is a versatile flap and can be used to cover medium and large defects and can be a substitute for other major reconstructive options with reduced cosmesis comparatively. This flap gives good aesthetic results in lip reconstructions.

As mentioned in El Marakby study, this study also shows that facial artery ligation doesnot cause hindrance to the flap viability and can be securely ligated during neck dissections or surgery for the primary tumor.

As mentioned by Joshi et al, this study also shows that this flap can be used for palate and alveolus defects.

V. CONCLUSIONS AND SUMMARY

The nasolabial flap is proven advantageous due to following reasons :

- 1) Versatility.
- 2) Less harvest and inset time.
- 3) Utilises minimum resources.
- 4) Easy learning curve.
- 5) Least complication rate.
- 6) Minimised cost.
- 7) Minimised hospital stay.
- 8) Faster healing which translates to earlier start of adjuvant therapy.
- 9) Options of other flaps are still open.

The disadvantages which were noticed are :

- 1) Inscion and scar on face.
- 2) Couldnot give the required bulk translating to compromised cosmesis.
- 3) Orocutaneous fistula in pedicled(two staged) flaps, requiring a second procedure to close.
- 4) Commissuroplasty required for angle of mouth reconstructions.

REFERENCES

- [1]. Hussain Gadelkarim Ahmed, Saadalnour Abusail Mustafa, and Eyman Warille, "Human papilloma virus attributable head and neck cancer in the sudan assessed by p16ink4a immunostaining," Asian Pacific Journal of Cancer Prevention, vol. 13, no. 12, pp. 6083–6086, 2012.
- [2]. Misra S, Chaturvedi A, Misra N. Management of Gingivobuccal Complex Cancer. Annals of The Royal College of Surgeons of England. 2008;90(7):546-553. doi:10.1308/003588408X301136.
- [3]. Urken, M. L. et al. "Microvascular Free Flaps In Head And Neck Reconstruction: Report Of 200 Cases And Review Of Complications". N.p., 2017.
- [4]. SR B. Regional flaps in facial reconstruction. - PubMed - NCBI [Internet]. Ncbi.nlm.nih.gov. 2017 [cited 24 April 2017]. Available from: <https://www.ncbi.nlm.nih.gov/pubmed/2259510>
- [5]. Bailey BJ. Head and Neck Surgery-Otolaryngology. 2nd ed. Philadelphia, Pa: Lippincott- Raven; 1998. 1510.
- [6]. Joshi D, Bhatia D. Cross-correlation evaluated muscle co-ordination for speech production. J Med Eng Technol. 2013 Oct 17.
- [7]. Ducic Y, Burye M. Nasolabial flap reconstruction of oral cavity defects: A report of 18 cases. J Oral Maxillofac Surg. 2000;58:1104–8.
- [8]. Varghese BT, Sebastian P, Cherian T, Mohan PM, Ahmed I, Koshy CM, et al. Nasolabial flaps in oral reconstruction: An analysis of 224 cases. Br J Plast Surg. 2001;54:499–503.
- [9]. Napolitano M, Mast BA. The nasolabial flap revisited as an adjunct to floor-of-mouth reconstruction. Ann Plast Surg. 2001;46:265–8
- [10]. Joshi A, RajendraPrasad J. Reconstruction of intraoral defects using facial artery musculomucosal flap. British Journal Of Plastic Surgery. 2005;58(8):1061-6.
- [11]. El-Marakby H. The versatile naso-labial flaps in facial reconstruction. Journal Of The Egyptian National Cancer Institute. 2005;17(4):245-50.
- [12]. El-Marakby H, Fouad F. One stage reconstruction of the floor of the mouth with a subcutaneous pedicled nasolabial flap. Journal Of Egyptian National Cancer Institute. 2012;24(2):71-6.
- [13]. Hakeem, A.H., Hakeem, I.H. & Wani, F.J. Eur J Plast Surg (2016) 39: 187. doi:10.1007/s00238-015-1162-6
- [14]. Yadav P. Reconstructive surgery in oral cancers. Indian J Plast Surg [serial online] 2007 [cited 2017May2];40,SupplS1:22-7. <http://www.ijps.org/text.asp?2007/40/12/2/36855>