



A Case Of Intracholecystic Papillary Neoplasm Associated Invasive Carcinoma Gallbladder - A Case Report

Dr.Thiyagaraj Lakshmi Seshadri.M^{3*}, Dr.V.Kopperundevi¹, Dr.G.Vimala²,
Dr.R.Kannan⁴

Institute of General Surgery, RGGGH & MMC, Chennai 03, Tamilnadu, India.

Institute of General Surgery, RGGGH & MMC, Chennai 03, Tamilnadu, India.

Institute of General Surgery, RGGGH & MMC, Chennai 03, Tamilnadu, India.

Institute of General Surgery, RGGGH & MMC, Chennai 03, Tamilnadu, India.

Submitted: 15-04-2022

Accepted: 30-04-2022

ABSTRACT:

Intracholecystic papillary neoplasm (ICPN) is a precursor lesion of gall bladder carcinoma. Gall bladder carcinoma arising from intracholecystic papillary neoplasm is comparatively less common. Hereby we present a case of gall bladder polyp/mass diagnosed to be a invasive carcinoma gallbladder arising from intracholecystic papillary neoplasm. Patient presented with right hypochondriac pain diagnosed to have gallbladder polyp/mass without nodal involvement and hepatic infiltration. There was no associated gallstones. The staging laparoscopy was negative. Open simple cholecystectomy with fresh frozen section revealed intracholecystic papillary neoplasm. Following histopathological examination could pickup an additional invasive component leading to upstaging of the tumor. This disparity between the fresh frozen section and histopathology created a need for additional investigations. PET-CT revealed prominent peri-portal and peri-hepatic nodes without increased metabolic activity. Completion radical cholecystectomy showed no evidence of the lymph node metastasis nor hepatic infiltration. Patient recovered uneventfully.

Key words : Intracholecystic papillary neoplasm, carcinoma gallbladder, ICPN, Invasive carcinoma, carcinoma insitu, gallbladder mass, gallbladder polyp.

I. INTRODUCTION :

ICPN is a grossly visible, mass forming, non invasive tumor arising from the gallbladder mucosal epithelium. It is usually a polypoidal lesion. When a invasive component is associated the lesion is called as ICPN with associated invasive component and is classified as per ICD-O coding under 8503/3 as separate entity. (1) ICPN is more common in female than male.(2)The mean age of presentation is 61 years.(2)While most of

them are incidentally detected, the most common presentation in a symptomatic patient is right upper quadrant pain.(2, 3) ICPN is reported less than 1 percent of cholecystectomy specimens. (4,5)Nearly 6 % of invasive gallbladder carcinoma arise from ICPN as a precursor lesion. (2)Unlike carcinoma gallbladder, ICPN is not known to be associated with gall stones . Macroscopically ICPN is a granular, friable, exophytic growth with broad base resembling a polyp with a median size of 2.2cm. They may be multifocal. Microscopically ICPN shows intra luminal growth with back to back epithelium units in papillary configuration. Adjacent mucosa may show varying degrees of cytoarchitectural atypia - depending upon which they are further classified into low grade and high grade (ICD - 0 8503/0 and 8503/2 respectively). If an associated invasive component is identified, they are classified as ICPN with associated invasive component.(2, 5) This invasive component may be far away from ICPN and thorough search has to be made. In TNM staging, ICPN with high grade dyplasia is considered as pTis whereas ICPN with associated invasive component is considered as pT1-4 depending on depth of invasion of gallbladder wall.(6)The 5 year survival after ICPN without invasion is 78% and ICPN with invasive component is 60% respectively. The overall outcome ICPN with invasive carcinoma is far better than conventional gall bladder carcinoma that arises denovo. (2)

II. CASE REPORT:

History :

A 54 year old female presented with complaints of progressive, intermittent, dull aching, post-prandial, non radiating pain in right hypochondrium for past 2 month. No other significant complaints such as dyspepsia, vomiting, jaundice, steatorrhoea, weight loss. No other



significant past history, family history and prior surgery. She known to have type 2 diabetes mellitus without other co-morbidities was on oral hypoglycaemic agent Tab.Metformin / Tab.Glimepride for 2 years. She had a preference to fatty diet- non vegetarian meal and had no history of substance abuse or drug allergy.

Examination:

Patient was conscious, oriented, comfortable at rest, afebrile, no pallor, not icteric, Eastern Cooperative Oncology Group score 0, BMI 28 kg/m².

Vitals

Blood pressure - 140/90 mm hg, pulse - 92/ min, temperature - normal, respiratory rate- 16/min. , ,

Per abdomen :

Inspection : within normal limits

Palpation : soft, non tender, hepatomegaly present, no evidence of any other mass or organomegaly.

Percussion :no free fluid, liver span 18cm.

Auscultation: bowel sounds present

Digital rectal examination normal

Investigations :

Ultrasonogram of abdomen revealed a 2.5 x 3 cm heteroechoic mass in fundus of gallbladder. Contrast enhanced tomography with triple phase protocol revealed a irregular,well defined, intraluminal, soft tissue attenuating lesion of 2.5 x 3.2 cm in the fundus and body of the gallbladder.Magnetic Resonance Cholangio Pancreatogram revealed well defined,irregular, T1 and T2 hypointense lesion arising from the fundus and body of gall bladder of 3.4 cm anteroposterior x 2.5 cm transverse x 3.2 cm craniocaudal.No evidence of associated gallstones, intra hepatic biliary radical dilation, hepatic infiltration, peri hepatic/ peri choledochal nodes, hepatic metastasis could be made out radiologically. Upper Gastrointestinal endoscopy was normal.CEA and CA 19-9 was normal. Complete hemogram, coagulation profile renal and liver function test are within normal limits.

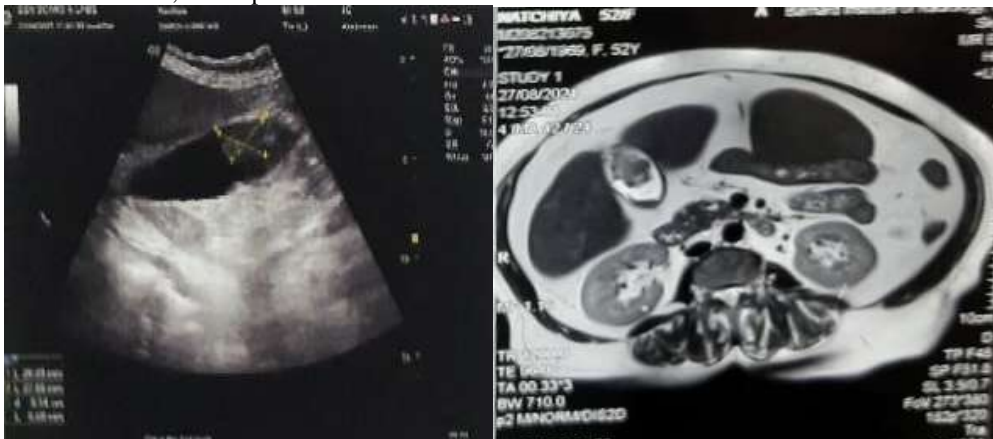

Figure 1a: Ultrasonogram showing a heteroechoic mass in fundus of gallbladder. 1b: Magnetic Resonance Cholangio Pancreatogram showing mass arising from the fundus and body of gall bladder.

Operative procedure:

Staging laparoscopy showed no evidence of peritoneal, hepatic metastasis or gallbladder serosal breach. Gall bladder removed in-toto without rupture by open simple cholecystectomy. Fresh frozen section showed non-invasive intracholecystic papillary neoplasm at the fundus and body of gall bladder with normal cystic duct margins. Tumor was staged as pTis, so further gall bladder fossa resection and nodal clearance was deferred. Patient course in postoperative period is uneventful. Thorough histopathological examination following the surgery showed adjacent areas of invasive component infiltrating the muscularis propria. Tumour was diagnosed as intracholecystic papillary neoplasm with invasive

carcinoma (Gross: intraluminal, polypoidal, granular, friable, lesion of size 2.5 cm x 3.5 cm. Microscopy : neoplastic cells arranged in papillary forms with central fibrovascular core lined by columnar epithelium, moderate eosinophilic cytoplasm, prominent nucleoli and associated with malignant glands infiltrating into muscularis propria. Cystic duct margins free). This lead to upstaging of the tumor as T1b postoperatively and warranted further evaluation and treatment. Following positron emission tomography revealed prominent periportal nodes and pericholedochal nodes without any abnormal metabolic activity suggesting postoperative changes or micro metastasis. No other metabolically active disease found elsewhere. Completion radical

cholecystectomy done to remove gallbladder bladder fossa and periportal, pericholedochal, retroduodenal and aortocaval nodes which showed

no evidence of hepatic infiltration or nodal metastasis. Postoperative period was uneventful.

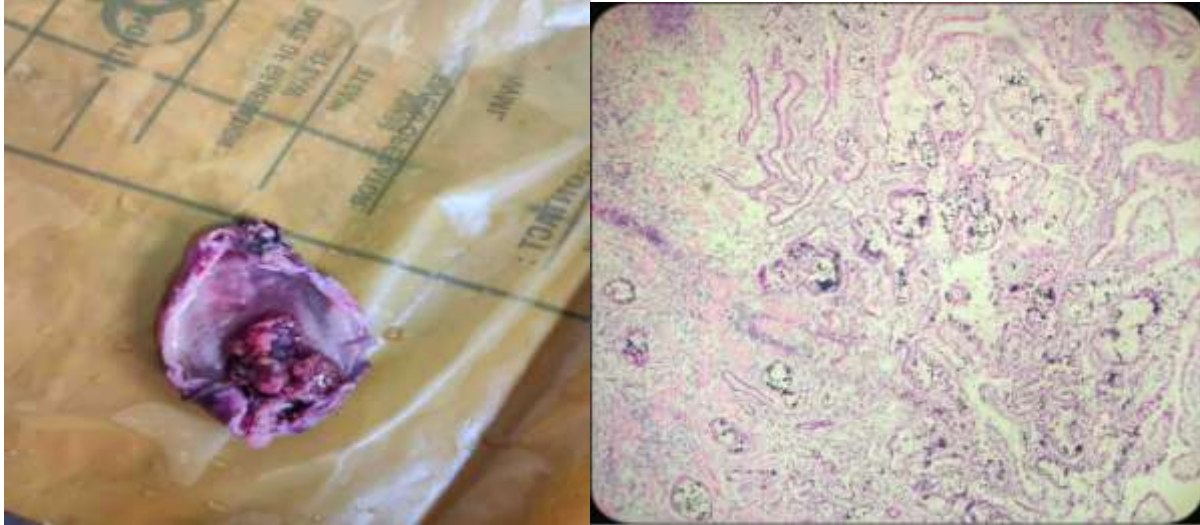


Figure 2a: Gross view of a polypoidal mass in fundus of the gallbladder.2b: Fresh frozen section showing a low power view of intracholecystic papillary neoplasm.

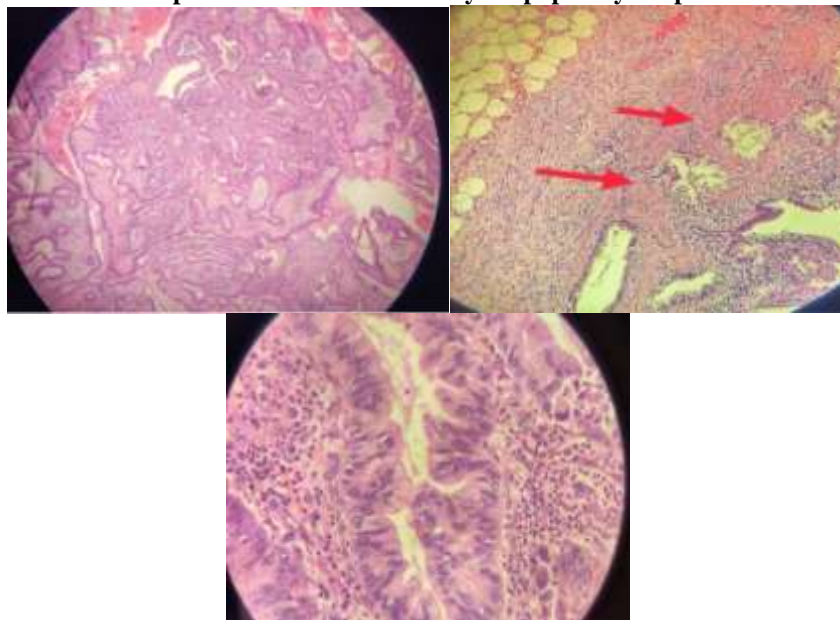


Figure 3: Post operative histopathological examination showing low power view of the intracholecystic papillary neoplasm 3a, invasion into muscle 3b, high power of papillary architecture 3c.

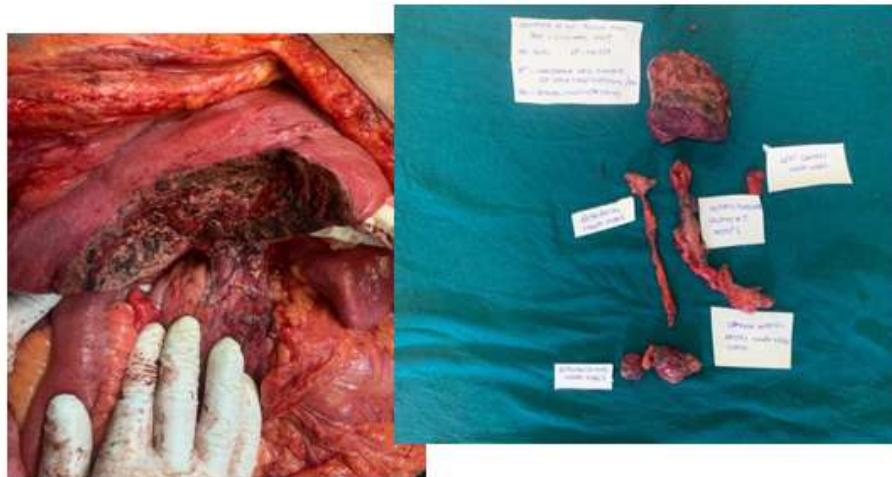

Figure 4a: intraoperative picture after completion radical cholecystectomy, 4b specimen showing resection liver and lymph nodes.

Follow up and outcomes

Patient is now being followed for 6 months. No evidence of local or distant metastasis could be found till now.

III. DISCUSSION:

ICPN was first described in 2010 WHO classification. Histopathology four sub types exist namely biliary, gastric, intestinal and oncocytic type. They are usually a intra-luminal polypoidal lesion of more than 1cm. So it is wise to suspect a malignancy preoperatively, if the size of gall bladder poly is more than 1 cm. (7)patients are mostly asymptomatic and are detected radiologically as a incidental finding. Unlike conventional gall bladder carcinoma, there are no know etiology or associated risk factor in ICPN associated gallbladder carcinomas. Multifocal nature of ICPN, detection of invasive component at site far away from the insitu lesion, simultaneous detection of intracholecystic and intraductal papillary neoplasm in some patients, associated of ICPN with abnormal pancreaticobiliary maljunction, choledochal cyst, detection of invasive biliary cancer long time after surgery for ICPN may suggest a field cancerisation effect.(8,9)This nature of ICPN warrens a need for follow up and active surveillance protocol to detect second malignancy earlier.

Granular and friable nature of the ICPN may lead to detachment of the lesion from the gallbladder bladder wall and could be mistaken for gallbladder sludge which could go unnoticed. Hence minimal manipulation with careful attention to the intra luminal content is critical.(10)Several issues and challenges that are to be addressed

during histopathological examination and pathological staging includes failure to identify a invasive component associated with ICPN leading to inadvertent under-staging thereby under treatment of the neoplasm, inapparent nature of gallbladder carcinoma (detection of invasive lesion in clinically and grossly unsuspected gallbladders), need to differentiate invasion from Rokitansky - Aschoff sinuses and practical difficulties in sub staging T1a,T1b due to hardships in identifying distinct layers of gall bladder. Hence establishing distinct layers of gall bladder. Hence establishing proper grossing protocols with adequate sampling are critical while staging these pancreatobiliary neoplasms.(6)The frozen section examination is not always fool proof and has been reported to have a low accuracy for detection of malignancy in polypoidal lesion than non polypoidal lesion.The accuracy of frozen section diagnosis was 91% (93% for benign; 89% for malignant). In 54 nonpolypoid lesions, the accuracy of diagnosis was 98% (100% for benign; 93% for malignant).(11) The overall outcome and 5 year survival is good for ICPN associated invasion carcinoma when compared to the conventional gall bladder carcinoma suggesting the indolent nature of neoplasm.

IV. CONCLUSION:

High index of suspicion is need for detection ICPN associated invasive carcinoma. Patients who are found to have a invasive component in their cholecystectomy specimens following negative frozen section should undergo restaging and in absence of contraindications, completion radical resection for hepatic and nodal clearance should be performed as soon as possible.



Consent from patient : Obtained.
Conflict of interest : None.
Ethical Committee Approval : Not required.
Funding : Nil.

Abbreviations:

T2DM - Type 2 Diabetes Mellitus
SHTN - Systemic Hypertension
BA - Bronchial Asthma
PRBC - Packed Red Blood Cells
CT - Computed Tomography
eFAST - extended Focused Assessment with Sonography in Trauma
BP - Blood Pressure
PR - Pulse Rate
RR - Respiratory Rate

REFERENCES :

- [1]. Gonzalez RS. WHO classification. PathologyOutlines.com website. <https://www.pathologyoutlines.com/topic/gallbladderwhoclassification.html>. Accessed February 18th, 2022.
- [2]. Adsay V, Jang KT, Roa JC, Dursun N, Ohike N, Bagci P, Basturk O, Bandyopadhyay S, Cheng JD, Sarmiento JM, Escalona OT, Goodman M, Kong SY, Terry P. Intracholecystic papillary-tubular neoplasms (ICPN) of the gallbladder (neoplastic polyps, adenomas, and papillary neoplasms that are ≥ 1.0 cm): clinicopathologic and immunohistochemical analysis of 123 cases. *Am J Surg Pathol*. 2012 Sep;36(9):1279-301. doi: 10.1097/PAS.0b013e318262787c. PMID: 22895264.
- [3]. Bennett S, Marginean EC, Paquin-Gobeil M, Wasserman J, Weaver J, Mimeault R, Balaa FK, Martel G. Clinical and pathological features of intraductal papillary neoplasm of the biliary tract and gallbladder. *HPB (Oxford)*. 2015 Sep;17(9):811-8. doi: 10.1111/hpb.12460. PMID: 26278323; PMCID: PMC4557656.
- [4]. Argon A, Barbet FY, Nart D. The Relationship Between Intracholecystic Papillary-Tubular Neoplasms and Invasive Carcinoma of the Gallbladder. *Int J Surg Pathol*. 2016 Sep;24(6):504-11. doi: 10.1177/1066896916644781. Epub 2016 Apr 27. PMID: 27122163.
- [5]. Kiruthiga KG, Kodiatte TA, Burad D, Kurian R, Raju RS, Rymbai ML, Jagannathan AM, Vyas FL. Intracholecystic papillary-tubular neoplasms of the gallbladder - A clinicopathological study of 36 cases. *Ann Diagn Pathol*. 2019 Jun;40:88-93. doi: 10.1016/j.anndiagpath.2019.04.014. Epub 2019 Apr 30. PMID: 31077876.
- [6]. Adsay NV, Bagci P, Tajiri T, Oliva I, Ohike N, Balci S, Gonzalez RS, Basturk O, Jang KT, Roa JC. Pathologic staging of pancreatic, ampullary, biliary, and gallbladder cancers: pitfalls and practical limitations of the current AJCC/UICC TNM staging system and opportunities for improvement. *Semin Diagn Pathol*. 2012 Aug;29(3):127-41. doi: 10.1053/j.semdp.2012.08.010. PMID: 23062420.
- [7]. Terzi C, Sökmen S, Seçkin S, Albayrak L, Uğurlu M. Polypoid lesions of the gallbladder: report of 100 cases with special reference to operative indications. *Surgery*. 2000 Jun;127(6):622-7. doi: 10.1067/msy.2000.105870. PMID: 10840356.
- [8]. Resende V, Roda R, Pedrosa M. Gallbladder papillary neoplasia associated with intrahepatic carcinoma and pancreaticobiliary malformation. *Gastroenterol Res*. 2012;5:245-8.
- [9]. Michalinos, A., Alexandrou, P., Papalambros, A. et al. Intracholecystic papillary-tubular neoplasm in a patient with choledochal cyst: a link between choledochal cyst and gallbladder cancer?. *World J Surg Onc* 14, 202 (2016). <https://doi.org/10.1186/s12957-016-0962-x>.
- [10]. Askan G, Basturk O. Intracholecystic papillary neoplasm. PathologyOutlines.com website. <https://www.pathologyoutlines.com/topic/gallbladderipn.html>. Accessed February 18th, 2022.
- [11]. Yamaguchi K, Chijiwa K, Saiki S, Shimizu S, Tsuneyoshi M, Tanaka M. Reliability of frozen section diagnosis of gallbladder tumor for detecting carcinoma and depth of its invasion. *J Surg Oncol*. 1997 Jun;65(2):132-6. doi: 10.1002/(sici)1096-9098(199706)65:2<132::aid-jso11>3.0.co;2-7. PMID: 9209526.