



## A Prosthodontic Approach for Managing Edentulism in Patient with Cleft Palate: A Case Report

Nighila Ravindran<sup>1</sup>, Sneha Joseph<sup>1</sup>, Aswani Surya<sup>1</sup>, Sankar Madhavan<sup>2</sup>

<sup>1</sup>Postgraduate, Department of Prosthodontics and Crown & Bridge, Sree Anjaneya Institute of Dental Sciences

<sup>2</sup>Professor and Head, Department of Prosthodontics and Crown & Bridge, Sree Anjaneya Institute of Dental Sciences

Date of Submission: 01-06-2024

Date of Acceptance: 10-06-2024

**ABSTRACT:** This case report shares the journey of a 56-year-old woman who faced challenges with speaking and swallowing due to an untreated cleft palate, despite having her cleft lip repaired. Through detailed assessments and personalized care, crafted a specialized complete denture with a pharyngeal obturator to address her unique needs. Following the treatment, the patient experienced remarkable improvements in her ability to speak, chew, and swallow comfortably. This case underscores the importance of tailored dental interventions in restoring oral function and enhancing the quality of life for individuals with cleft palate.

**KEYWORDS:** Cleft palate, complete dentures, pharyngeal obturator, speech difficulties, swallowing difficulties, personalized care.

### I. INTRODUCTION

Oral health is crucial in everyday activities like chewing, tasting food, speaking, and overall psychosocial well-being.<sup>1</sup> According to the Global Burden of Disease 2015 study, total tooth loss was the top cause of disability-adjusted life years (DALYs) related to oral health from 1990 to 2015.<sup>2</sup> People with cleft lip and palate (CLP) and those with maxillary complete dentures both suffer from the loss or damage of maxillary hard and soft tissues. However, their unique life experiences and histories of oral tissue loss can lead to different outcomes regarding oral rehabilitation.<sup>3</sup>

The cleft palate is one of the most prevalent birth defects, characterized by an elongated opening in the hard and/or soft palate. This defect can cause a range of complications, including feeding difficulties, delayed and impaired speech development, psychosocial challenges, and a reduced quality of life. Effective management of cleft palate requires a multidisciplinary approach, focusing on repairing the barrier between the oral and nasal cavities and rehabilitating velopharyngeal sphincter closure. While plastic surgery has improved outcomes in cleft palate reconstruction, surgical repair alone

often falls short. Thus, palatal appliances such as obturators and speech aid prostheses are crucial for restoring function.<sup>4</sup>

Historically, the use of these appliances dates back to ancient times, with figures like Demosthenes employing rudimentary methods to enhance speech. Over the centuries, the development of prosthetic designs has evolved significantly, becoming more sophisticated by the 19th century. Today, modern palatal obturators, with or without speech aids, serve as definitive treatments to recontour the oral cavity and address velopharyngeal inadequacy.<sup>4,5</sup>

Given the significant impact of cleft palate on an individual's development, timely and effective rehabilitation is essential. Current protocols advocate for a combination of reconstructive surgery and comprehensive multidisciplinary care beginning in infancy.<sup>6</sup> However, patients with both palatal defects and complete edentulism face unique challenges, particularly in the fabrication of complete dentures. Proper obturators and palatal extensions are necessary to ensure optimal speech, mastication, and deglutition. This case report highlights the successful rehabilitation of a cleft palate patient with a complete denture, emphasizing the importance of a tailored prosthodontic approach.<sup>7</sup>

### II. CASE REPORT

A 56-year-old female sought rehabilitation at the Department of Prosthodontics due to speech and swallowing difficulties stemming from a significant palatal defect associated with an untreated cleft palate, despite her cleft lip having undergone surgical repair during childhood. Upon intraoral examination, a unilateral cleft was evident, spanning from the hard palate to the soft palate up to the uvula. The hard palate displayed a low vault and irregular anatomy, while the soft palate, though structurally intact, demonstrated limited mobility and inadequate neuromuscular function, impeding proper palatopharyngeal

closure. Notably, no lip cleft was observed (figure 1).

To address these issues, the treatment plan involved crafting a complete denture pharyngeal obturator prosthesis along with a mandibular complete denture. The palatal component of the prosthesis aimed to cover the hard palate defect, preventing food and liquid accumulation and thereby enhancing speech and swallowing. Additionally, the pharyngeal portion extended posteriorly to the palatal plane and above the soft palate, establishing contact with the posterior and lateral pharyngeal walls during normal function. This design facilitated the restoration of velopharyngeal sphincter closure, contributing to improved speech and swallowing function.

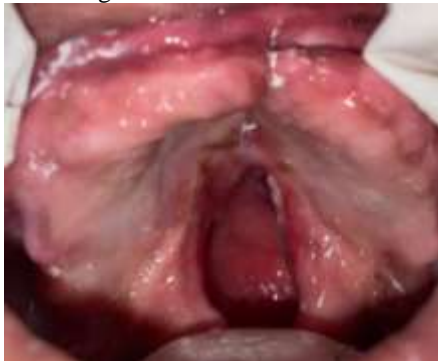

FIGURE 1: - Cleft palate

### III. TREATMENT

After choosing the suitable stock impression tray, primary impressions were taken using an impression compound (hi flex impression compound) (Figure 2). Modelling wax was used to block the undercuts in the cleft area on the primary cast.

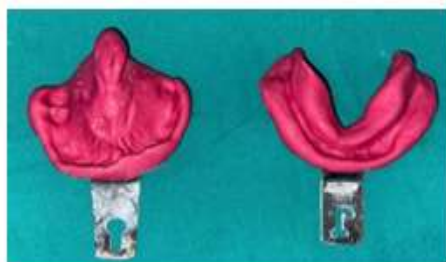


FIGURE 2: - Primary impressions

Custom impression trays were created using auto-polymerized acrylic resin. Border molding was performed using a green stick impression compound (DPI green stick). In the area of the defect, the type I modelling plastic impression compound was softened and adapted. To capture the posterior extension of the denture, the patient was instructed to slowly bend their head

forward, touch their chest, and then move it backwards. A softened modelling plastic impression compound was added to record the lateral aspects, and the patient was instructed to perform side-to-side movements. Additionally, the patient was asked to repeatedly and forcefully phonate the sound "ah." The impression surface was adjusted until the patient was satisfied with speech and comfort. Secondary impressions were then taken using light-body elastomeric impression material (3M ESPE Light body impression material).



FIGURE 3: - Master Cast

Jaw relations were recorded, and this was followed by a try-in session (Figure 4). During the try-in, assessments were made for speech, aesthetics, and swallowing. Speech evaluation was conducted using tests such as perceptual analyses, resonance frequency analyses, and acoustic analyses, revealing a significant improvement in speech. To assess swallowing, the patient was requested to drink water to check for any regurgitation. It was observed that the denture effectively prevented the regurgitation of liquid during swallowing.

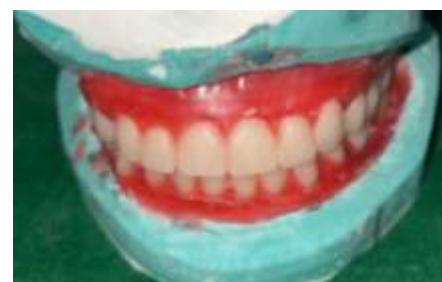

FIGURE 4: -Teeth arrangement

The waxed dentures underwent conventional investment and dewaxing procedures, following the manufacturer's guidelines.

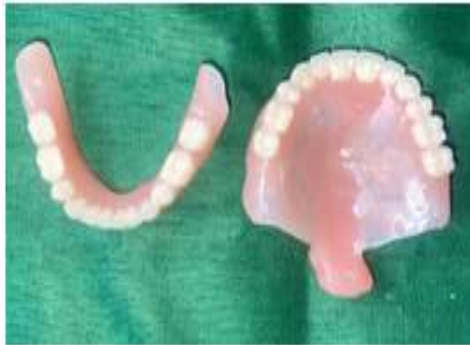

FIGURE 5: - Patient's dentures

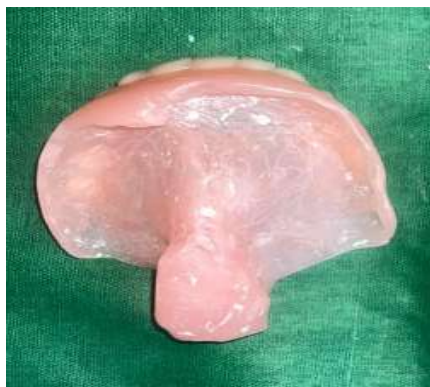

FIGURE 6: - Intaglio surface of dentures

Subsequently, complete dentures were provided to the patient (Figure 5&6).

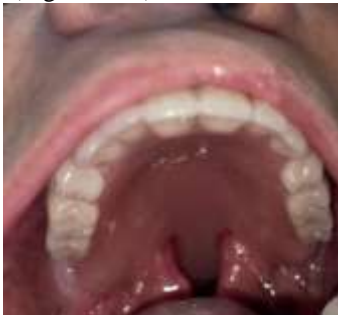

FIGURE 7: - Intraoral view with dentures

Comprehensive instructions were provided to the patient regarding proper cleaning and maintenance protocols for the complete dentures. The patient expressed satisfaction (figure 8&9) with the enhanced aesthetics, speech intelligibility, swallowing comfort, and masticatory efficiency facilitated by the improved retention and stability of the new prosthesis. Follow-up appointments were scheduled at one-week, one-month, and six-month intervals to monitor any challenges or adjustments required during denture wear.

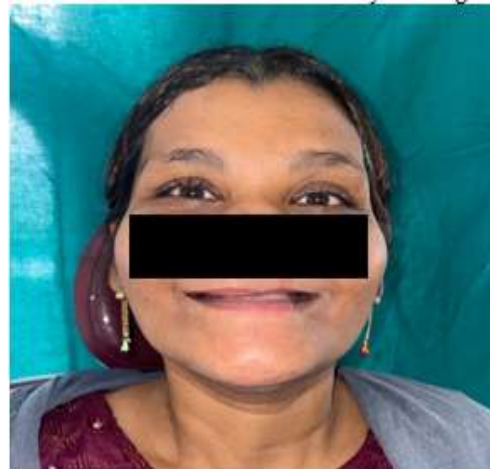

FIGURE 8: - Pre-op photograph of the patient.

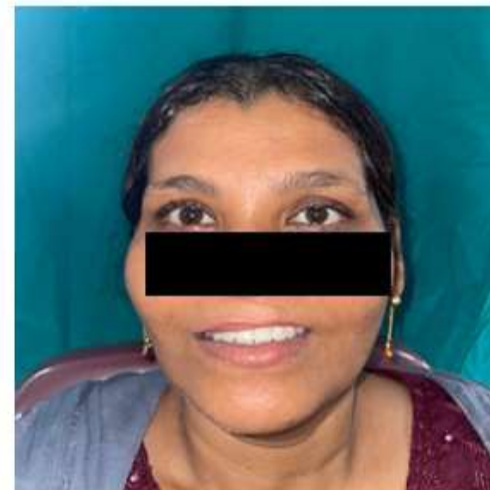

FIGURE 9: - Post-op photograph of the patient.

#### IV.DISCUSSION

Cleft lip/palate, the most common craniofacial congenital birth defect, exhibits significant variation across ethnic groups and geographic regions. This condition can be classified as syndromic or non-syndromic, depending on its association with other anomalies. The aetiology of cleft lip/palate is multifactorial, involving complex interactions between genetic and environmental factors. Its ramifications are extensive, impacting psychological, social, medical, and financial aspects of affected individuals' lives. In developing countries, socioeconomic factors and access to medical facilities heavily influence treatment options and outcomes.<sup>8</sup>

For patients with a cleft palate, timely surgical intervention is crucial. In this case, the patient had surgical closure of the lip during early childhood but could not undergo palatal surgery due to financial constraints. This underscores the





importance of early and interdisciplinary management to optimize functional and aesthetic outcomes. The patient, now an adult, required a complete denture with an obturator and pharyngeal bulb due to edentulism and a palatal defect. The prosthesis not only aimed to enhance quality of life but also to provide significant functional and psychological benefits.

The patient can experience wearing dentures with retention and stability, impacting chewing and speaking abilities. To address this, the new maxillary denture included a proper peripheral seal and intimate contact with the oral mucosa, improving retention. The upward extension of the obturator compensated for the reduced seal in the posterior palatal area.<sup>10</sup>

Speech evaluation showed remarkable improvement with the new denture, as evidenced by perceptual analyses, resonance frequency analyses, and acoustic analyses. The denture also effectively prevented the regurgitation of liquids and food during swallowing. The patient expressed satisfaction with the dentures regarding aesthetics, chewing, swallowing, and speech during recall visits.

Restoration of cleft palate defects ideally begins early, before adulthood, to address the associated functional and aesthetic impairments. Adult patients with unrepaired cleft palates present unique challenges for maxillofacial prosthodontists. These patients often exhibit habitual speech and sound errors, abnormal neuromuscular function, incomplete velopharyngeal valve closure, nasal air emission, irregular jaw relationships, atypical dentition, defective intraoral tongue pressure, weak lip support, and conductive hearing loss. VPI treatment, with or without speech therapy, is more effective in younger patients because they have not yet developed these compensatory behaviours.

Prosthetic rehabilitation poses greater challenges for edentulous adult patients. Issues such as the weight of the prosthesis, inadequate peripheral border seal, and the lack of opposing mandibular dentition are particularly pronounced in such cases. Edentulism is prevalent in rural areas, often attributed to poor oral health, limited education, socioeconomic disparities, and restricted access to dental services. Consequently, many older adults in these regions have never sought dental care, resulting in prolonged periods of edentulism and a significant decline in their overall quality of life.

In this instance, the patient's unaddressed palatal defect led to speech and swallowing difficulties, highlighting the necessity for comprehensive and accessible dental services.

Despite limited resources, the patient exhibited resilience by training their tongue, lips, and soft tissues to perform specific manoeuvres to aid speech. This underscores the importance of tailored interventions and patient empowerment in managing oral health challenges amidst resource constraints.

## V. CONCLUSION

Treating cleft lip and palate poses significant challenges and necessitates long-term planning and continuous follow-up. This case report highlights the successful management of an edentulous cleft palate patient using a maxillary complete denture with a palatal obturator and pharyngeal extension. The patient reported satisfaction with the dentures regarding aesthetics, chewing, swallowing, and speech. Prosthetic rehabilitation of a cleft palate is cost-effective and rapid and a conservative approach with minimal complications.

## REFERENCE

- [1]. Palmeiro MR, Bronstrup MB, Durham J, Walls A, Shinkai RS. Quality of life and mastication in denture wearers and cleft lip and palate adults. *Brazilian oral research*. 2018 Nov 29;32: e113.
- [2]. Kassebaum NJ, Smith AG, Bernabé E, Fleming TD, Reynolds AE, Vos T et al. Global, regional, and national prevalence, incidence, and disability-adjusted life years for oral conditions for 195 countries, 1990-2015: a systematic analysis for the global burden of diseases, injuries, and risk factors. *J Dent Res*. 2017 Apr;96(4):380-7
- [3]. Glick M, Williams DM, Kleinman DV, Vujicic M, Watt RG, Weyant RJ. A new definition of oral health supported by FDI opens the door to a universal definition of oral health. *J Dent*. 2017 Feb; 57:1-3.
- [4]. Ferro, K.J.; Morgano, S.M.; Driscoll, C.F.; Freilich, M.A.; Guckes, A.D.; Knoernschild, K.L. The Glossary of Prosthodontic Terms. *J. Prosthet. Dent*. 2017, 117, C1–e105.
- [5]. Beumer, J.; Curtis, T.A.; Marunick, M.T. *Maxillofacial Rehabilitation: Prosthodontic and Surgical Management of Cancer-Related, Acquired, and Congenital Defects of the Head and Neck*, 3rd ed.; Quintessence Pub: Hanover Park, IL, USA, 2011; pp. 315–355.
- [6]. Güven, O.; Gürbüz, A.; Baltali, E.; Yilmez, B.; Hatipoglou, M. Surgical and



- Prosthetic Rehabilitation of Edentulous Adult Cleft Palate Patients by Dental Implants. *J. Craniofac. Surg.* 2010, 21, 1538–1541.
- [7]. Rosalen, N.P.; Muniz, F.W.; Scalo, N.R.; Dezingrini, K.S.; Colussi, E.L.; Pires, A.L.; Colussi, P.R.G. What variables are associated with use of and need for dental prosthesis? A cross-sectional study. *Gerodontology* 2021. Early View
- [8]. Slayton RL, Williams L, Murray J, et al.: Genetic association studies of cleft lip and/or palate with hypodontia outside the cleft region. *Cleft Palate Craniofac J.* 2003, 40:274-9.
- [9]. Kang, D.-C.; Park, J.-H.; Seok, H.; Baek, J.-A.; Kim, D.-W.; Ko, S.-O. Speech-aid prosthesis in velopharyngeal incompetency patient with cleft palate: Can speech aids be applicable for adult patient? *Maxillofac. Plast. Reconstr. Surg.* 2021, 43, 1–7.
- [10]. Markus, A.F.; Watts, R. Cleft palate speech. *Dent Clin. North Am.* 2000, 12, 481–498.
- [11]. Hardwick, C.; Puryer, J. A palatal speech bulb-A case study. *Reports* 2019, 2, 5.