



A Functional Study of Tibial Shaft Fractures Treated with Suprapatellar Versus Infrapatellar Nailing Technique.

Dr.Sathya Swarup, Dr. Ashit Shetty, Dr. Shridhar Shetty

(Postgraduate, Department Of Orthopaedics, A.J Institute Of Medical Sciences and Research Centre, NH 66 Kuntikana, Mangalore, Karnataka, India)

(Postgraduate, Department Of Orthopaedics, A.J Institute Of Medical Sciences and Research Centre, NH 66 Kuntikana, Mangalore, Karnataka, India)

(Professor & Unit Head, Department Of Orthopaedics, A.J Institute Of Medical Sciences and Research Centre, NH 66 Kuntikana, Mangalore, Karnataka, India)

Submitted: 20-10-2024

Accepted: 30-10-2024

ABSTRACT

- **Introduction:** Tibia and fibula shaft fractures are pervasive, constituting the lion's share of long bone injuries in adults. Tibial shaft fractures, making up about 2% of all fractures, often necessitate surgical intervention. While the traditional infra-patellar approach for intramedullary nail fixation is commonplace, it encounters challenges in proximal third tibia shaft fractures, resulting in deformities and persistent postoperative knee pain.
- **Objectives:** This study seeks to meticulously compare the clinical, functional, and radiological outcomes of intramedullary interlocking nailing in tibial shaft fractures, delving into the nuances of supra-patellar and infra-patellar approaches. Additionally, an in-depth analysis of complications associated with each surgical technique will be conducted.
- **Materials and Methods:** Conducted at AJIMS & RC, Mangalore, Karnataka, a prospective study involving 8 patients with tibial shaft fractures treated using both approaches unfolded from July 2022 to November 2023. Patients were diligently followed for six months, and outcomes were meticulously assessed using the Lysholm knee scoring system to ensure a cohort of uniformity.
- **Observations:** The functional and anatomical outcomes, meticulously gauged through the Lysholm knee scoring system, unveiled promising results with the supra-patellar approach. This novel technique demonstrated a reduction in postoperative anterior knee pain and improved knee extension during surgery, offering a potential leap forward compared to the conventional infra-patellar approach.
- **Conclusion:** In summation, the supra-patellar approach for intramedullary tibial nailing, executed in a semi- extended knee position, emerges as an exciting and promising

alternative to the traditional infra-patellar approach. This pioneering technique not only showcases favourable clinical, functional, and radiological outcomes but also minimizes complications. These encouraging preliminary findings beckon for further research and larger-scale studies, hinting at a transformative shift in the surgical management of tibial shaft fractures.

I. AIMS AND OBJECTIVES

- To evaluate and compare the **clinical, functional and radiological union** in fractures of shaft of tibia nailing with supra-patellar approach and infrapatellar approach.
- To study and compare the **complications** associated with supra-patellar nailing method and infrapatellar nailing method.

II. METHODOLOGY

- A prospective study was conducted on **30 patients** with Tibia shaft fracture operated with intramedullary interlocking nailing through supra-patellar approach and infra-patellar approach between **July 2022 to February 2024** at AJIMS & RC, Mangalore, Karnataka, and followed up for 6 months and results were assessed using Lysholm knee scoring system.



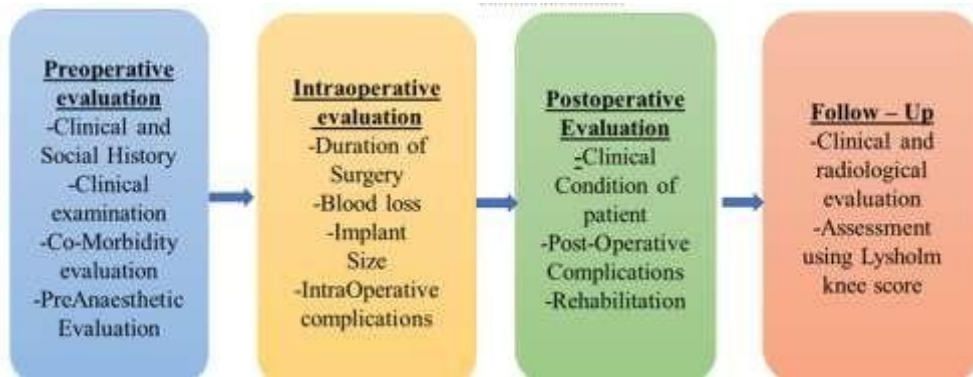

Inclusion criteria

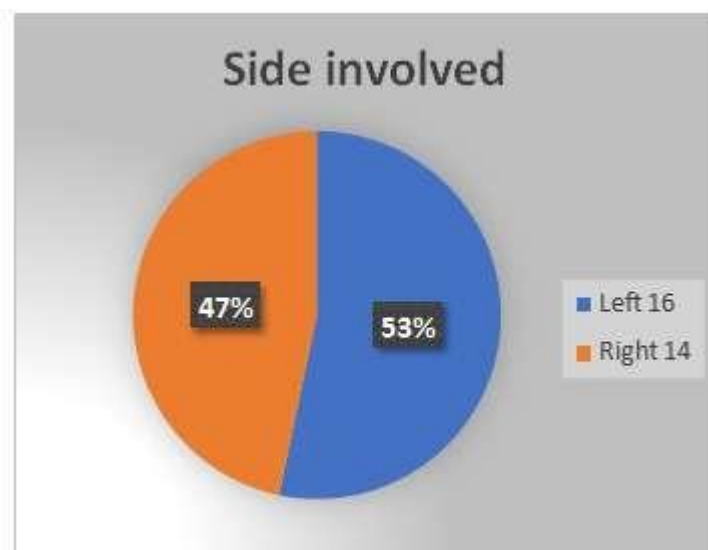
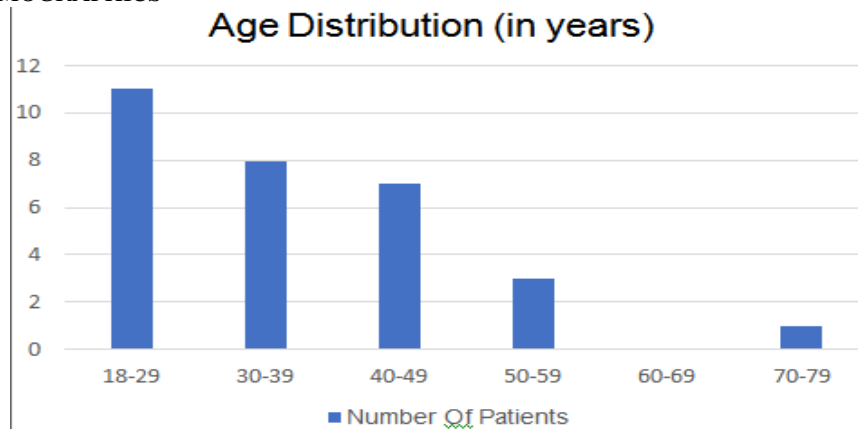
- All patients medically fit for surgery.
- Extraarticular tibia fractures.
- All skeletally mature patients (>18years and <80yrs)
- Compound type 1 and type 2 fractures

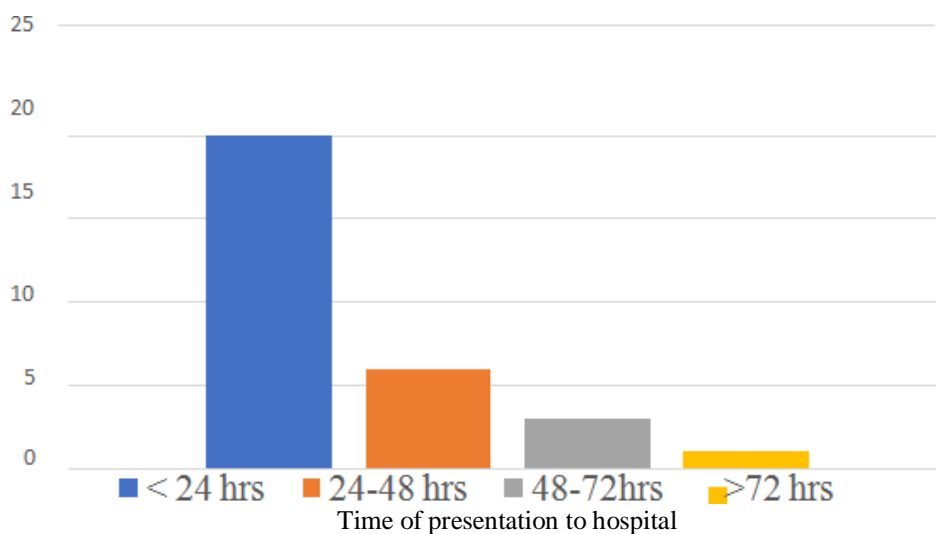
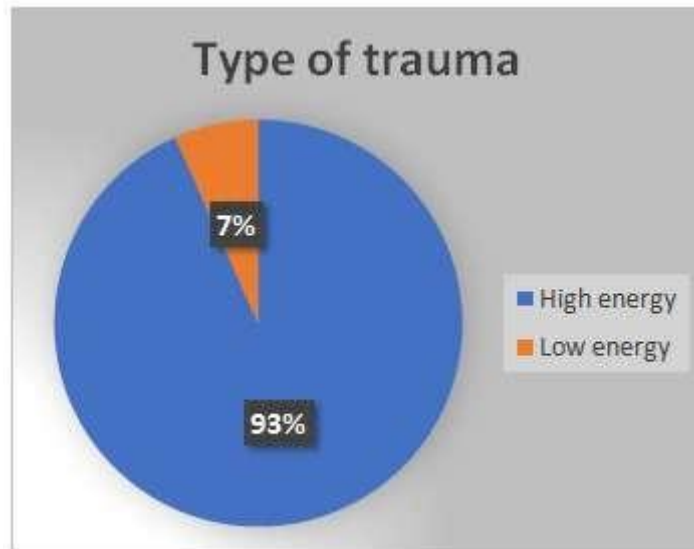
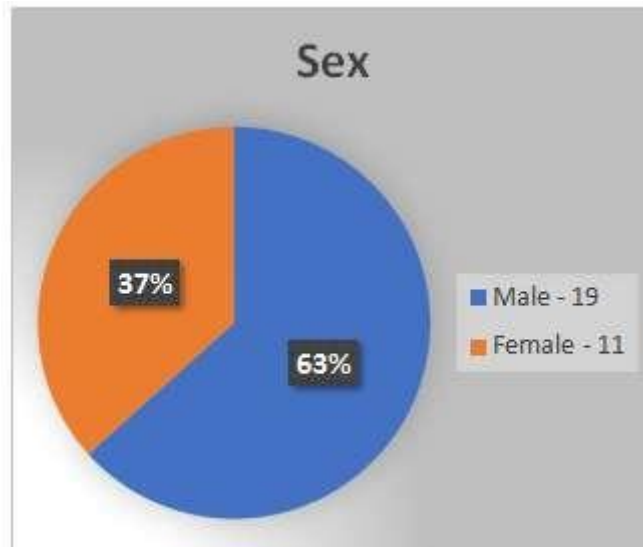
- Patients not willing or medically unfit for surgery.
- Compound type 3 fractures.
- Age (<18years and >80years)
- Ipsilateral knee injury.
- Severe ankle diseases such as rheumatoid and gouty arthritis.

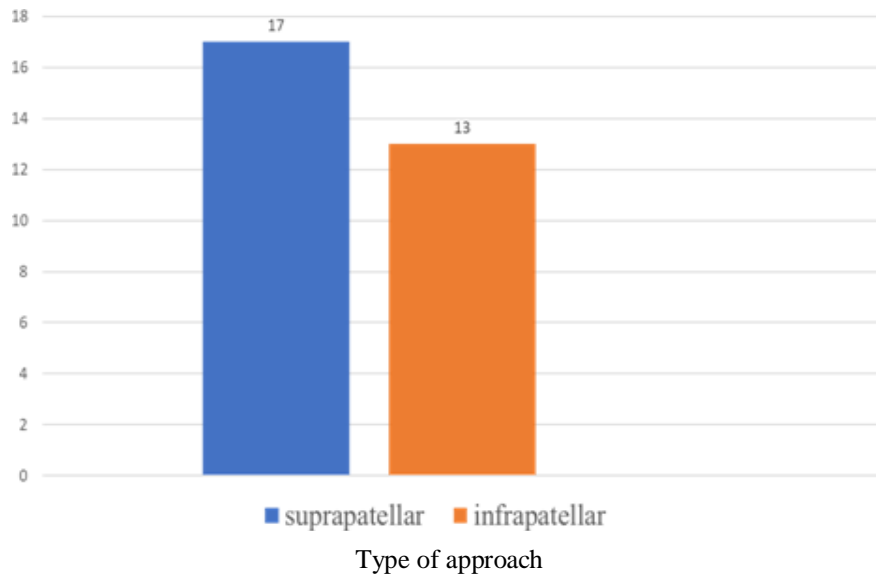
Exclusion criteria



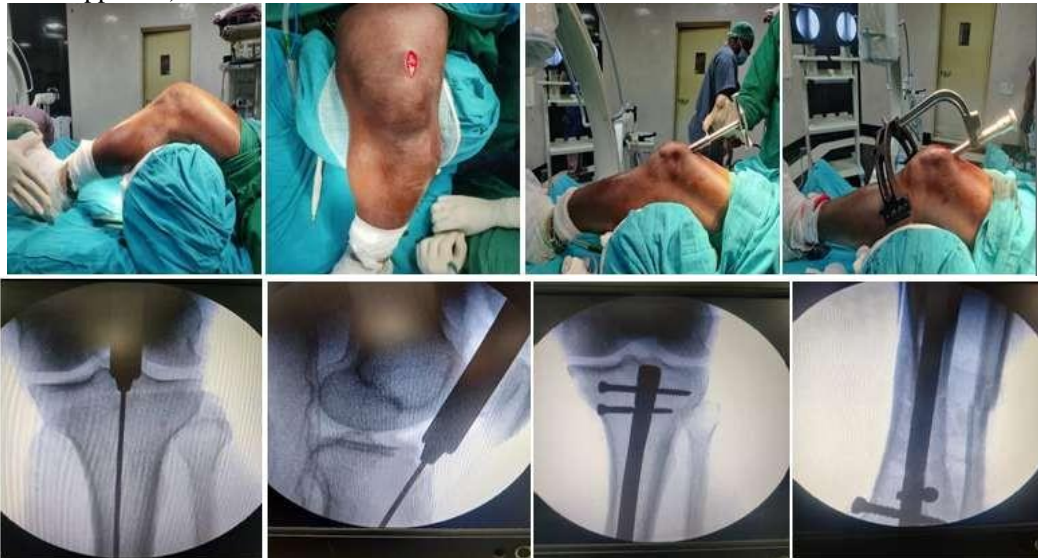
PATIENT DEMOGRAPHICS



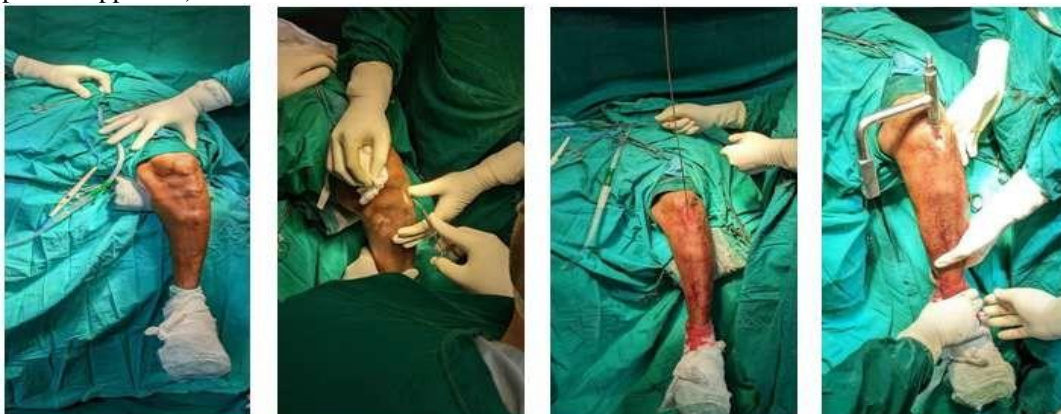


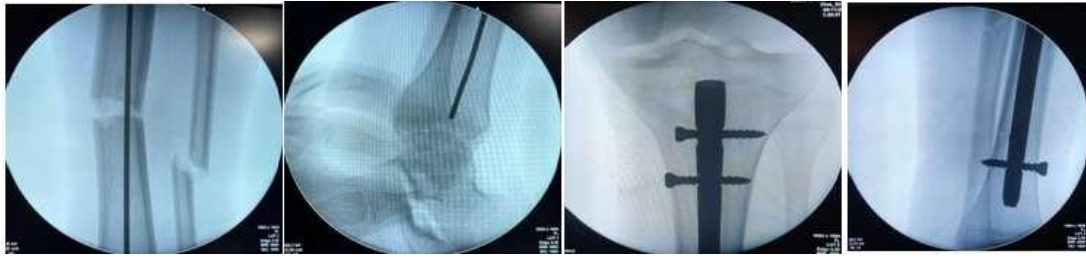
INTRA-OP PICS OF THE PROCEDURE
(Suprapatellar approach)



INTRA-OP PICS OF THE PROCEDURE
(Infrapatellar approach)

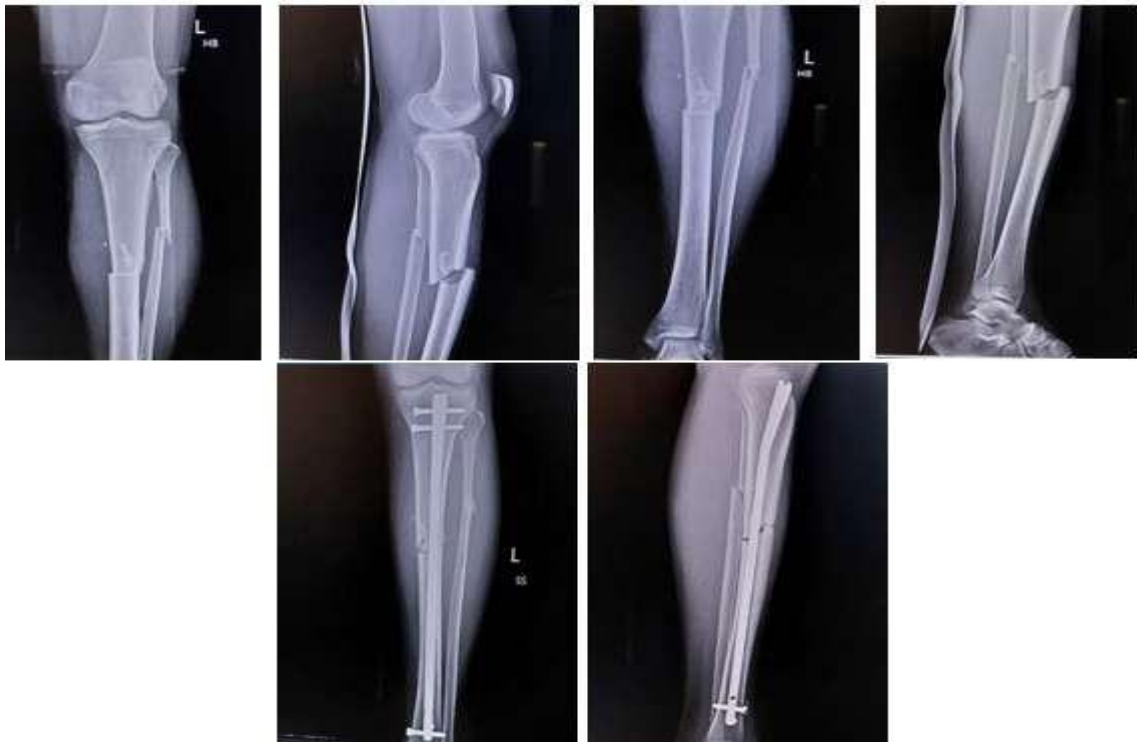



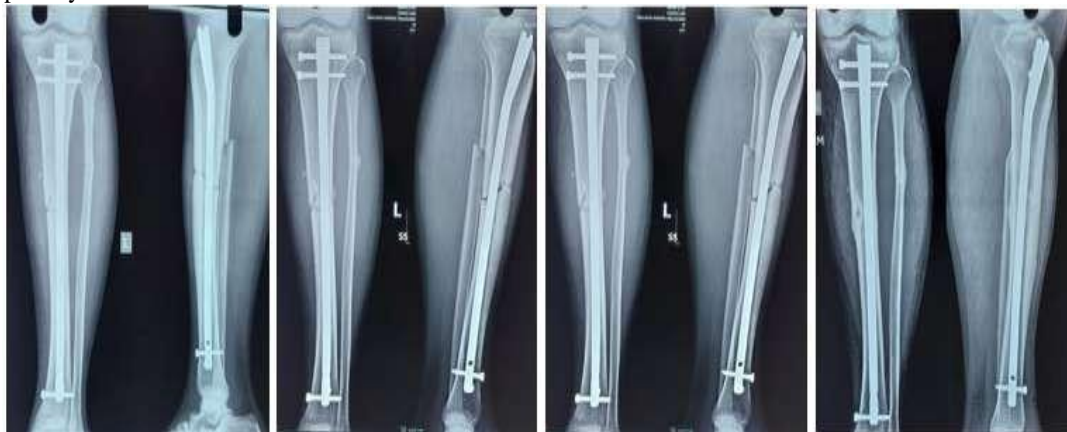CASE SCENARIO

- Admission diagnosis : Compound type 2 left proximal 1/3rd middle 1/3rd junction tibia and fibula shaft fracture without DNVD.

Pre-op X-rays



Post-op X-rays



1 month

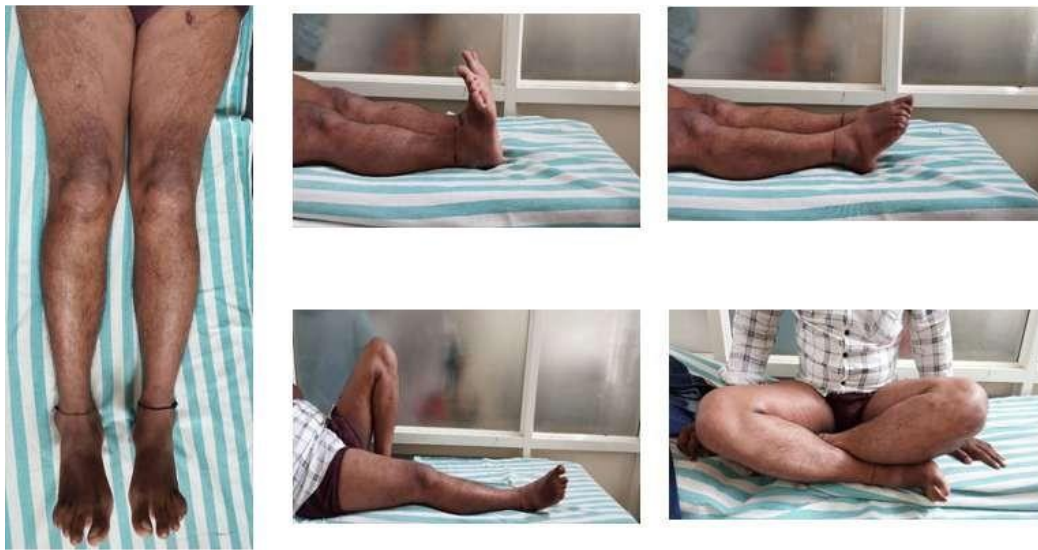2 months

3 months

6 months



CLINICAL PICTURE



COMPLICATIONS

Complications	suprapatellar	infrapatellar
superficial skin infection	1	2
Anterior knee pain	0	3
Delayed union	1	1

FOLLOW UP

LKSS	No. of patients via Suprapatellar approach	No of patients via Infrapatellar approach	Mean LKSS in Suprapatellar approach	Mean LKSS in Infrapatellar approach
At 1 month	17	13	66.26	66.0
At 2 months	15	10	72.80	70.64
At 3 months	9	7	77.07	75.03
At 6 months	7	6	92.67	88.03
At 1 year	4	2	96.83	90.52

III. RESULTS

- Functional and anatomical results were assessed for 30 cases into considerations using **Lysholm knee scoring system.**
- <65 = poor result
- 65-83 = fair
- 84-94 = good
- 95-100 = excellent

FUNCTIONAL RESULTS	NO OF CASES DONE VIA SUPRAPATELLAR APPROACH	NO OF CASES DONE VIA INFRAPATELLAR APPROACH	TOTAL NO OF CASES	PERCENTAGE
EXCELLENT	15	7	22	73.33%
FAIR	2	6	8	26.66%
POOR	0	0	0	0



IV. DISCUSSION

- Patient suffering from postoperative **anterior knee pain** is less when compared to infrapatellar approach than in the suprapatellar approach.
- **Extension of knee** during surgery which was very useful in the treatment of complex metaphyseal and diaphyseal tibia fractures can be achieved via suprapatellar technique
- Suprapatellar approach also **relaxes quadriceps** muscle, preventing mal-reduction.
- Additionally **surgeon's convenience** is more in the suprapatellar approach than the infrapatellar approach.
- **Union rates** are almost comparable in both the approaches.

V. CONCLUSION

- Suprapatellar approach of intramedullary tibial nailing in semi extended position of knee offers an **alternative** to traditional infrapatellar approach and has good results.
- Specific instrumentation with a canula system allows for nail insertion in a safe fashion and **minimize the risk** of iatrogenic damage to intraarticular structures in suprapatellar approach,
- **Delayed union** was the only complication which was evident via suprapatellar approach whereas **anterior knee pain and delayed union** were seen in infrapatellar approach.

REFERENCES

- [1]. Franke J, Hohendorff B, Alt V, et al. Suprapatellar nailing of tibial fractures: indications and technique. *Injury*. 2016;47(2):495–501.
- [2]. Tornetta P 3rd, Collins E. Semiextended position of intramedullary nailing of the proximal tibia. *Clin Orthop Relat Res*. 1996;328:185–9.
- [3]. Katsoulis E, Court-Brown C, Giannoudis PV. Incidence and aetiology of anterior knee pain after intramedullary nailing of the femur and tibia. *J Bone Joint Surg Br*. 2006;88(5):576–80.
<https://doi.org/10.1302/0301-620X.88B5.16875>.
- [4]. Chen X, Xu HT, Zhang HJ, Chen J. Suprapatellar versus infrapatellar intramedullary nailing for treatment of tibial shaft fractures in adults. *Medicine (Baltimore)*. 2018;97(32): e11799.
<https://doi.org/10.1097/MD.00000000000011799>.
- [5]. Gao Z, Han W, Jia H. Suprapatellar versus

infrapatellar intramedullary nailing for tibial shaft fractures: a meta-analysis of randomized controlled trials. *Medicine (Baltimore)*. 2018;97(24): e10917.
<https://doi.org/10.1097/MD.00000000000010917>.