



Anaesthetic management of lower segment caesarean section in a patient with mitral stenosis under combined spinal epidural technique: A case report

Deepa Dharmaraj, Naveen Ramji*, Lakshmi Ramakrishnan

Department of Anesthesiology, Saveetha Medical College, Thandalam, Chennai, Tamil Nadu

Submitted: 15-05-2021

Revised: 26-05-2021

Accepted: 28-05-2021

ABSTRACT: Rheumatic heart disease is the most common cause of mitral stenosis and patients with mitral stenosis becomes symptomatic during pregnancy due to increase in blood volume and heart rate. Neuraxial anaesthesia for caesarean delivery can be safely performed in patients with moderate mitral stenosis provided that systemic vascular resistance, preload and afterload is maintained. We report a case of G2A1 woman with moderate mitral stenosis who underwent lower segment caesarean delivery under combined spinal epidural technique. As per the patient's height of 155cm and weight of 75kg, 1.2ml of 0.5% bupivacaine + 0.5ml of fentanyl given according to Harten's chart. The mother and neonate were stable after the procedure.

I. INTRODUCTION

Rheumatic heart disease is a major cardiac disease associated with pregnancy in India, despite its declining trend^{1,2}. Among the cardiac disease complicating pregnancy, mitral stenosis is associated with 88% of cases referred to tertiary centre^{3,4}. Anaesthesiologist plays a multidisciplinary role by providing better perinatal care thereby reducing the morbidity and mortality⁵. Rheumatic heart disease is the most common cause of mitral stenosis. Rheumatic fever causes pancarditis due to cardiac inflammation which heals with scarring affecting the valves⁶. The main cardiovascular changes in pregnancy which worsen features of mitral stenosis are increase in blood volume by 30% to 50% starting at the end of 1st trimester to peak at 20 to 24 weeks which increases pulmonary capillary hydrostatic pressure thereby increasing the risk of pulmonary oedema, decrease in systemic vascular resistance, increase in heart rate by 10 to 20 beats per minute which reduces diastolic filling time of left ventricle and cardiac output increases by 30 to 50% after 5th month. Cardiac output returns to normal after 12 to 24 weeks postpartum. Transvalvular gradient increases significantly which increases left atrial pressure giving rise to symptoms. There will be sudden rise

in venous return to the heart due to autotransfusion and Inferior vena cava decompression leading to decompensation. Enlarged atrial dimension predispose to atrial arrhythmias⁷. Hence the management depends upon the severity of disease with multidisciplinary care for the safe outcome of mother and neonate.

II. CASE REPORT

A 25 year old G2A1 female with 39 weeks gestation was posted for elective caesarean delivery in view of cephalopelvic disproportion. She is a known case of Rheumatic heart disease with moderate mitral stenosis and moderate pulmonary hypertension. During preanesthetic assessment her blood pressure was 100/70mmhg and heart rate was 70/min. All routine laboratory investigations were within normal limits. After obtaining written and informed consent, patient was shifted to Operating room. All routine monitors were attached. Two large bore intravenous cannula 16G and 18G were inserted. Arterial line was secured in left radial artery and continuous blood pressure monitoring was done. Ringer's lactate was used judiciously. Under aseptic precautions, parts painted and draped, L3 -L4 space palpated, using Combined spinal epidural needle by (needle through needle technique), subarachnoid block was given with 1.2ml of 0.5% bupivacaine and 0.5ml of fentanyl. Skin to epidural space was 4cm and epidural catheter was fixed at 10cm after dilatating the epidural space with 3ml of 1% lignocaine with adrenaline. Test dose negative. Then patient was made to lie down and within 5 minutes sensory level reached to T6. Surgery was uneventful and baby delivered in 10 minutes. Just immediately after delivery, Inj. Lasix 10mg intravenous was given to maintain preload. 20IU of oxytocin in 500ml NS over 4hours infusion was started. Target Mean arterial pressure of 65mmhg was maintained with inj. Phenylephrine boluses. Throughout the surgery duration of 40mins, oxygen was given through face mask. Intraoperative period was uneventful as shown in Figure 1,2 and 3. Epidural



catheter was removed in postoperative care unit and patient was shifted to high dependency unit for

further monitoring. Postoperative period was uneventful.

Figure 1

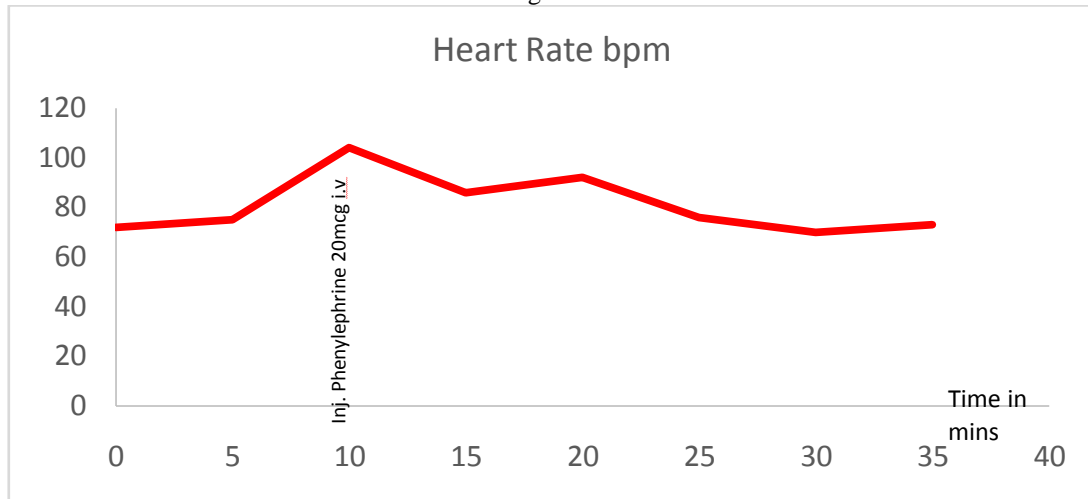


Figure 2

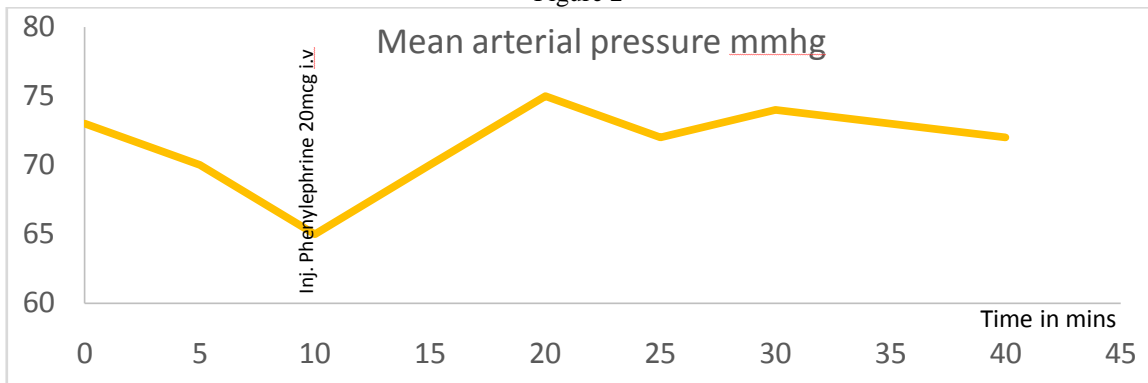
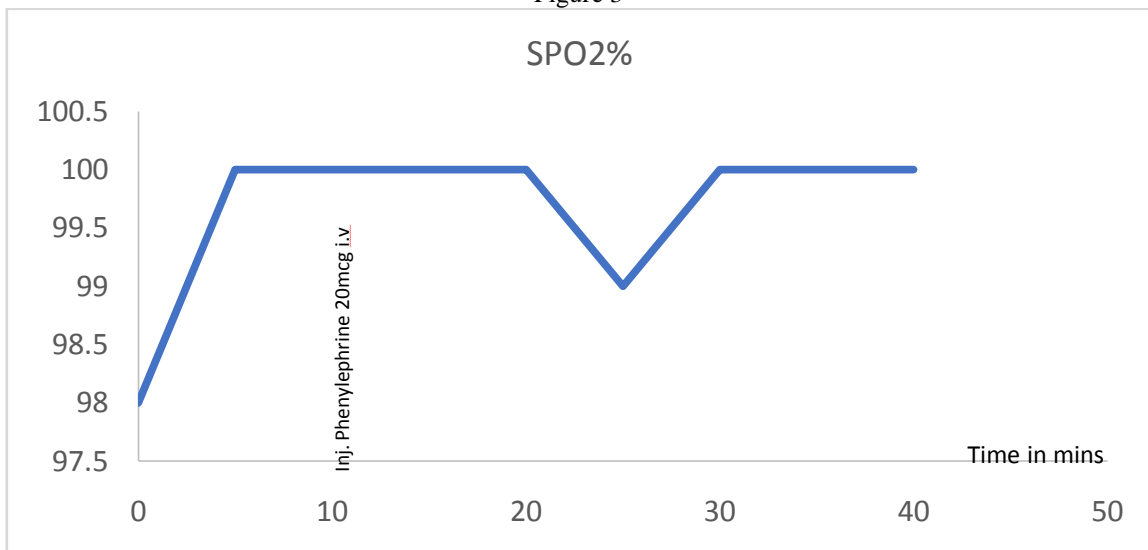


Figure 3





III. DISCUSSION

We report a case of G2A1 woman with moderate mitral stenosis without any cardiac symptoms in whom percutaneous transvenous mitral commissurotomy was done in 2019 for severe mitral stenosis with Mitral valve area 0.8cm^2 , posted for Elective Lower segment caesarean section. Recent echocardiography showed Mitral valve area 1.5cm^2 ; Mild to moderate left atrial enlargement; Mean gradient 6mmHg ; Pulmonary artery pressure 30mmHg ; Moderate mitral regurgitation; Ejection fraction 60% patient was on T.PENTID 400mg BD; T.METOPROLOL 12.5 mg OD; T.ECOSPORIN 75mg OD. The goals for the anaesthetic management of patients with mitral stenosis are maintenance of an acceptable slow heart rate, immediate treatment of acute atrial fibrillation and reversion to sinus rhythm, avoidance of aortic caval compression, maintenance of adequate venous return, maintenance of adequate systemic vascular resistance and prevention of pain, hypoxaemia, hypercarbia and acidosis, which may increase pulmonary vascular resistance⁸. Regional anaesthesia has proved to be a safe technique in cardiac patients presenting for caesarean section, however the problems associated is mainly the hemodynamic alterations associated with it. During the lower segment caesarean section, there will be approximately 1000ml of blood loss which may lead to decrease in after load. The use of vasoconstrictors such as phenylephrine to prevent hypotension and tachycardia and judicious administration of intravenous fluids make this a safe technique for both mother and baby⁹. However, there has been controversy over the use of neuraxial blockade in patients with severe mitral stenosis as this is a fixed cardiac output state, and the patient may not tolerate the associated decreased systemic vascular resistance. Further, these patients may be on drugs such as diuretics and beta-blockers that may compromise the compensatory cardiovascular mechanisms present in normal parturients¹⁰. There are several recent case reports of successful use of neuraxial blockade in parturients with severe heart disease^{11,12,13}. As shown in Figure 1, 2 and 3 patient's mean arterial pressure, heart rate and SPO₂ were stable throughout the surgery and one bolus of inj. Phenylephrine 20mcg intravenously was given. Combined spinal and epidural anaesthesia was administered successfully in this patient without any complications.

REFERENCES

- [1]. Padmavati S. Present status of rheumatic fever and rheumatic heart disease in India. *Indian Heart J.* 1995;47:395–8.
- [2]. Jose VJ, Gomathi M. Declining prevalence of rheumatic heart disease in rural schoolchildren in India: 2001–2002. *Indian Heart J.* 2003;55:158–60.
- [3]. Misra M, Mittal M, Singh R, Verma A, Rai R, Chandra G, et al. Prevalence of rheumatic heart disease in school-going children of Eastern Uttar Pradesh. *Indian Heart J.* 2007;59:42–3.
- [4]. Bhatla N, Lal S, Behera G, Kriplani A, Mittal S, Agarwal N, et al. Cardiac disease in pregnancy. *Int J Gynaecol Obstet.* 2003;82:153–9.
- [5]. Malhotra M, Sharma JB, Tripathii R, Arora P, Arora R. Maternal and fetal outcome in valvular heart disease. *Int J Gynaecol Obstet.* 2004;84:11–6.
- [6]. Saxena KN, Wadhwa B, Mishra D. Anesthetic management of cesarean section in parturients with severe mitral stenosis: A case series. *J Obstet Anaesth Crit Care* 2019;9:46–9.
- [7]. Vidovich MI. Cardiovascular disease. In: Chestnut DH, Polley LS, Tsen LC, editors. *Chestnut's Obstetric Anaesthesia: Principles and Practice.* 5th ed. Philadelphia (PA): Mosby Elsevier; 2014. pp. 960–1002.
- [8]. Kannan M, Vijayanand G. Mitral stenosis and pregnancy: Current concepts in anaesthetic practice. *Indian J Anaesth.* 2010;54(5):439–444.
- [9]. Langesaeter E, Dragsund M, Rosseland LA. Regional anaesthesia for a Caesarean section in women with cardiac disease: A prospective study. *Acta Anaesthesiol Scand* 2010;54:46–54.
- [10]. Dyer RA, Reed AR, Van Dyk D, Arcache MJ, Hodges O, Lombard CJ, et al. Hemodynamic effects of ephedrine, phenylephrine, and the coadministration of phenylephrine with oxytocin during spinal anesthesia for elective cesarean delivery. *Anesthesiology* 2009;111:753–65.
- [11]. Naz A, Dasgupta S, Bandhopadhyay BK, Shirazee HH. Graded epidural anaesthesia for Caesarean section in a parturient with Shone's syndrome: A case study. *S Afr J Anaesth Analg* 2016;22.
- [12]. Mishra L, Pani N, Samantaray R, Nayak K. Eisenmenger's syndrome in pregnancy: Use of epidural anesthesia and analgesia for



- elective cesarean section. *J Anaesthesiol Clin Pharmacol* 2014;30:425- 6.
- [13]. Hillyard SG, Bate TE, Corcoran T, Paech MJ, O'Sullivan G. Extending epidural analgesia for emergency Caesarean section- a meta-analysis. *BJA* 2011;107:668- 78