



CT Evaluation of Intracranial Calcifications.

Dr.Praveen Kumar R, Dr.Shraavan Shankar, Dr. Praveen Kumar John.

Post-Graduate, A.J. Institute Of Medical Sciences & Research Centre,Mangalore.

Post-Graduate, A.J. Institute Of Medical Sciences & Research Centre,Mangalore.

Professor, A.J. Institute Of Medical Sciences & Research Centre,Mangalore.

Submitted: 20-10-2024

Accepted: 30-10-2024

I. AIMS AND OBJECTIVES:

- To diagnose intracranial calcification on CT imaging and to classify calcifications into physiological and pathological based on age , appearance and location.
- To distinguish between physiological from pathological intracranial calcification.

II. METHODS AND MATERIALS:

- **SOURCE OF DATA:** This study was performed in the department of radiodiagnosis, A.J institute of medical sciences, Mangalore.
- **SAMPLE SIZE:** Fifty cases (50).
- **STUDY DESIGN:** Retrospective.
- **IMAGING PROTOCOL:** CT brain done in siemens 128 slice CT machine. It consists of contiguous axial sections of 5mm thickness in craniocaudal direction. Reconstruction will be done with thickness of 1 mm. Coronal and sagittal reconstructions will be done.Contrast will be given whenever necessary.All images

are viewed in soft tissue and bone window settings.

• INCLUSION CRITERIA:

1. Male and female patients of all age group presenting with symptoms like fever, headache, vomiting, behavioural disorders, dizziness, neurological deficits of sudden onset.
2. Asymptomatic symptoms where intracranial calcifications, are detected at time of routine CT scanning done for other diagnosis.

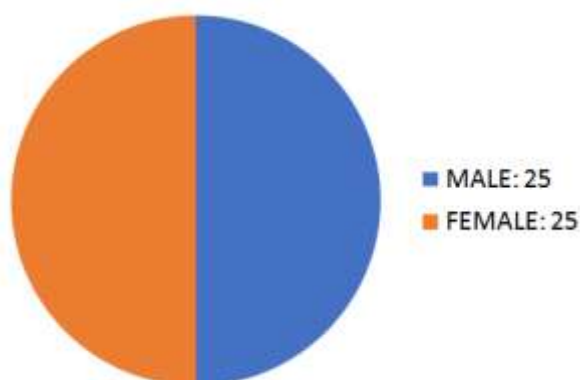
• EXCLUSION CRITERIA:

1. Known cases of skull bone trauma.
2. Pregnancy.

III. RESULTS

1.INCIDENCE OF CASES ACCORDING TO GENDER.

- The study of 50 patients who fulfilled inclusion criteria enrolled, out of which 25 were male,25 were female.



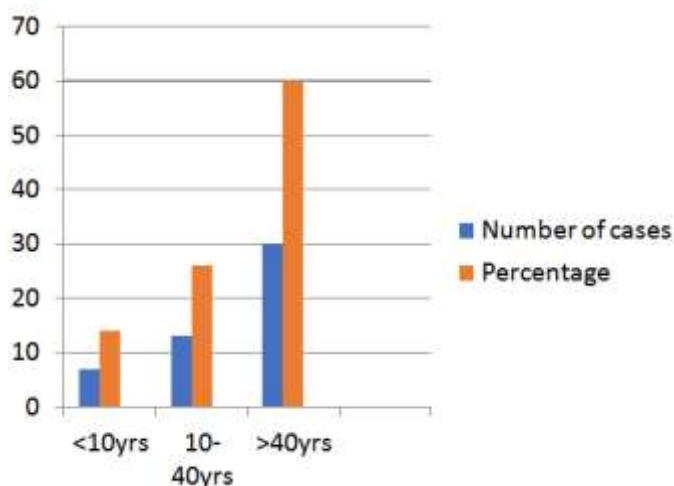
2.INCIDENCE OF CASES ACCORDING TO AGE GROUP.

- Patients divided into 3 age groups of <10yrs,10-40yrs and >40yrs.14% (7 cases)of

cases of intracranial calcifications found in <10 yrs,26% (13 cases) in 10-40 yrs and majority of case with 60% (30 cases)seen after 40 years.



AGE GROUP	NUMBER	%
<10YRS	7	14%
10-40YRS	13	26%
>40YRS	30	60%
TOTAL	50	100%

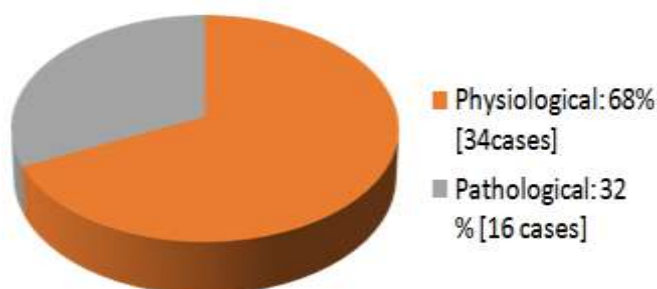


3. INCIDENCE OF PHYSIOLOGICAL AND PATHOLOGICAL CALCIFICATIONS:

- In the study, only physiological calcifications seen in 34 patients(68%) and pathological

calcification seen in 16 cases(32%) who also had physiological calcifications.

TYPE	NUMBER OF CASES	%
PHYSIOLOGICAL	34	68%
PATHOLOGICAL	16	32%
TOTAL	50	100%



4. INCIDENCE OF PHYSIOLOGICAL CALCIFICATIONS ACCORDING TO SITE.

- In our study, pineal gland is the commonest site of physiological calcification seen in 40

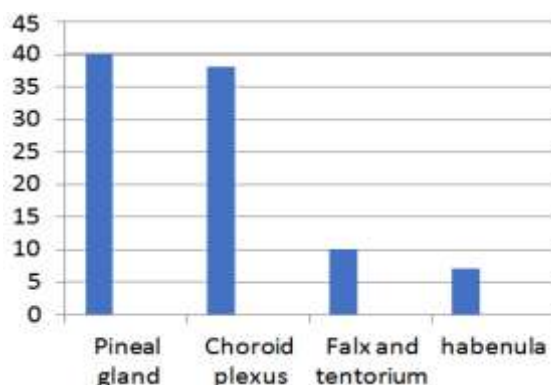
cases(80%), followed by choroid plexus calcification in 38 cases(76%). Next being falx and tentorium calcification seen in 10



cases(20%) and habenular calcification in 7 cases(14%).

NUMBER OF CASES OF PHYSIOLOGICAL CALCIFICATION AS PER SITES

SITE	CASES	%
PINEAL GLAND	40	80%
CHOROID PLEXUS	38	76%
FALX AND TENTORIUM	10	20%
HABENULA R	7	14%

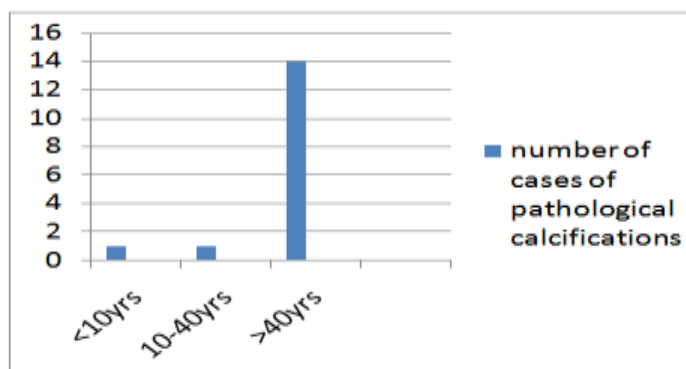


5. INCIDENCE OF TOTAL PATHOLOGICAL CALCIFICATIONS ACCORDING TO AGE;

14cases(88%), followed by 1 case in <10yrs and 1 case between 10-40yrs.

- Highest incidence of pathological calcification found after 40 years seen in

AGE	CASES	%
<10YRS	1	6%
10-40YRS	1	6%
>40YRS	14	88%
TOTAL	16	100%



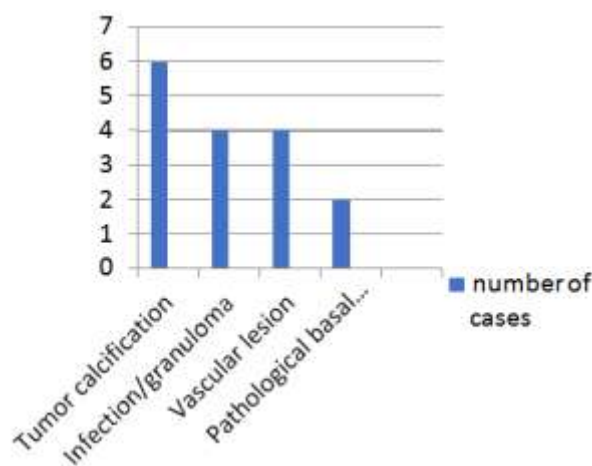


6.SUMMARY OF INCIDENCE OF TYPES OF PATHOLOGICAL CALCIFICATION.

- Among patients with pathological calcification, most common was tumor calcification with 6

cases(37.5%).Infections/granuloma seen in 4 cases(25%),vascular lesion calcification in 4 cases(25%) and pathological basal ganglia calcification in 2 cases(12.5%).

DIAGNOSIS	NUMBER OFCASES	%
TUMOR	6	37.5%
INFECTION S/ GRANULO MA	4	25%
VASCULAR LESION	4	25%
PATHOLOGIC BASAL GANGLIA	2	12.5%
TOTAL	16	100%

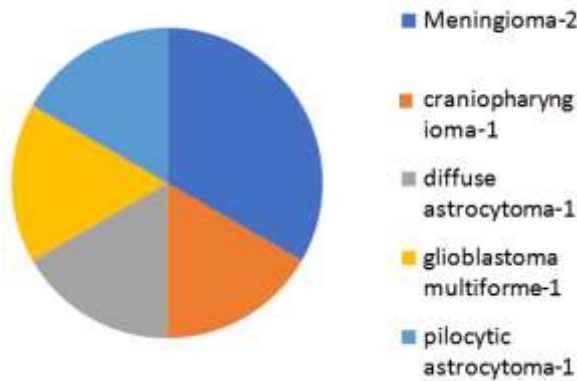


7.INCIDENCE OF CALCIFICATION AMONG TUMORS.

- Among 6 cases of tumoral calcification,2 cases were of meningioma,1 craniopharyngioma,1

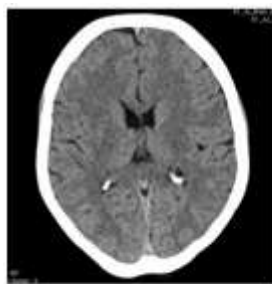diffuse astrocytoma,1 glioblastoma multiforme and 1 pilocytic astrocytoma.

TUMORS	NUMBEROF CASES	%
MENINGIOMA	2	33.3%
CRANIOPHARYNGIOMA	1	16.6%
DIFFUSE ASTROCYTOM A	1	16.6%
GBM	1	16.6%
PILOCYTIC ASTROCYTOM A	1	16.6%
TOTAL	6	100%

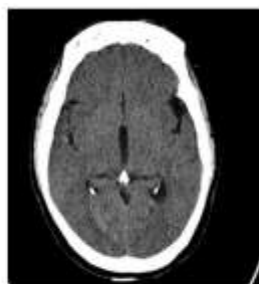

PHYSIOLOGICAL CALCIFICATIONS:

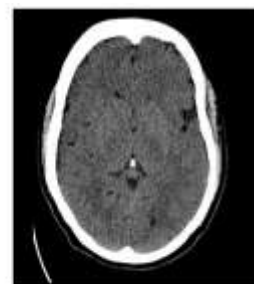1. Bilateral choroid plexus calcification in 58 year female with lower limb weakness.
2. Pineal gland and choroid plexus calcification in 30 year old female with headache.
3. Pineal gland calcification in 29 year boy with headache.



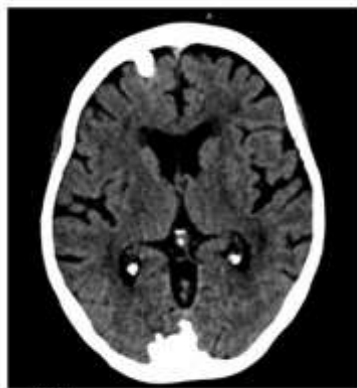Case:1



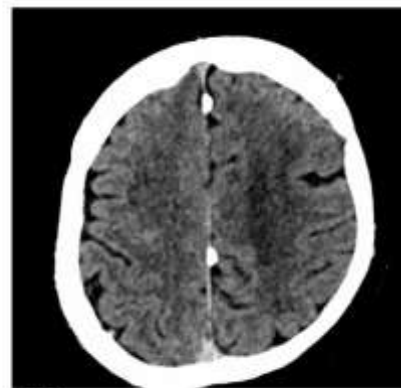
Case:2



Case:3



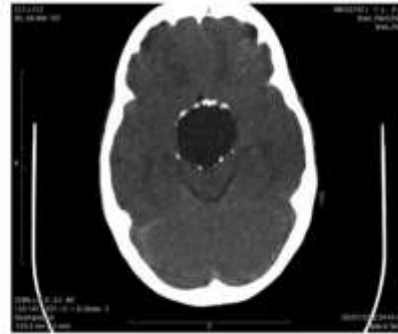
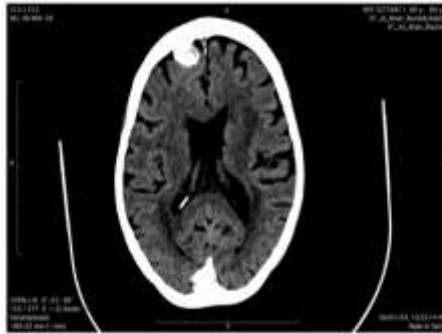
Case:4



Case:5

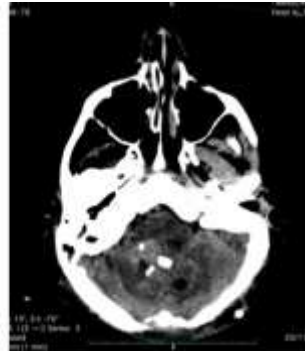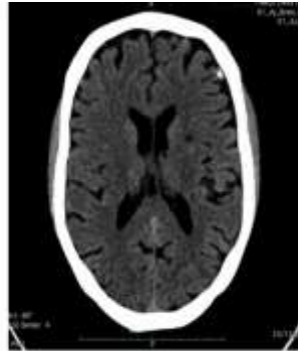
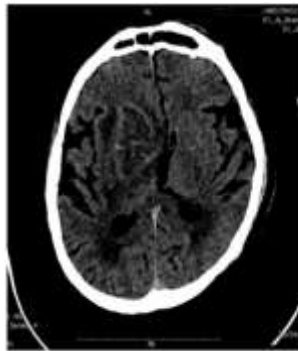4. 80 Yr female with headache and giddiness having bilateral choroid Plexus,pineal and habenular calcification.
5. Falx calcification in 60yr male with left sided weakness
1. Well defined extraaxial lesion with extensive calcification in right frontal region in 80 year female Case of CALCIFIED MENINGIOMA.
2. Relatively well defined hypodense lesion with peripheral rim of calcification in Sella and Suprasellar region in 10 year boy with sudden loss of consciousness .Case of CRANIOPHARYNGIOMA.

PATHOLOGICAL CALCIFICATION:

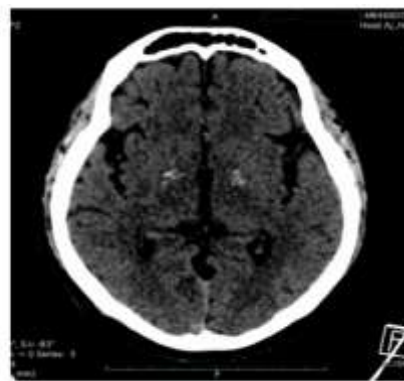
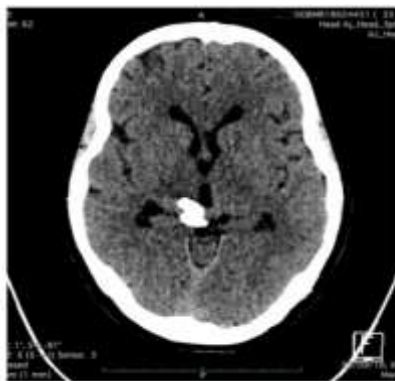
3. 61 year male with loss of consciousness. Ill defined heterodense area with surrounding edema And few foci of calcification in right gangliocapsular region.case of GLIOBLASTOMA MULTIFORME.

4. Calcified granuloma left frontal region in 46yr male.Case of NEUROCYSTICERCOSIS.
5. 6yr female.Cystic lesion with mural nodule and speck of calcification in posterior fossa. Case of PILOCYTIC ASTROCYTOMA



6. Chunky pop corn type calcification in left thalamus region in 33 yr female.Case of CAVERNOMA.
7. Bilateral basal ganglia calcification in 66 yr female who is known case of hypoparathyroidism.



IV. DISCUSSION AND CONCLUSION:

- PHYSIOLOGICAL INTRACRANIAL CALCIFICATION:
- Physiological calcifications are those which is not associated by any evidence of disease and have no demonstrable pathological causative factors.
- More prevalent in older age group.

- Choroid plexus, pineal gland, habenula, basal ganglia, falx, tentorium and sagittal sinus are among the common site for physiological calcification.
- In upto 40% of general population, pineal gland is calcified by the age of 20 years and are compact in appearance.



- Choroid plexus and habenular is another most common locations seen most commonly after 5th decade.
- Physiological calcifications of the duramater are also very frequent among older age population and are classically located in the falx or the tentorium. Dural calcifications in kids should raise the doubt of fundamental pathology, predominantly basal-cell nevus syndrome.
- Incidence of basal ganglia calcifications is merely 0.3-1.5%, usually idiopathic and incidental detected. Its incidence also increases with age.

PATHOLOGICAL INTRACRANIAL CALCIFICATIONS:

- **Tumoral calcification:** seen in extraaxial tumors like meningioma, craniopharyngioma, pinealocytoma, dermoid and epidermoids.
- Nearly 20 – 69% of meningiomas show calcification. These calcifications can range from focal or diffuse, and can be coarse or sand-like, sometimes even rim.
- Compact pineal calcifications measuring >10mm are worrisome of pineal gland tumors.
- Nearly 70 -90% of craniopharyngiomas observed in children have calcifications, and 30% to 40% of craniopharyngiomas seen in adults calcify. Adamantinous craniopharyngiomas are frequently encountered in children and mostly (90%) either calcify in the periphery and/or the solid component of the tumor.
- Intra-axial tumors like oligodendroglioma, astrocytoma, DNET, medulloblastoma and metastasis also show calcifications.
- The oligodendrogliomas demonstrate the highest incidence of calcification amongst all brain parenchymal tumors, and nearly 90% of them show calcification.
- **Vascular lesion calcifications:** causes include intracranial atherosclerosis, Cavernous angioma which shows pop corn pattern calcification, AV malformation showing serpentine calcification, AV fistulas, developmental venous anomaly .
- Vessel calcification seen in 90% of atherosclerotic lesions and are potential predictors of stroke.
- **Infections causing calcification:** include congenital lesions like cytomegalovirus, neonatal herpes, toxoplasmosis, rubella.
- Acquired infections like Neurocysticercosis, tuberculosis, cryptococcosis.
- Pathological basal ganglia calcifications occur due to endocrine /metabolic causes like hyperparathyroidism, hypoparathyroidism and hypothyroidism.
- Intracranial calcifications are relatively common findings and CT is most sensitive modality and modality of choice to detect and characterise them.
- They can be encountered in both pediatrics and adult population ,but commonly after 40 years.
- Physiological and pathological calcifications can co-exist. In our study all patients with pathological calcifications also had physiological calcifications which led us to conclude that normal physiological calcifications in CT have a documented location where they usually occur and follows an order unlike pathological calcifications.
- Several pathologic conditions involving the brain are associated with calcifications and the recognition of their appearance and distribution helps narrow the differential diagnosis.
- Patients age,clinical findings,location,size and pattern of intracranial calcification helps in aiding proper diagnosis and management.

REFERENCES

- [1]. Charbel Saade, Elie Najem, Karl Asmar, Rida Salman, Bassam El Achkar, Lena Naffaa. Intracranial calcifications on CT: an updated review.J Radiology case Rep.2019aug;13(8):1-18.
- [2]. Karan nataiaieto taborda, Catalina wilches, Alejandra manrique. A diagnostic algorithm for patients with intracranial calcifications.Rev,colomb.radiol.2017.28(3).4732-9.
- [3]. Kiroglu Y, Çalli C, Karabulut N, Öncel Ç. Intracranial calcifications on CT. Diagnostic and Interventional Radiology. 2010 Dec 1;16(4):263.
- [4]. Weins J, Stenbeg A (2003) Skull. In: Freyschmidt J,Brossman J, Weins J ed. Borderlands of normal and early pathological findings in skeletal radiography. Thieme, New York, pp. 380–386