



## Concordance of Ultrasonographic Findings with Fnac Results in Evaluation of Thyroid Swellings

Dr. Ananya Udgata<sup>1</sup>, Dr. Vikas Agrawal<sup>2</sup>, Dr. Biswaranjan Behera<sup>3</sup>

PG student, Department of Radiodiagnosis, Hi-tech Medical College & Hospital, Bhubaneswar.

Professor, Department of Radiodiagnosis, Hi-tech Medical College & Hospital, Bhubaneswar.

Asso. Professor, Department of Radiodiagnosis, Hi-tech Medical College & Hospital, Bhubaneswar.

Date of Submission: 01-02-2025

Date of Acceptance: 10-02-2025

### I. AIMS AND OBJECTIVES

- To study the Ultrasonographic features of various thyroid swellings in patients with thyroid disorders.
- To correlate the sonographic findings with FNAC in the evaluation of Thyroid swellings.
- In this study, we are trying to study the diagnostic accuracy of ULTRASOUND in evaluation of Thyroid swellings by correlating with FNAC impression.

### II. INTRODUCTION AND BACKGROUND

- Thyroid gland ( glandulathyroidea ) is a butterfly-shaped endocrine gland that sits & wraps around trachea. Thyroid nodules are a common condition and are found in 3-8% of the general population, females being more commonly affected.
- Serum TSH remains the primary screening test for thyroid dysfunction. Current guidelines recommend that serum TSH is the first-line test for detecting both overt & subclinical thyroid dysfunction.
- USG is the non-invasive, cost-effective, easily available investigation for evaluation of Thyroid pathology. Moreover, ACR TI-RADS uses a standardized scoring system providing recommendations for when to use ultrasound follow-up or FNAC or to safely leave nodules which are not suspicious.
- USG followed by FNAC increases the accuracy to diagnose various thyroid lesions so that unnecessary thyroid surgery can be avoided. Hence, diagnostic accuracy can be improved greatly by using multiple diagnostic modalities for thyroid swellings.

### NEED FOR THE STUDY

- A structured pre-prepared case proforma was used to enter the patient details, clinical history, physical examination and

investigations including thyroid function tests of patients who have met the inclusion and exclusion criteria.

- DEVICE / MACHINE used: SAMSUNG HS 70 A  
PHILIPS AFFINITY 70 G
- Machine settings : Grey scale & color doppler modes using a high resolution, 7.5-12 MHz, linear array transducer.
- FNAC of thyroid swelling was done after taking informed written consent & performing a coagulation profile.

### III. REVIEW OF LITERATURE

- Patel NR et al, performed a case study on 100 cases & concluded that USG findings were more significant as compared to FNAC findings for diagnosis of Thyroid swellings.
- Ahuja et al, studied large (>3cm) rapidly growing thyroid masses with ultrasound in 42 patients & concluded that USG was of value in differentiating between a benign hemorrhagic nodule & a malignant tumor.
- Ajith Nilakantan, MD. et al concluded that in patients with nodular thyroid disease, USG can accurately determine the number & size of nodules & is extremely useful in guiding FNAC.

### MATERIAL

- Total- 70 patients in the age group of 11 years & above with thyroid swellings referred to the department of Radiodiagnosis, Hi-tech Medical College & Hospital, Bhubaneswar during the period November 2023 – November 2024 for USG & FNAC were included in the study.
- Male-21, Female- 49
- Referred from Dept. of ENT & General Surgery
- November 2023 – November 2024



**Exclusion Criteria(s) :**

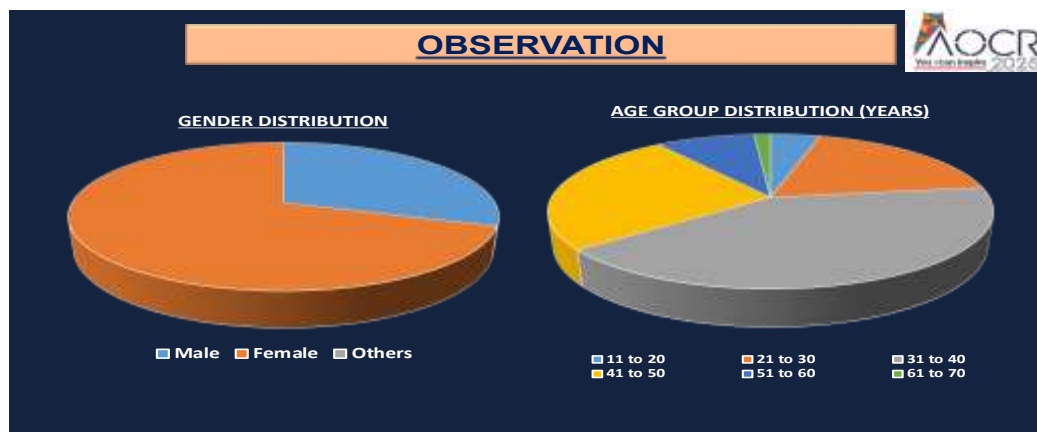
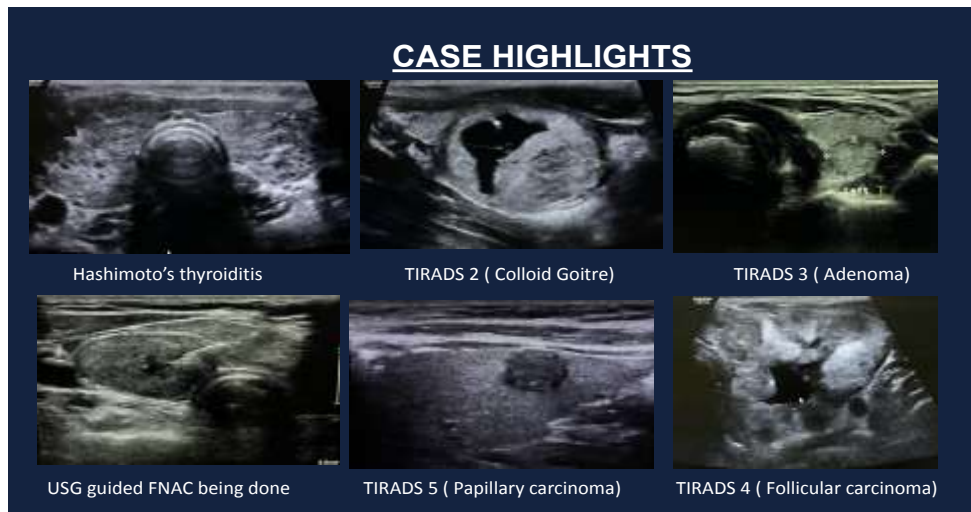
- Patients who did not give consent.
- Patients who were already undergoing treatment or had recovered after proper diagnosis and treatment.
- Patients with bleeding diathesis.

**METHODS**

- **STUDY DESIGN :** Prospective cross-sectional study.
- **STUDY SETTINGS :** Department of Radiodiagnosis, HI-TECH Medical College & Hospital, Bhubaneswar.
- **STUDY POPULATION :** Patients of all age groups of either sex with thyroid swelling.
- **DURATION OF STUDY :** November 2023 – November 2024.
- **SAMPLE SIZE :** As many as study participants who present during study period fulfilling inclusion & exclusion criteria.
- **SAMPLE TECHNIQUE :** Convenient sample technique.

**IV. METHODOLOGY**

- A structured pre-prepared case proforma was used to enter the patient details, clinical history, physical examination and investigations including thyroid function tests of patients who have met the inclusion and exclusion criteria.
- Sonographic evaluation of clinically diagnosed thyroid swelling was done using grey scale & color doppler modes using a high resolution, 7.5-12 MHz, linear array transducer in SAMSUNG HS 70 A & PHILIPS AFFINITY 70 G ultrasound machines. The swelling was then assigned a TI-RADS score & managed accordingly.
- FNAC was performed using a standard 1.5” 25 gauge, non cutting bevelled edge needle & a 10ml syringe. The samples were sent for histopathological evaluation.





### OBSERVATION

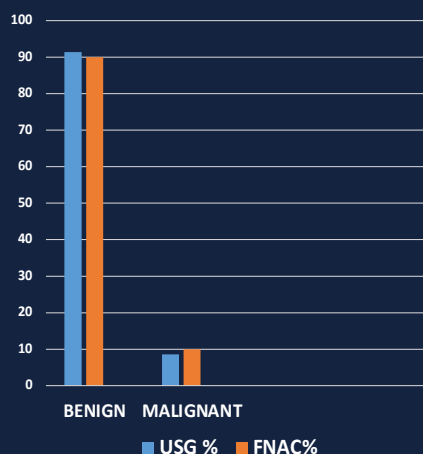
USG Diagnosis	No. of cases	Percentage
Adenoma (Benign)	27	38.8
Colloid goitre	16	22.9
Multinodular goitre	12	17.2
Hashimoto's thyroiditis	02	2.8
Diffuse hypertrophy of gland	04	5.8
Nodule with degenerative changes	03	4.3
Carcinoma	06	8.6

FNAC findings	No. of cases	Percentage
Adenoma (Benign)	29	40
Colloid goitre	24	28.6
Multinodular goitre	12	17.2
Hashimoto's thyroiditis	02	2.9
Papillary Ca	04	5.7
Follicular Ca (Biopsy proven)	02	2.9
Medullary Ca	01	1.4
Thyroglossal cyst	01	1.4
Total	70	100

### OBSERVATION

Lesion	USG Diagnosis	%	FNAC Diagnosis	%
Benign	64	91.4	63	90
Malignant	06	8.6	07	10
Total	70	100	70	100

CORRELATION BETWEEN USG & FNAC FINDINGS



### V. RESULTS

In the above study :

- It is found that Thyroid diseases are more common in females (70%) than males (30%) & maximum number of patients are in the age group 31-40 years (41.5%).
- Most USG diagnosis were benign (adenoma) i.e., 38.8% & least common is hashimoto thyroiditis i.e., 2.8%.
- Most FNAC diagnosis were adenoma i.e., 40% followed by colloid goitre i.e., 28.6%.
- Out of the total 70 cases, 64 cases (91%) were benign and 6 cases (9%) were malignant. By

FNAC 7 cases (10%) were malignant & 63 cases (90%) were benign.

### VI. DISCUSSION

- In our study , out of 70 cases :
  1. Maximum number of cases were between 3<sup>rd</sup> to 5<sup>th</sup> decade with females constituting 70%.
  2. 80% cases had solitary & 20 % had multiple thyroid nodules.
  3. Out of 56 benign thyroid nodules, 40% were adenoma, 28.6% were colloid goitre& 17.2% were multinodular goitre.



4. Carcinoma was confirmed on FNAC in 7 cases of which papillary carcinoma was 4, medullary carcinoma 1 & follicular carcinoma 2 (biopsy proven).
5. 2 patients revealed the features of Hashimoto's thyroiditis in USG & were confirmed on HPE.

## VII. CONCLUSION

- High resolution USG is a safe, non – invasive, less time consuming, easy to perform, repeatable modality & does not employ any ionizing radiation. It is gold standard for assessing the morphological structure, size of the gland & its vascularity.
- USG followed by FNAC increases the accuracy to diagnose various thyroid lesions thereby avoiding unnecessary thyroid gland surgery.

## REFERENCES

1. [https://www.wikilectures.eu/w/Thyroid\\_gl](https://www.wikilectures.eu/w/Thyroid_gl) and [1]. Shrestha E, Thapa NB, Rajbhandari SBS et al. Role of Ultrasonography in the Evaluation of Thyroid Nodule with Fine Needle Aspiration Cytology ( FNAC) Correlation. Nepal Journal of Medical Sciences.2021;6(2):32-8. <https://doi.org/10.3126/njms.v6i2.42419>
- [2]. Nehal R. Patel, Alpesh V. Patel, Vaibhav V. Patel, Payal R. Vadher, Manali B. Kakadia et al. Ultrasonographic ang fine needle aspiration cytology correlation of thyroid gland lesions; a study of 100 cases. International Journal of Otorhinolaryngology and Head and Neck Surgery. Patel NR et al. Int J Otorhinolaryngol Head Neck Surg. 2019 Mar;5(2):319-325<http://www.ijorl.com>
- [3]. Grainger & Allison's Diagnostic Radiology, 7<sup>th</sup> edition, Volume-2 ,P- 1634
- [4]. AIIMS-MAMC-PGI Comprehensive Textbook of diagnostic Radiology,3<sup>rd</sup>edition,Volume- 4, P- 3795 – 3797