



Dens Invaginatus with an Associated Periapical Cyst: A Rare Case Report

Dr. Abhishek S Hiremath¹, Dr. Sangeeth Siddabasappa², Dr. Sujatha G P³,
Dr. Ashok L⁴, Dr. Shambulingappa P⁵

¹ Dr. Abhishek S Hiremath, Postgraduate, Department of Oral Medicine and Radiology, Bapuji Dental College and Hospital, Davanagere, Karnataka, India

² Dr. Sangeeth Siddabasappa, Professor, Department of Oral Medicine and Radiology, Bapuji Dental College and Hospital, Davanagere, Karnataka, India

³ Dr. Sujatha G P, Professor, Department of Oral Medicine and Radiology, Bapuji Dental College and Hospital, Davanagere, Karnataka, India

⁴ Dr. Shambulingappa P, Professor, Department of Oral Medicine and Radiology, Bapuji Dental College and Hospital, Davanagere, Karnataka, India

⁵ Dr. Ashok L, Professor & Head, Vice Principal, Department of Oral Medicine and Radiology, Bapuji Dental College and Hospital, Davanagere, Karnataka, India

Corresponding Author: Dr. Abhishek S Hiremath

Date of Submission: 08-03-2026

Date of Acceptance: 20-03-2026

ABSTRACT

Dens invaginatus (dens in dente) is a rare malformation with a widely varied morphology. An unusual presentation of a type II dens invaginatus permanent lateral incisor in an 19-year-old male patient is reported. The presence of a periapical radiolucency further complicated the case.

KEYWORDS

Dens invaginatus, Periapical cyst, Lateral Incisor

I. Introduction:

Dens Invaginatus is a developmental anomaly resulting from an invagination in the surface of a tooth crown/root before its calcification. In humans, "DI" was first described by Socrates in 1859. It has also been referred to as dens in dente, dilated composite odontome, gestant odontoma, etc. Hallet introduced the term "dens invaginatus" to clarify the point that in invagination, enamel is located centrally and the dentin peripherally. Since then, it has been the preferred term². The patient is usually unaware of this condition, and the anomaly is detected with the help of an intraoral periapical (IOPA) radiograph taken for another indication. Radiological examination shows a radio-opaque invagination similar in density to enamel, extending into the central region of the crown at a variable distance from the tooth. The following case report describes the case of dens in dente in a maxillary lateral incisor associated with a chronic periapical lesion.

II. Case Report:

A 19 year old male patient reported with a complaint of pain and swelling in the left upper front tooth region for 3 months. The patient's medical and Surgical history was unremarkable. Patient has no deleterious habits. Extra orally, right submandibular lymph nodes are enlarged, roughly oval in shape, palpable, mobile, tender, and firm in consistency. (Fig a) Intraorally, Solitary swelling was present on the left side of palate of size about 2cm X2.5cm extending Antero posteriorly from distal part of 21 to 24 and mediolaterally from the gingival margin to midline of palate, surface over the swelling was smooth and its borders of were well defined. On palpation, the swelling was tender and firm. On Hard tissue examination, A deep palatal pit and slight discoloration was noticed on the palatal surface of left permanent maxillary lateral incisor. The tooth was tender on vertical percussion and did not respond to respond to the electric pulpal vitality test. (Fig c). Intraoral Periapical radiograph revealed presence of infoldings of enamel which is radiopaque and this infoldings appear as an inverted teardrop shaped radiolucency surrounded by radiopaque border extending beyond cemento-enamel 2 junction adjacent to root canal suggestive of type 2 Oehlers classification and Periapical radiolucency of size about 2cm X2.5cm with well-defined borders and distally pushing the root of 23. (Fig d) Orthopantomograph revealed type 2 dens invaginatus (DI) and periapical radiolucency in relation to 22. (Fig e). Cone beam Computed tomography revealed an expansile hypodense lesion with thinning of cortical bone in relation to 22 and



displacement of root of 23 distally, Axial section at the level of Cementoenamel junction showing the oval shaped radiolucency surrounded by the radiopaque line suggestive of enamel invagination and sagittal section confirming the diagnosis with the similar appearance. [Fig f,g,h]. Based on history, clinical and radiographic findings, a diagnosis of radicular cyst (RC) associated with DI in relation to 22 was made.

III. Discussion:

Dens invaginatus is a variation in the development of a tooth, which is thought to occur when there is an infoldings of the surface of the crown before calcification has begun. Radicular dens invaginatus is a rare dental anomaly with bizarre radiographic appearance. The etiology is considered controversial, as many mechanisms may be possible causes of this phenomenon, including local external influences on the dental germ, dental arch growth resulting in pressure that limits and deforms the enamel organ, incomplete fusion of two dental germs, infection processes, genetic factors, and trauma.³

Oehlers described dens invaginatus as occurring in three forms depending on the extension of enamel lined cavity, Type I – minor form occurring within the confines of the crown of the tooth and not extending beyond the amelocemental junction, Type II – which invades the roots but remains within its confines and Type III – severe form which penetrates through the root and shows a second foramen in the apical or periodontal area ⁴.

The prevalence of DI is 0.3% and 10% with symptoms in 0.25%–26.1% of individuals ⁵. More and Patel reported that 37.33% of cases of DI are associated with cysts ⁶. DI is common in maxillary lateral incisors, followed by maxillary centrals, premolars, canines, and is rarely seen in molars. The radicular variety is mostly seen in mandibular first premolars and second molars ⁷. Males are more affected by a ratio of 3:1. Other dental anomalies observed in association with dental invagination, including taurodontism, microdontia, supernumerary teeth, germination and dentinogenesis imperfecta ⁸. A deep lingual pit is often present on the tooth affected with dens invaginatus. The pit may be filled with soft tissue similar to dental follicles, the soft tissue becomes

necrotic when the teeth erupt into the oral cavity⁹. Two-dimensional radiographs will assist in determining the severity ³ and type of DI, but they are of limited use in understanding the complex root canal morphology in DI cases. Advanced imaging, such as spiral CT (SCT) or CBCT, reveals the complex root morphology, and examination of the anatomy of pulp canals increases the accuracy of diagnosis; also, providing a three-dimensional image helps the clinician to deliver the treatment procedure more precisely. These imaging techniques provide a three-dimensional view of the DI along with accurate morphology of root canals and typing of DI. Three-dimensional imaging is also useful in detecting the communication between the invagination and the primary root canal ¹⁰. In axial sections, the dens invaginatus can often be seen as an invagination lined with a radiopaque enamel circle and, in many cases, partially surrounded by the true root canal, which may assume a C-shape in cross-section, as it is “pushed” by the dens invaginatus. CBCT has been done in our case, which has contributed to the diagnosis of Dens invaginatus. CBCT revealed characteristic enamel infoldings within the root canal of tooth 22 with associated periapical radiolucency, confirming dens invaginatus. The treatment options for an invaginated tooth include prevention treatment by sealing or filling in the invagination, endodontic treatment, apical endodontic surgery, intentional reimplantation and exodontics ¹¹. The dentist must be aware of the variations and select the most appropriate materials and techniques for the removal of the necrotic tissue and bacteria ¹². Dens invaginatus can often be a concealed finding. Therefore, we suggest radiographic examination of all teeth that present with shape anomalies and hypoplasia especially maxillary anterior.

IV. Conclusion:

DI presents with associated complications such as the risk of dental caries, pulp, and periapical pathology. Hence, early diagnosis is crucial. The diagnosis and treatment planning of DI can be very challenging for a clinician due to complex dental anatomy. Awareness about the clinical and radiographic characteristics, possible complications, and the treatment of this anomaly is essential. ⁴

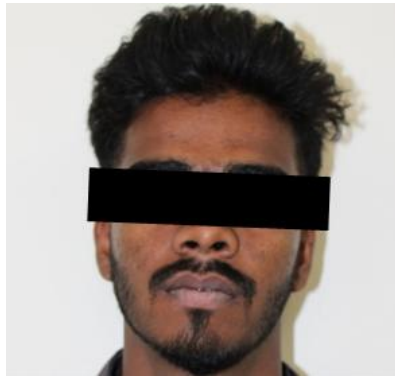

Fig a: Facial Profile

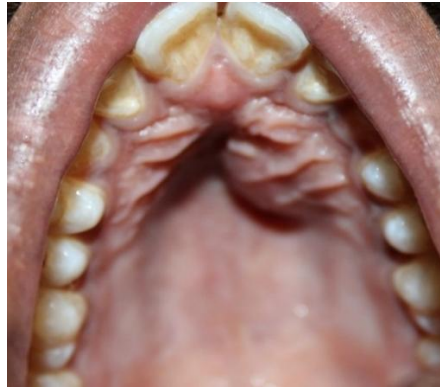

Fig b: Intra Oral Palatal Swelling

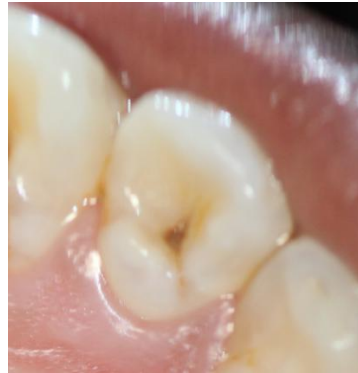

Fig c: Deep Palatal Pit irt 22

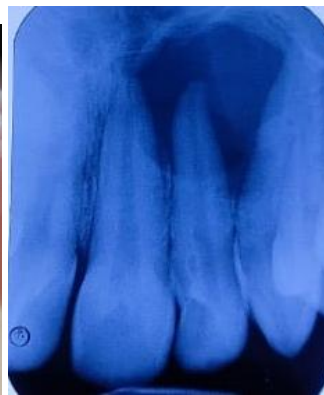

Fig d: IOPAR irt 22

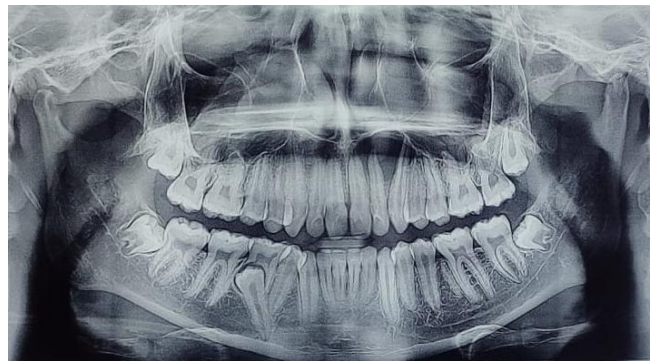


Fig e: Orthopantomograph

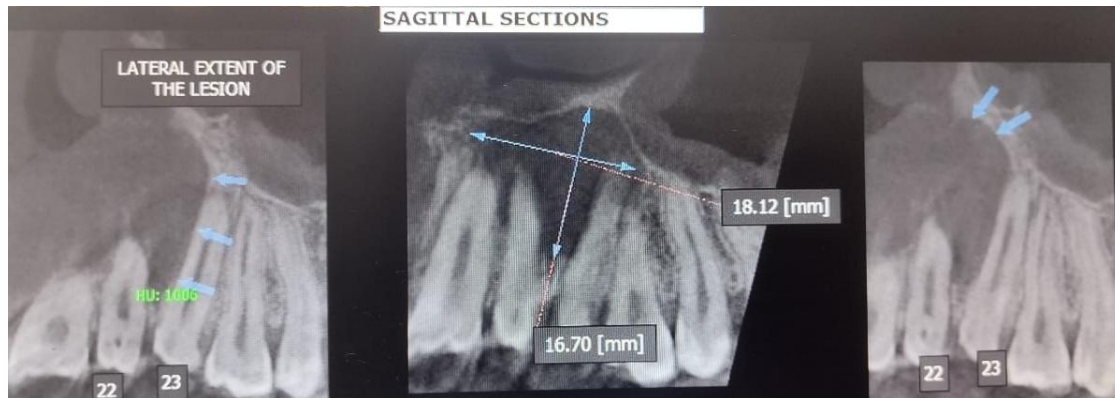

Fig f: CBCT Image: Sagittal View

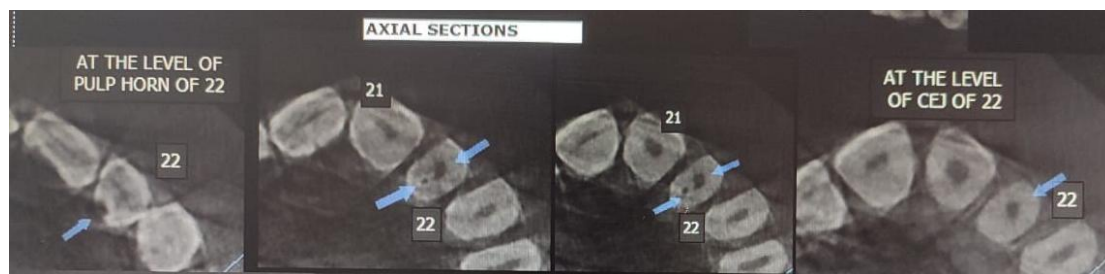

Fig g: CBCT Image: Axial View

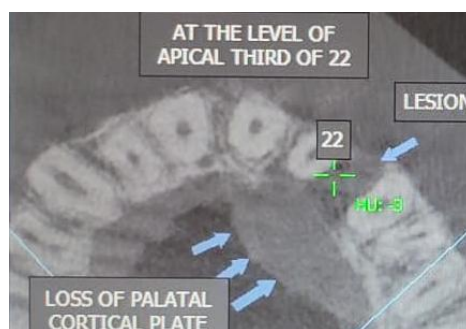


Fig h: CBCT Image: Axial View

REFERENCES

- [1]. Hülsmann M. Dens invaginatus: Aetiology, classification, prevalence, diagnosis, and treatment considerations. *Int Endod J* 1997; 30:79–90.
- [2]. Meghana SM, Thejokrishna P. Type III Dens Invaginatus with an Associated Cyst: A Case Report and Literature Review. *Int J Clin Pediatr Dent*. 2011 May-Aug;4(2):139-41.
- [3]. Luciana de Souza Falcão, Priscila Sousa de Freitas, Raquel de Oliveira Marreiro, Ângela Delfina Bittencourt Garrido Management of Dens Invaginatus Type III with Large Periradicular Lesion *The Journal of Contemporary Dental Practice*, January-February 2012;13(1):119-124
- [4]. Mupparapu M, Singer SR. A review of dens invaginatus (dens in dente) in permanent and primary teeth: A case report in a microdontic maxillary lateral incisor. *Quintessence Int* Feb 2006; 37(2):125-29.
- [5]. Thakur S, Thakur NS, Bramta M, Gupta M. Dens invagination: A review of literature and report of two cases. *J Nat Sci Biol Med* 2014; 5:218–21.
- [6]. More CB, Patel HJ. Dens Invaginatus: A radiographic analysis. *Open Access Sci Rep* 2012; 1:147.
- [7]. Nandini, D. B.; Wairokpam, Bhoomika Devi, Singh, Koijam Sashikumar, Mall, Braj Bhushan. Radicular Cyst Associated with Type 3B Dens Invaginatus in a Permanent Maxillary Lateral Incisor. *Journal of Microscopy and Ultrastructure* 2024;12(2): p 94-98.



- [8]. Galindo-Moreno PA, Parra-Vázquez MJ, Sánchez-Fernández E, Avila-Ortiz GA. Maxillary cyst associated with an invaginated tooth: A case report and literature review. *Quintessence Int* 2003;34(7):509-14.
- [9]. Pallivathukal RG, Misra A, Nagraj SK, Donald PM. Dens invaginatus in a geminated maxillary lateral incisor. *BMJ Case Rep*. 2015; 22
- [10]. Zubizarreta Macho Á, Ferreiroa A, Rico-Romano C, et al. Diagnosis and endodontic treatment of type II dens invaginatus by using cone-beam computed tomography and splint guides for cavity access: a case report. *J Am Dent Assoc* 2015; 146:266–70.
- [11]. Canger EM, Kayipmaz S, Celenk P. Bilateral dens invaginatus in the mandibular premolar region. *Ind J Dent Res* 2009;20(2):238-40.
- [12]. Lichota D, Lipski M, Woźniak K, Buczkowska-Radlinńska J. Endodontic treatment of a maxillary canine with type 3 dens invaginatus and large periradicular lesion: A case report. *J Endod* 2008;34(6):756-58.