



Did we miss something inside? Delayed diagnosis of Gossypiboma always a norm after abdomino-pelvic surgery?

Dr Mohini Abreo, Dr Sheikha Al Jabri, Dr Yasser ARazek Mohammed

MBBS, DGO, MD, Consultant OBGYN, Sohar Hospital, Oman

BSC MD FRCS AAGL, Head of the department, Obstetrics and Gynecology, Consultant OBGYN, Sohar Hospital, Oman

MSc, MD/PhD Edir, ABRMI, Radiology Department, Sohar Royal Hospital, Oman

Submitted: 20-09-2022

Accepted: 30-09-2022

ABSTRACT: Gossypibomais an infrequent surgical complication with uncertain incidence varies from 1 in 8801 to 18760. Human factors play an important role in this iatrogenic condition. The serious legal implications involved with this condition leads to under reporting. True incidence remains unknown as a result. The mass or the lesion is formed by foreign-body reaction due to A retained surgical swab/mop/ foreign body (RFB) leads to a foreign body reaction forming a mass or a lesion presenting as a growth/neoplasm which causes delayed diagnosis. Clinical history and physical examination should be the key to differential diagnosis. Abdominal and pelvic surgeries are the most common associated with Gossypiboma but can also occur after prostate surgery and others.

We report two cases of gossypibomawith delayed diagnosis. We have described the newer technology to help in minimizing the incidence of retained swabs and make early and timely diagnosis in case of forgotten swab.

Case 1: A 53-years-old woman presented with abdominal wound infection after hysterectomy with umbilical hernia repair. She had removal of RFB and 6 inches of small bowel resected with end-to-end anastomosis.

Case 2: A 34-year-old primigravida had spontaneous vaginal delivery followed by severe PPH due to atonic uterus. She ended up in hysterectomy after all measures failed. Retained swab was detected on routine physical examination and removed in OPD without any difficulty.

Any postoperative patient who presents with pain, foul smelling vaginal discharge, sign of persistent surgical site infection, or palpable mass, Gossypiboma should be the first differential diagnosis.

Preventive measures and early detection can lead to reduction of severe morbidity and definitive management. High degree of suspicion and early diagnosis is the key to reduce morbidity.

I. INTRODUCTION

In retained foreign bodies (RFB), a retained surgical mop /sponge is the most common which is termed as Gossypiboma. Gossypiboma comes from cotton (Gossy) and place of concealment (boma) which is Latin and Swahili respectively. Sentinel event data base of the joint commission shows a steady rise in these cases therefore a re-emphasis on the prevention of human errors leading to this condition is the need of the hour. This will help in minimizing litigation, cost implication following that and most importantly the morbidity related to this.

RFB can present as follows :

1. Exudative inflammatory reaction leading to abscess which is usually detected and managed early as these cases present early.
2. A sterile mass can form as a fibrotic reaction to the cotton material which can lead to a delayed and missed diagnosis as they usually are asymptomatic. The clinical presentation of patient with a RFB varies widely, often depends on the type of body response and time elapsed between the operation and the detection. Complications such as intestinal obstruction, perforation, intra-abdominal abscesses, and fistulae formation have been described. Other vague presentations which may present as abdominal distention and pain.

Within the abdominal cavity the swabs often surrounded by the omentum and intestines, which attempt to encapsulate it and try to limit the inflammatory reactions. The pressure and irritation can be exerted on the bowel loops which leads to necrosis of the intestinal wall leading to fistula and bowel obstruction. Presenting symptoms can be abdominal pain, nausea, vomiting, anorexia, and weight loss resulting from malabsorption due to obstruction or multiple intestinal fistulas or intraluminal bacterial overgrowth.



II. CASE PRESENTATION

Case 1: A 53-year-old woman presented in the accident and emergency department three weeks after abdominal surgery with diffuse abdominal pain, surgical site wound discharge, nausea, anorexia and constipation (which responded to laxatives). She had a total abdominal hysterectomy with bilateral salpingo-oophorectomy and umbilical hernia repair with a mesh abroad. The indication for her hysterectomy was simple endometrial hyperplasia.

She was discharged on day 3 and was readmitted with wound infection after few days. She was treated with antibiotics and she returned to

Oman after two weeks of surgery. She presented to Sohar hospital after three weeks with the above complaints.

Her vital signs were normal and was afebrile. On abdominal examination, there was purulent discharge from the abdominal wound at the repair site of umbilical hernia. There was mild tenderness all over the abdomen.

Routine laboratory tests were normal including the inflammatory markers. Abdominal X-ray was performed which was suggestive of retained surgical swab. A CT scan was also performed which confirmed the diagnosis.

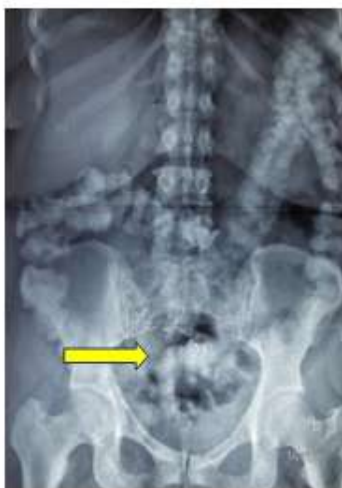

Fig 1 Abdominal X ray showing radiopaque serpiginous thread in the pelvic region

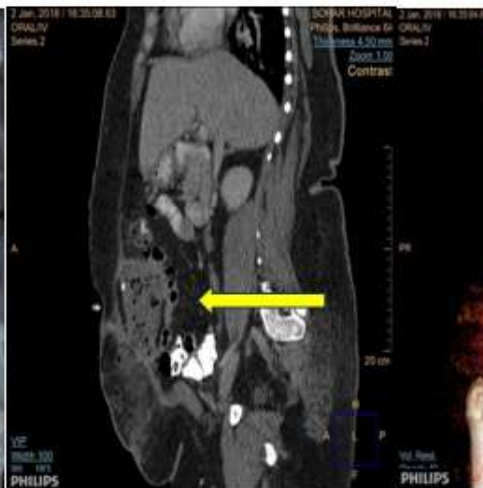


Fig 2 sagittal CECT of abdomen & pelvis showing mass of mixed densities adherent to anterior abdominal wall with fat

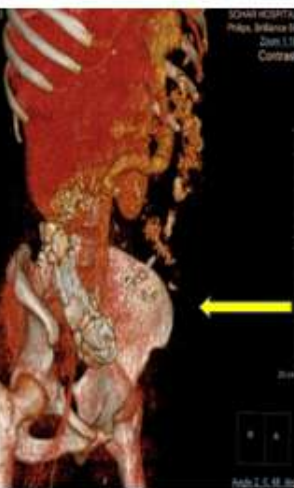


Fig 3 -CECT of the abdomen and pelvis, 3D reformats, showing intraabdominal hyperdense serpiginous threads

Exploratory laparotomy involving the multidisciplinary team (senior gynecologist and surgeon) revealed an encapsulated swab surrounded by omentum and bowel. It was also

noted that six inches of small bowel had areas of ischemia and necrosis with a purulent coating. Therefore, resection and anastomosis were performed. Postoperative course was uneventful.

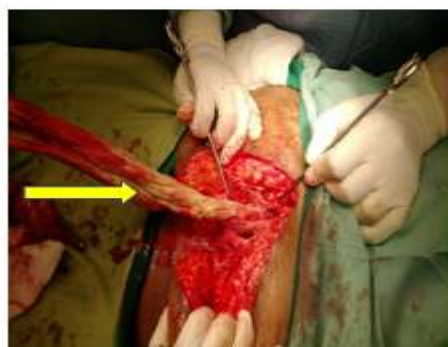

Fig 5
Surgical mop which was removed



Case 2: A 34-year-old primigravida had spontaneous vaginal delivery followed by severe PPH due to atonic uterus. She ended up in hysterectomy after all measures failed. There were few senior obstetricians were involved as a team. As operation was time consuming there were shift change of the theatre staff during the operation. We used many surgical mops which were counted correctly at the end of the operation. She was transfused with 6 units of blood and FFP. She made a full recovery and discharged home in 6 days. She came for the routine follow-up in 4 weeks just to make sure her she is recovering well. She was asymptomatic and her vitals were normal apart from some vaginal discharge which was thought to be normal. Abdominal examination was normal. Speculum examination suggested foul smelling discharge with a greenish discoloration noted in the posterior fornix. A HVS was taken and little exploration suggestion a greenish colour tissue like structure which was pulled with the sponge holder. To our surprise large amount of substance which looked like cotton was removed in entirety (this was a remnant of the swab which had been used during the operation). A CT scan was organized to make it has been completely removed. All inflammatory marker were within normal limits. She was allowed home after normal CT scan of the pelvis. She was given a course of antibiotics to cover both gram positive and negative was started.

Her notes were reviewed to see whether the swab count was normal and confirmed it. She was counselled and likely explanation was given regarding the likelihood of RFB and apology were made. She had no symptoms on further follow up and discharged from the clinic.

III. DISCUSSION

Persistent pain, vaginal discharge, palpable mass and any symptoms or signs of inflammatory process after a surgery should arouse a suspicion of Gossypiboma. Both patients had no signs of sepsis and one woman was on prolonged use of antibiotics since discharge from the hospital due to surgical site infection.

Abdominal plain X Ray is the usual diagnostic modality. A globular mass with a dense central part and an enhancing wall is the usual finding in CECT scan

If there is a suspicion of lost surgical swab during the intra or immediate post-operative period., immediate X-ray is done. The clinicians perceive that the radiograph can easily detect the retained swab, however, this is not often the case. Intraoperative radiographs can be of poor quality

and identification can be very difficult (especially in obese patients).

At a later stage the surgical swabs or RFB may become twisted or folded between the bowel/tissues and present as an unusual image. It can be misinterpreted as calcifications, intestinal contrast material, wires, or surgical clips. In our first case it was misinterpreted by the clinician as mesh that was used for the hernia repair. However, CT scan accurately diagnosed it as a surgical swab.

The usual treatment of a RFB is removal of the swab and the proper exploration of the bowel and abdominal cavity. There are cases of missed small bowel perforation in cases of mini laparotomy where the entire length of bowel is not explored.

High degree of suspicion of RFB must be considered in any postoperative patient who presents with pain, infection, or palpable mass. Identifying a swab in an intraoperative radiograph is difficult. CT scan is the best diagnostic modality of a RFB.

Complication during surgical removal of RFB is missed perforation of adherent bowels, hence involvement of senior surgeons during removal and thorough exploration of the bowels should be carried out.

The risk factors may include emergency surgeries/procedure by fatigued surgeons, unexpected change in the surgical procedure, involvement of multiple surgical teams, change in nursing staff during procedure due to shift change, multiple procedure being done at a time, body mass index (BMI). Other human factors are distraction, lack of leadership, multitasking, mis-communication, time pressure leading to false correct counts.

In our case most likely cause was that the gynecology team performed the hysterectomy and bilateral salpingo-oophorectomy and handed over the case to the surgeons for umbilical hernia repair. In second case due to continued PPH patient ended in hysterectomy with the involvement of multiple surgeons and change of theatre staff.

In 88% of the cases the counts were falsely called correct at the end of the procedure. It is recommended that "radiographic screening" at the end of high-risk cases as a possible adjunct to improve detection of RFB.

Only radiologically detectable swabs and towels should be used in the surgical site. Only large swab should be used after opening the abdominal cavity and all smaller swabs should be discarded. A thorough count and search should be done for all the instruments and surgical swabs before and after the procedure.



In order to decrease the incidence of RFB newer technologies are constantly being developed.

1. Bar codes which can be scanned and counted by an electronic surveillance system are applied on the mops

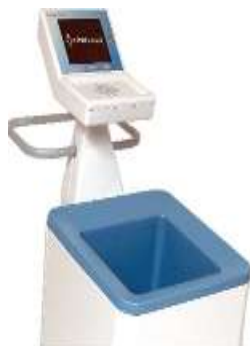

Fig 5: RFID surgical sponge tracking



Fig 6: RF detect sponge

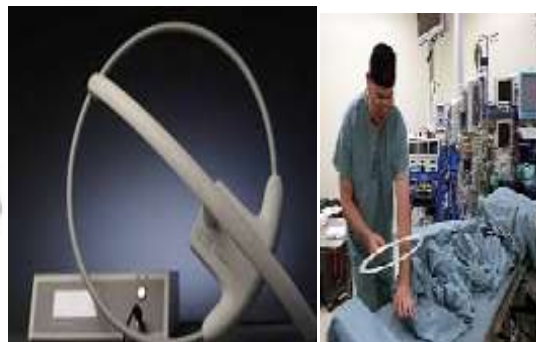

Fig 7 and Fig 8; Magic wand

How to reduce Medico-legal problem:

A lack of reasonable care and skill, or willful negligence on the part of a doctor in the treatment of a patient whereby the health or life of a patient is endangered defines medical negligence/malpractice.

- A private complaint is entertained only when the complainant produces prima facie evidence.
- ‘Res ipsa loquitur’ this doctrine means ‘The accident speaks for itself or tells its own story’
- A more complete reporting of such events with root cause analysis is necessary to reduce such complications. Confidentiality and anonymity allows a more accurate reporting system without fear of litigation. An anonymous reporting system leads to more diligent reporting without fear of litigation, and this allows a more accurate assessment of the incidence and causes of these events.

IV. CONCLUSION

Gossypiboma or retained surgical swab is a post-operative complication associated with significant morbidity and medico-legal implication. This can be prevented by adherence to the Joint commission and WHO recommendations in prevention of RFB. Clinical presentation coupled with high index of suspicion is the key to early diagnosis. CT scan should be the diagnostic modality of choice. Laparotomy with MDT is the treatment and during retrieval of the surgical swab/mop entire bowel to be explored to

2. The use of radiofrequency identification systems holds much hope for application in this area.

rule out perforation. Newer technologies can eliminate the human error.

Abbreviations

BMI-Body mass index

RFB -Retained foreign body

CECT- contrast enhanced Computed topography

MDT-Multidisciplinary team

REFERENCES

- [1]. Gibbs VC, Coakley FD, Reines HD: Preventable errors in the operating room: retained foreign bodies after surgery. *Curr Probl Surg*. 2007, 44: 281-337. 10.1067/j.cpsurg.2007.03.Pub Med.
- [2]. Fabian CE: Electronic tagging of surgical sponges to prevent their accidental retention. *Surgery*. 2005, 137: 298-301. 10.1016/j.surg.2004.Pub med
- [3]. Haaga J R, Boll D. CT and MRI of the whole body. Mosby(2009) ISBN, 032305375
- [4]. Imaging of retained surgical items: A pictorial review including new innovations *Indian J Radiol Imaging*, 2017 Jul-Sep, 27(3):354- 361 doi: 10.4103/ijri.IJRI 31 17
- [5]. Retained Surgical sponges: a descriptive study of 319 occurrences and contributing factors from 2012-2017. *Patient safety in surgery* volume 12, Article number. 20(2018) <https://doi.org/10.1186/s13037-018-0166-0>



- [6]. WHO Guidelines for safe surgery 2009(Patient Safety) Safe surgery saves lives
- [7]. †The Joint Commission. Sentinel Event Alert, Issue 60: Developing a reporting culture: Learning from close calls and hazardous conditions.[www.jointcommission.org/sentinel event alert](http://www.jointcommission.org/sentinel_event_alert). February 1,2019