



Endodontic Management of Aberrant Mandibular Premolars: A Report of Two Cases

Rachana mishra¹; Anushree jain¹

Senior lecturer, Department of Conservative Dentistry and Endodontics,
Daswani Dental College and Research Centre, kota

Submitted: 01-05-2021

Revised: 18-05-2021

Accepted: 22-05-2021

ABSTRACT: Prior to initiation of endodontic treatment possibility of extra roots and canals should be considered. The incidence of three canals in mandibular second premolar has been found to be between 0.46-0.5%. The present series describes nonsurgical endodontic treatment of a mandibular second premolar having three canals and three roots and a mandibular first premolar having two roots and three canals. In the first case, three orifices were located and in the second case a single orifice which bifurcated into two canals in the coronal portion and then one canal further divided into two and three canals exited from the apex was seen. With good operator skill and knowledge of root canal anatomies, teeth with extremely complex root canal morphologies can have successful treatment outcome even if treated non-surgically.

Keywords: mandibular premolars, complex root canal anatomy, sonic irrigation, Self-adjusting file (SAF), Hyflex.

I. INTRODUCTION

The primary goal of endodontic therapy is thorough chemical and mechanical debridement of the root canal system followed by three dimensional obturation using an inert filling material. There are several reasons for failure of endodontic treatment such as incomplete obturation, inadequate canal instrumentation, and untreated major canals. In addition to this failure to locate additional canals may result in poor outcome and cause acute flare ups during and after treatment¹.

It is important that the clinician has thorough knowledge of morphological divergence in the root canal system and an understanding of normal anatomy and variations. Mandibular premolars are the most common teeth to have varied anatomical configurations. According to Vertucci, second premolar with one root canal at the apex was found in 97.5% cases and two canals in only 2.5% cases; however, three root canals were very rarely found². Also mandibular premolars

with two canals have been commonly found in 1.6% of Caucasians and 2.6% in Negroids³. Despite of the scarce prevalence, the clinician should be aware of the clinical and radiographic anatomy of such teeth.

The purpose of present case series was to discuss the treatment recommendations of a mandibular second premolar having three canals and three roots and a mandibular first premolar having two roots and three canals.

II. CASE REPORT-1

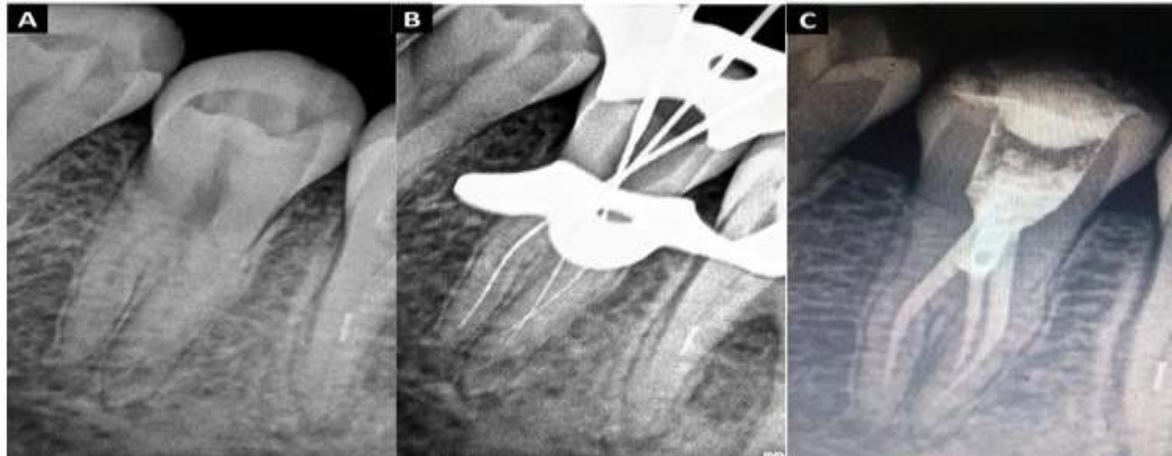
A 22 year-old female, with a non-contributory medical history reported to the dental college for endodontic treatment on the left mandibular second premolar by her general dentist. The chief complaint of the patient was -pain in the lower left back tooth since 2 weeks. Clinical examination revealed temporized left mandibular second premolar, tooth 35. Teeth 36 and 34 were in normal contact with tooth 35. Vitality tests like EPT and cold test were done, both of which showed lingering pain for more than 30 seconds after removal of stimulus. Tooth 35 had sharp, lingering pain to cold testing with ice-stick, no pain to percussion and palpation. No gingivitis or periodontitis was observed. Preoperative radiographs were taken and a possibility for aberrant root canal morphology was suspected. Indistinct definition of root anatomy on mesial and distal angulation radiographs showed the presence of additional roots. An abrupt loss of radiolucency of the main canal, suggested an extra canal in the same root or in the other independent roots. A diagnosis of Vertucci's type VIII root canal configuration with asymptomatic irreversible pulpitis was given. Non-surgical root canal treatment was the planned in the tooth over two visits with the use of calcium hydroxide as inter-appointment, intra-canal medicament.

Local anesthesia using an inferior alveolar nerve block was administered using 1.8 ml of 2% lidocaine hydrochloride (HCl) with 1: 100,000 epinephrine (Lignospan Standard; Septodont,



Lancaster, USA). After isolating the tooth using a rubber dam, temporary restoration was removed which showed an access cavity (Fig-1B), a DG 16 explorer (Dentsply Maillefer, Ballaigues, Switzerland) was used to locate the canal orifices, and 3 canal orifices were detected. Working length was determined using an Apex Locator (Root ZX

Mini; J. Morita Mfg. Corp., Kyoto, Japan). Periapical radiographs in different angulations confirmed the presence of the 3 roots and 3 canals; 2 buccal roots (with one canal in each root, i.e. mesiobuccal MB and distobuccal DB canals) and 1 lingual root (with one lingual L canal) (Fig-1B).



Once confirmed, root canal orifices were enlarged and straight-line access was improved using Gates-Glidden drills (Dentsply Maillefer). All the three canals were negotiated using stainless-steel, precurved 10 K files (MANI Inc, Tochigi, Japan) and the working length was confirmed on periapical radiographs. Patency was achieved in all the canals and was maintained with a 10 k file. All the canals had separate portals of exit. Biomechanical preparation was done using Hyflex rotary system (Coltene Whaledent, pvt, ltd). Calcium Hydroxide (RC Cal, Prime Dental Products Pvt Ltd) was used as intracanal medicament and the access cavities were sealed between appointments. The patient was seen after 4 weeks for the completion of the treatment. All the symptoms had ceased.

Calcium hydroxide was removed from the canals with ultrasonic activation of 17% EDTA and 5.25% hypochlorite. All the canals were negotiated, cleaned, and shaped to a size 30; .04 taper with pre-curved HyFlex CM (controlled memory) files (Coltene/Whaledent). Canals were prepared upto size 30; .04 taper. Irrigation was carried out using 5.25% sodium hypochlorite (NaOCl) (Prime Dental Products Private Limited) solution and 17% ethylenediaminetetraacetic acid (Largal Ultra Septodont Healthcare India Pvt Ltd) with saline as a final rinse.

Sonic irrigation was performed by using a Rispionic file attached to a MM 1500 sonic

handpiece (Medidenta International, Inc, Woodside, NY) after canal shaping. The canals were dried with sterile paper points (Dentsply Maillefer), and obturation was completed using 30; .04 gutta-percha cones fitted to length (Dentsply Maillefer) along with AH Plus resin sealer (Dentsply Maillefer, Konstanz, Germany). Each canal was obturated independently. The tooth was restored with composite resin, and a postoperative radiograph was taken (Fig-1C).

CLINICAL CASE -2

A 15 year old female patient reported to the endodontic department with a chief complaint of pain in the lower right back region of the jaw since one month. Her medical history was non-contributory. After local anaesthesia and rubber dam placement, root canal treatment was initiated with pulp chamber access and chemomechanical preparation of the root canals was carried out for tooth 28. Clinical examination revealed a deep carious lesion involving the disto-occlusal surface of the tooth. Vitality tests like EPT and cold test, depicted that the tooth 28 had sharp, lingering pain even after removal of stimulus. No pain to percussion and palpation. Different angulation preoperative radiographs suspected an unusual root canal morphology (Fig-2A).

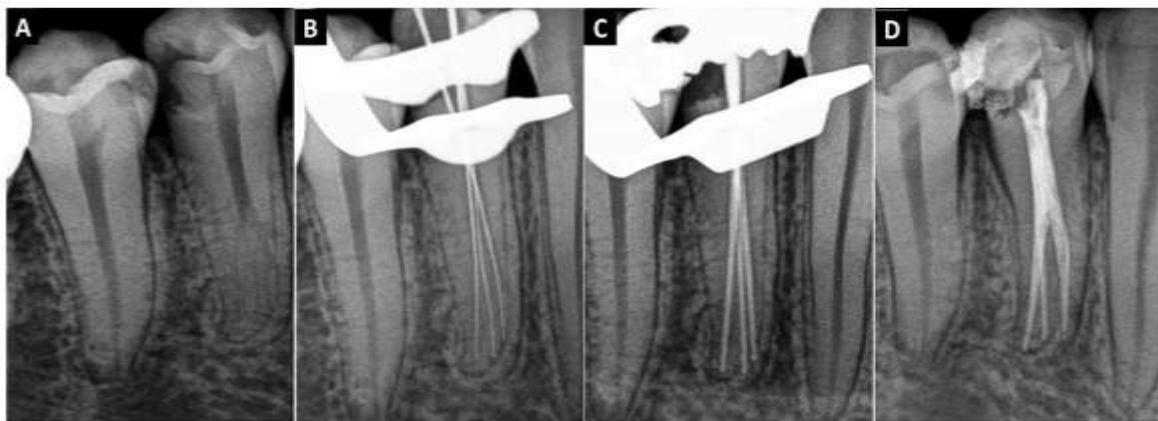
A diagnosis of Gulabivala's type III root canal configuration (Type III (2-3)): The pulp space separates into two canals in the coronal portion and



then one canal further divides into two and exit as three canals from the apex). Pulpal diagnosis was given as asymptomatic irreversible pulpitis. Non-surgical root canal treatment was planned in the tooth over two visits with the use of calcium hydroxide as inter-appointment, intra-canal medicament. Length was measured with the help of Root ZX electronic apex locator (J. Morita, Kyoto, Japan) and size 10 K-File (Dentsply Maillefer, Ballaigues, Switzerland) and confirmed with a periapical radiograph (Fig-2B). Biomechanical preparation was carried out initially using K files (Mani Inc, Japan) upto size 25. Due to complex root canal configuration, the instrumentation was

performed using the Self-Adjusting File (SAF) system (ReDent-Nova, Israel) in order to achieve meticulous cleaning of the canals. SAF (1.5 mm diameter and 25 mm length) was used for each canal. Irrigation was carried out for 4 min with 2.5% NaOCl solution at a 4 ml/min flow rate, as suggested by the manufacturer.

Obturation was completed with gutta percha using cold lateral condensation technique along with AH plus root canal sealer (Fig-2: C, D). Composite (Z250, 3M, ESPE, USA) post-obturation restoration was done.



III. DISCUSSION

Root canal morphology of mandibular premolars is complex and hence these are considered to be an enigma to an endodontist. The incidence of two roots in mandibular first premolars was found to be 1.8%. Two or more canals were found in 24.2% of the teeth studied and 21.1% had two or more apical foramina [4]. Whereas, the incidence of 2 roots (0.3%) and 3 roots (0.1%) was extremely rare in the mandibular second premolars. Approximately 9.0% have 2 or more canals and 2 or more foramina occurred in 8.2% of the cases.⁵

In the first case, due to the complex anatomy, Hyflex CM was used, due to their increased fatigue resistance and flexibility without the restoring forces of other files. In the second case the SAF system was used where a hollow file is operated with continuous irrigation provided by a special irrigation device (VATEA). The irrigation fluid enters the file through a free-rotating hub and is continuously replaced throughout the procedure, thus providing a fresh, fully active, supply of sodium hypochlorite. The use of advanced diagnostic aids such as cone beam computed

tomography and dental operating microscope would have proven to be a useful adjunct, which was a drawback in these two reported cases.

IV. CONCLUSION

Predictable and successful endodontic treatment requires knowledge of normal anatomy and variations. Complex root canal anatomy is commonly seen in mandibular premolars. Use of advanced diagnostic techniques along with conventional radiography can help improve the endodontic outcome of such cases.

REFERENCES

- [1]. Krasner, P., & Rankow, H. J. (2004). Anatomy of the pulp-chamber floor. *Journal of endodontics*, 30(1), 5-16.
- [2]. Vertucci, F., Seelig, A., & Gillis, R. (1974). Root canal morphology of the human maxillary second premolar. *Oral Surgery, Oral Medicine, Oral Pathology*, 38(3), 456-464.
- [3]. Amos, E. R. (1955). Incidence of bifurcated root canals in mandibular bicuspids. *Journal*



- of the American Dental Association (1939), 50(1), 70-71.
- [4]. Cleghorn, B. M., Christie, W. H., & Dong, C. C. (2007). The root and root canal morphology of the human mandibular first premolar: a literature review. *Journal of Endodontics*, 33(5), 509-516.
- [5]. Cleghorn, B. M., Christie, W. H., & Dong, C. C. (2007). The root and root canal morphology of the human mandibular second premolar: a literature review. *Journal of Endodontics*, 33(9), 1031-1037.
- [6]. Chaniotis, A., & Filippatos, C. G. (2017). The Use of a Novel Approach for the Instrumentation of a Cone-beam Computed Tomography–discernible Lateral Canal in an Unusual Maxillary Incisor .Case Report. *Journal of endodontics*, 43(6), 1023-1027.