



## Immunohistochemical study of inducible nitric oxide synthase (INOS) in odontogenic keratocyst and Ameloblastoma

Amr Mustafa Kamal, Prof. Dr. Azza A. El-Sissi, Prof. Sherief Youssaf  
Elnagdy, Dr. Mona Mohsen

<sup>2</sup>Student, faculty of Dentistry Mansoura university .

Date of Submission: 20-12-2023

Date of Acceptance: 30-12-2023

**ABSTRACT:** Odontogenic lesions comprise a group of lesions that affect the jaw with different biological behaviour. Odontogenic keratocyst (OKC) is benign interosseous lesion with aggressive behaviour and highly recurrent rate. Ameloblastoma (AB) most clinical aggressive odontogenic tumor. This study will pave the way for more information about role of INOS in the biological behaviour of OKC, and AB.

23 formalin paraffin tissue blocks of OKC, and AB were included in this study. All lesions were immunohistochemically examined for presence of INOS intensity and evaluated mean percentage of positive cells by image analysis. There was no significant difference between OKC and AB according to INOS intensity P value in INOS > 0.05. INOS expression can be used to differentiate between OKC and AB. It is hard to predict clinical behaviour.

**KEYWORDS:** Odontogenic keratocyst (OKC), Ameloblastoma (AB), INOS immunohistochemistry

### I. INTRODUCTION

Odontogenic cysts and tumors have a diverse spectrum of biological behaviour that develop in the jaw bones or soft tissue. The clinical presentation, radiographic appearance, and natural history of these lesions vary considerably. These lesions lifestyle of patients with complaints of loose teeth, changes in bite, and difficulty in eating, speaking, and swallowing. They often present with progressive mandibular or maxillary expansion and facial asymmetry without pain except when secondarily infected (1). Odontogenic keratocyst (OKC) has been reinstated as the preferred term for this simple keratinizing cyst. There is a large literature-recording debate around the putative neoplastic nature of this lesion. (2) Ameloblastoma (AB) is the most clinically significant odontogenic tumor. AB is a slow-growing tumor that runs a benign course in most cases; however, it is locally invasive and destructive. (3)

Nitric oxide (NO) is a gaseous molecule that has a vital role in signalling pathways involved

in numerous physiological processes (e.g., vasodilation, inflammation, apoptosis, and tumor growth). NO seems to be both tumor-promoting and tumoricidal. (4) The amount of NO generated, time, and site vary and are important determinants of the biological effects initiated. Inducible nitric oxide synthase (INOS) is primarily transcriptionally regulated and is not regularly expressed in most human tissues. Numerous researches have also examined the distinctive role of INOS in a variety of human malignancies, given the complex roles that NO plays in the initiation and progression of cancer. (5)

### II. MATERIAL AND METHODS

I. Tissue samples: This study was retrospectively applied on 23 formalin-fixed and paraffin-embedded tissue blocks (10 OKC and 13 AB), collected from archival files of Oral Pathology Departments Faculties of Dentistry, and Medicine, Mansoura University. Ethical approval was obtained from the Research Ethics Committee of the Faculty of Dentistry, Mansoura University. Immunohistochemical markers: Human INOS: is an affinity-purified rabbit polyclonal antibody obtained from Thermo Scientific, Wuhan, Hubei, China. Four serial tissue sections were cut at 4  $\mu$  thickness. Sections were deparaffinized in xylene and rehydrated in ethanol with descending concentrations.

The MOSFETs used are (IRF3205) which act as current amplifiers and amplify the current from 1 amp to 3 amps. Two solenoids are placed on the inlet and exhaust valves the piston of the solenoid is directly connected to the valve using a rubber tubing for motion transfer. Each solenoid consists of two set of copper windings with 12 mm dia, 20 turns and 8 layered both the solenoid are oppositely connected and when actuated two sets of opposite windings get magnetized, the piston inside solenoid moves up closing the valve the alternate valve is opened. The solenoids are rigidly placed over the cylinder head with the help of wood powder and glue which turns into concrete strong



upon drying up. A solenoid is simply a specially designed electromagnet. A solenoid usually consists

Antigen Retrieval was performed. Slides were immersed in citrate buffer (10 minutes), heated, blocked (30 minutes) and finally the slides were incubated in 4.0% rabbit serum for 15

minutes at room temperature then the solution was drained from the slides Evaluation of Immunohistochemical staining:

The immunoreactivity for INOS was semi-quantitatively assessed the intensity of staining of the cells of interest according to Cizkova K et al.(6) The Intensity was recorded from 0 to 3 representing: Negative, Weak, Moderate, and Strong respectively. To evaluate the percentage of positive cells, was also used mean of percentage area protocol. The Color Deconvolution Plug-in was downloaded into the ImageJ program and used to isolate positively stained areas from the total epithelial area as previously described For INOS stained sections according to Hammad et al. (7)

Statistical analysis: The clinical and laboratory data were recorded on an "Investigation report form." These data were tabulated, coded then analysed using the computer program SPSS (Statistical package for social science) version 17.0. Descriptive statistics were calculated in the form of mean, frequency (number-percent), median and interquartile range (IQR).

## II. RESULTS

INOS expression in OKC was detected in most cases where it was positive cytoplasmic reaction in basal and parabasal cells in 9 cases (90%) and one case negative reaction (10%) (fig1). All cases of the AB showed positive cytoplasmic reaction in both stellate reticulum like cells and the ameloblast like cells. It was strong reaction in seven cases (53.8%) and moderate reaction observed in 6 cases (46.2%) (fig2).

Statistical analysis of INOS expressions revealed that there was a no significant difference between groups for the score of intensity (Table)

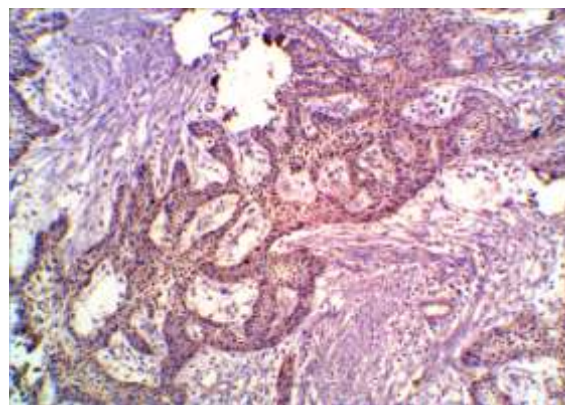


Fig 1: Photomicrograph showing Immunohistochemical expression of INOS in plexiform ameloblastoma in the peripheral cells and central cells (DAB x 200).

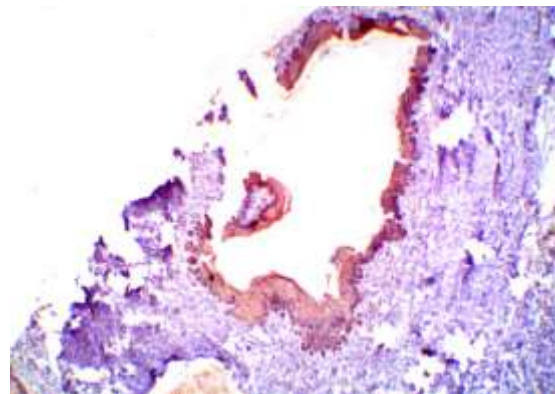


Fig 2: Photomicrograph showing Immunohistochemical expression of INOS in OKC with high positive cytoplasmic reaction in the basal and supra-basal layers (red arrow) (INOS x 200)



Table: INOS expression intensity score and mean of percentage area in OKC and AB:

Intensity	Group I (OKC) (n = 10)		Group II (AB) (n = 13)		P value
	Mean	%	Mean	%	
Negative	0.0	0	0.0	0	.372
Weak	0.0	0	0.0	0	
Moderate	0.0	6	0.0	3.8	
Strong	0.0	3	0.0	6.2	
Mean of percentage area					
Mean ± SD.	7.18 ± 2.70		9.2 ± 5.46		.499

P value = Statistically significant at  $p \leq 0.5$

### III. DISCUSSION

Odontogenic tumors and cysts have the same origin, but their biological behaviour is different and bizarre. Therefore, the present study was conducted to reveal the INOS immunohistochemical expression in OKC and AB and to reveal their varied aggressiveness and biological behaviour. As the results of our study were evaluated, the investigation focused on whether there was an obvious difference in terms of the immunoreactivity of INOS in the epithelial lining cells between OKC and AB.

In the present study, the mean age of OKC is 35 years, ranging from 12 to 70 years, with a peak of incidence in the third and fourth decades, which is comparable with international literature that reported a peak of incidence in the third and fourth decades (8, 9). Moreover, the mean age of AB cases showed a similar result to OKC cases (35 years). Similar findings were reported by Ghai S and Ilzgi E et al also showing the mean age was 33 to 38 years. (10, 11)

In the present work, the mandible is the most affected site in OKC and AB. These results are in agreement with nearly most of the reported English-language literature reviewing these lesions (12-14). This finding, supported by many other findings, resulted in having OKC and AB at

the top of the differential diagnosis list of posterior mandible lesions.

Although with variable intensity, the INOS protein was expressed in all currently studied lesions of OKCs, and AB indicating that epigenetic regulation by INOS proteins might drive the biological activity of these odontogenic lesions in a variable manner which contribute to the different behaviour of these lesions. The INOS expression was no significantly in the OKC group and AB group reflecting the most aggressive and invasive behaviour AB and OKC groups showed similar INOS expression. This suggestion supports the opinion of many researchers who insist that OKCs have a neoplastic potential rather than being cysts as considered in the WHO classification 2022. (15) The results of the present study were in favour of the study done by Jaafari-Ashkavandi Z et al using the markers p53 and MDM2 proteins in order to contribute to the similar biological behaviour of OKC and benign AB. (16) In the current study, the lack of a significant difference in INOS staining intensity between OKC and AB confirms the hypothesis that OKCs may represent a low-grade neoplasm rather than a developmental cyst. This notion is supported by other investigators thinking of OKC as being preferably classified as a neoplasm (16-18).



#### IV. CONCLUSION

Odontogenic lesions Over expression of INOS in AB cases is considered to be involved in neoplastic transformation. Therefore, the expression of INOS in OKC and in variants of AB suggests that an INOS inhibitor may play an important role in the treatment of odontogenic lesions. Further studies are needed to prove this therapeutic approach.

#### REFERENCES

- [1]. McClary AC, West RB, McClary AC, Pollack JR, Fischbein NJ, Holsinger CF, et al. Ameloblastoma: a clinical review and trends in management. *European archives of oto-rhino-laryngology : (EUFOS) : affiliated with the German Society for Oto-Rhino-Laryngology - Head and Neck Surgery.* 2016;273(7):1649-61.
- [2]. Bilodeau EA, Collins BM. Odontogenic Cysts and Neoplasms. *Surg Pathol Clin.* 2017; 10(1):177-22.
- [3]. Mendez LD, Wolsefer NS, Asa SL, Wasman J, Yoest JM, Stojanov IJ. The diagnostic utility of BRAF VE1 mutation-specific immunohistochemistry in ameloblastoma. *Modern Pathology.* 2022; 11: 35(11):1570-1577.
- [4]. Locascio A, Annona G, Caccavale F, D'Aniello S, Agnisola C, Palumbo A. Nitric Oxide Function and Nitric Oxide Synthase Evolution in Aquatic Chordates. *international Journal of Molecular Science* 2023;24(13): 82-111.
- [5]. Cinelli MA, Do HT, Miley GP, Silverman RBJMrr. Inducible nitric oxide synthase: Regulation, structure, and inhibition. *Medicinal Research reviews* .2020;40(1):158-189.
- [6]. Cizkova K, Foltynkova T, Gachechiladze M, Tauber Z. Comparative Analysis of Immunohistochemical Staining Intensity Determined by Light Microscopy, ImageJ and QuPath in Placental Hofbauer Cells. *Acta histochemica et cytochemica.* 2021;54(1):21-29.
- [7]. Hammad HM, Nagrash OM, Safadi RA. Maspin, Syndecan-1, and Ki-67 in the Odontogenic Keratocyst: An Immunohistochemical Analysis. *International Journal of Dentistry.*2020;1-8.
- [8]. Borghesi A, Nardi C, Giannitto C, Tironi A, Maroldi R, Di Bartolomeo F, et al. Odontogenic keratocyst: imaging features of abenign lesion with an aggressive behaviour. *Insights into Imaging.* 2018;9(5):883-897
- [9]. Elshafei MM, Afifi NS, Ghazy SE, Gad HA, Rasmy M. Odontogenic Keratocyst: A Review of Histogenesis, Classification, Clinical Presentation, Genetic Aspect, Radiographic Picture, Histopathology and Treatment. *Egyptian journal of Histology.* . 2022;45(2):325-337.
- [10]. Ghai S. Ameloblastoma: An Updated Narrative Review of an Enigmatic Tumor. *Cureus.* 2022;14(8):234-277..
- [11]. Izgi E, Mollaoglu N, Simsek M. Prevalence of Odontogenic Cysts and Tumors on Turkish Sample According to Latest Classification of World Health Organization: A 10-Year Retrospective Study. *Nigerian Journal of Clinical Practic.* 2021;24(3):355-361.
- [12]. Karaca C, Dere KA, Er N, Aktas A, Tosun E, Koseoglu OT, et al. Recurrence rate of odontogenic keratocyst treated by enucleation and peripheral ostectomy: Retrospective case series with up to 12 years of follow-up. *Medicina oral, patologia oral y cirugiabucal.* 2018;23(4):443-448.
- [13]. Kitisubkanchana J, Reduwan NH, Poomsawat S, Pornprasertsuk-Damrongsri S, WongchuensoontornCJOr. Odontogenic keratocyst and ameloblastoma: radiographic evaluation. *Oral Rdiology.* 2021;37:55-65
- [14]. Avril L, Lombardi T, Ailianou A, Burkhardt K, Varoquaux A, Scolozzi P, et al. Radiolucent lesions of the mandible: a pattern-based approach to diagnosis. *Insights Imaging.* 2014;5(1):85-101
- [15]. Vered M, Wright JM. Update from the 5th Edition of the World Health Organization Classification of Head and Neck Tumors: Odontogenic and Maxillofacial Bone Tumours. *Head and neck pathology.* 2022;16(1):63-75.
- [16]. Jaafari-Ashkavandi Z, Mehranmehr F, Roosta E. MCM3 and Ki67 proliferation markers in odontogenic cysts and ameloblastoma. *Journal of Oral Biology and Craniofacial Research.* 2019;9(5):47-50.
- [17]. Anusai V, Shylaja S, Suvarna M, Ramanand O, Reddy ES, Vamshi VRJDRJ. Immunohistochemical evaluation of myofibroblasts in



- odontogenic keratocyst, dentigerous cyst and different clinical variants of ameloblastoma: A comparative study. Dent Res J (Isfahan). 2021; 18-36.
- [18]. Pawar VM, Patel S, Pathak J, Swain N, Hosalkar R, IyerJJJoCD. Immunohistochemical evaluation of calretinin and cytokeratin-19 in odontogenic keratocyst and ameloblastoma: a retrospective study. Journal