



## In-Vitro Evaluation of Efficacy of Three Different Retreatment Systems in Removal of Gutta-Percha from Root Canal by Using Stereomicroscope

<sup>1</sup>Dr. Pradeep P R, <sup>2</sup>Dr. Subhasmita Panda, <sup>3</sup>Dr. Ananthakrishna S, <sup>4</sup> Dr. Claudia Dayanandini A, <sup>5</sup>Dr. Sowmya S

*1. Principal and Professor, Department of Conservative Dentistry and Endodontics M.R. Ambedkar Dental College and Hospital, Bangalore*

*2,4,5 Post Graduate Student, Department of Conservative Dentistry and Endodontics, M.R. Ambedkar Dental College and Hospital, Bangalore*

*3 Professor and Head of the Department, Department of Conservative Dentistry and Endodontics M.R. Ambedkar Dental College and Hospital, Bangalore*

*Corresponding Author : Dr. Subhasmita Panda, Department of Conservative Dentistry and Endodontics*

Date of Submission: 01-09-2025

Date of Acceptance: 10-09-2025

### ABSTRACT

**INTRODUCTION:** Successful root canal therapy depends on thorough cleaning, shaping, and three-dimensional obturation of the root canal system to achieve a hermetic seal. Despite reported success rates of 86–98%, failures may occur due to persistent infection, inadequate apical sealing, missed canals, insufficient cleaning, or procedural errors, necessitating nonsurgical retreatment. The primary objective of retreatment is to remove existing obturation material, disinfect the canal, and re-establish apical patency, thereby promoting periapical healing. Rotary nickel-titanium (NiTi) systems have significantly improved the efficiency, safety, and predictability of retreatment by facilitating effective removal of filling materials without the need for solvents, thus preventing smear layer formation that could hinder disinfection. Recently, advanced rotary systems such as the HyFlex Remover, NeoEndo retreatment file systems and Mani NRT GPR files have been developed with distinct design features aimed at optimizing gutta-percha removal, minimizing file fracture, and improving clinical outcomes. Limited evidence exists comparing the efficacy of these systems in removing obturation materials.

**AIM OF THE STUDY:** The present study was undertaken to evaluate and compare the effectiveness of HyFlex Remover, NeoEndo retreatment files, and Mani NRT GPR files in gutta-percha removal, with the goal of identifying the most reliable system for nonsurgical endodontic retreatment.

**MATERIALS AND METHODS:** Thirty extracted human mandibular premolars with fully formed apices and two distinct mesial canals were selected and stored in sodium hypochlorite. Teeth

with calcifications, resorption, prior treatment, fractures, caries, or anomalies were excluded. Soft tissue and calculus were mechanically removed. Access cavities were prepared, working length established (15 mm), and canals instrumented with the step-back technique to size 30 K-file at WL and size 45 K-file step back, with irrigation using 2.5% NaOCl and 17% EDTA. Canals were obturated with gutta-percha and AH Plus sealer via lateral compaction, verified radiographically, sealed with Cavit, and stored at 37°C and 100% humidity for 4 weeks. Specimens were randomly divided into three groups (n=10). Retreatment was performed without solvents using: HyFlex Remover (group 1), Neoendo Retreatment Files (group 2) and Mani GPR (group 3) Files. Retreatment was deemed complete when no material adhered to files or irrigant and canals were smooth to WL. Roots were sectioned longitudinally, and residual filling material was assessed at coronal (2 mm below CEJ), middle (8 mm from apex), and apical (1 mm above apex) thirds under a stereomicroscope (20×). Scores were assigned based on the proportion of remaining material.

**RESULTS:** Kruskal Wallis Test followed by Dunn's post hoc Test was used to compare the mean remaining obturating material scores between 3 groups at different regions. Friedman's Test followed by Wilcoxon Signed Rank Post hoc Test was used to compare the mean remaining obturating material scores between different regions in each group. The level of significance was set at  $p < 0.05$ . The test results demonstrated that, for the Coronal region, Group 1 has a mean score of 1.20 (SD: 0.42), Group 2 has 1.80 (SD: 0.63), and Group 3 has 1.90 (SD: 0.74). For the Middle region, Group 1 mean score was 1.80 (SD:



0.42), Group 2's is 2.30 (SD: 0.48), and Group 3's is 2.60 (SD: 0.52). For the Apical region, Group 1 has a mean score of 1.80 (SD: 0.42), Group 2 has 2.60 (SD: 0.52), and Group 3 has 3.50 (SD: 0.53).

**CONCLUSION:** Significantly less amount of filling material was present in Hyflex Remover treated teeth compared to Neo endo and Mani treated teeth.

**KEYWORDS:** Retreatment, Hyflex Remover, Neo Endo Retreatment files, Mani Retreatment files NRT GPR, AH Plus, Ezzie et al Scoring criteria, NiTi files.

## I. INTRODUCTION

The success of root canal therapy largely depends on achieving a three-dimensional fluid-tight seal throughout the root canal system. While this procedure proves effective in approximately 86–98% of cases, retreatment may become necessary in certain situations—such as an improper apical seal, remaining pulpal tissue, insufficient cleaning, missed canals, or inadequate obturation.<sup>1</sup>

Endodontic failures can occur even when treatment protocols are followed to the highest standards. Such failures are often linked to inadequate cleaning and shaping of complex canal anatomies, procedural errors, or an inability to achieve a hermetic seal—conditions that allow bacteria to persist or recolonize the root canal system. These microorganisms, along with residual necrotic tissue, are the primary contributors to periapical inflammation and pain. Bacteria, necrotic debris, and biofilms play a critical role in triggering inflammatory responses. During instrumentation, apical extrusion of debris may occur, potentially exacerbating inflammation. The goal of non surgical root canal retreatment is to thoroughly debride the canal system, thereby enabling the removal of microorganisms and necrotic tissue remnants. This, in turn, enhances the prognosis of the tooth.<sup>2</sup>

In non surgical root canal retreatment, thorough removal of existing root canal filling materials is required to enable proper disinfection and re-establish patency of the apical foramen. The primary objective of nonsurgical root canal retreatment is to achieve the resolution of periapical pathology and promote the regeneration of healthy periapical tissues. The primary etiological factor in the failure of root canal therapy is the persistence of microbial pathogens, particularly *Enterococcus faecalis*, within the complex anatomy of the root canal system.<sup>3-5</sup>

The prognosis of root canal therapy is significantly influenced by the anatomical

complexity of the root canal system, as well as tooth-specific factors that may pose challenges to effective debridement, disinfection, and obturation. Nonsurgical endodontic retreatment is generally considered the first-line therapeutic approach for endodontically treated teeth presenting with persistent apical periodontitis, owing to its effectiveness in eliminating intraradicular infection and its ability to preserve the integrity of dental structures.<sup>6-7</sup>

When evaluating the retrograde approach, several factors must be taken into account, including the proximity of the root apex to dental or nearby anatomical structures such as nerves and foramina, which can complicate the procedure. As a result, nonsurgical retreatment is often the preferred, more conservative treatment option in such situations. Nonsurgical retreatment is commonly regarded as the preferred approach for managing failed endodontic cases, with reported success rates ranging from 74% to 98%.<sup>8-9</sup>

Despite the introduction of various obturation materials in recent years, gutta-percha combined with a root canal sealer remains the most widely used option. A variety of techniques have been employed for the removal of gutta-percha from root canal systems, including the use of manual endodontic hand instruments, ultrasonic devices, laser-assisted methods, thermoplasticized or heat-carrying instruments, and nickel-titanium (NiTi) rotary systems.<sup>10</sup>

Traditionally, solvents have been used to dissolve gutta-percha during retreatment procedures. Commonly used solvents include chloroform, methylene chloride, eucalyptol, halothane, xylene, tetrahydrofuran, and others. However, both the Japanese Ministry of Health and Welfare and the U.S. Food and Drug Administration have classified chloroform as having carcinogenic potential.<sup>2</sup>

The resistance presented by existing filling materials can render nonsurgical retreatment a technically demanding and time-intensive procedure, particularly in cases involving curved root canals. Thorough removal of root canal filling materials during retreatment is essential, as residual material may serve as a barrier that protects persistent microorganisms implicated in post-treatment disease. If not adequately eliminated—particularly in the apical third—these bacteria can perpetuate periapical inflammation and clinical symptoms.<sup>4,11</sup>

Traditionally, removing gutta-percha with manual files, with or without the aid of solvents, has been a laborious and time-consuming task—particularly when the filling material is densely



compacted. As a result, rotary NiTi instruments have been employed to facilitate the removal of root canal filling materials. Multiple studies have highlighted their effectiveness, cleaning capability, and safety in this context. The use of NiTi rotary instruments in root canal retreatment may help reduce fatigue for both the patient and the operator. Several studies have demonstrated that nickel-titanium (NiTi) rotary instruments are a reliable and efficient option for removing root canal filling materials during endodontic retreatment.<sup>12,13</sup>

A key advantage of using rotary retreatment file is the ability to remove root canal filling material without the use of gutta-percha solvents. Avoiding solvents helps prevent the formation of a thin gutta-percha film on the canal walls, which could otherwise hinder the effectiveness of intracanal medicaments and compromise the adhesion of the root canal sealer during retreatment. Additional benefits of using rotary instruments include eliminating the need for potentially carcinogenic substances and reducing the risk of apical extrusion due to over-dissolution of gutta-percha.<sup>14,15</sup>

Numerous studies have evaluated various retreatment file systems, comparing the effectiveness of hand files and rotary files, both with and without the use of solvents.<sup>16</sup> However, there is currently limited data available on the performance of the recently introduced NeoEndo retreatment files and Mani NRT-GPR system. Certain NiTi systems developed specifically for retreatment possess distinct physical features—such as cross-sectional geometry, cutting angle, and the presence or absence of an active tip—which can influence the efficiency of gutta-percha and dentin removal from the root canal.<sup>17</sup>

The NRT-GPR, a relatively new rotary file system designed for gutta-percha removal, has been developed by Mani Inc. It features helical grooves along its working portion and is available in four sizes: 1S, 2S, 3N, and 4N. The 1S (size 70, 16 mm length, 0.04 taper) and 2S (size 50, 18 mm length, 0.04 taper) are stainless steel files intended for removing gutta-percha from the cervical and middle thirds of the canal. The 3N (size 40, 21 mm length, 0.04 taper) and 4N (size 30, 21 mm length,

0.04 taper) are nickel-titanium (NiTi) files designed for use up to the working length.<sup>9</sup>

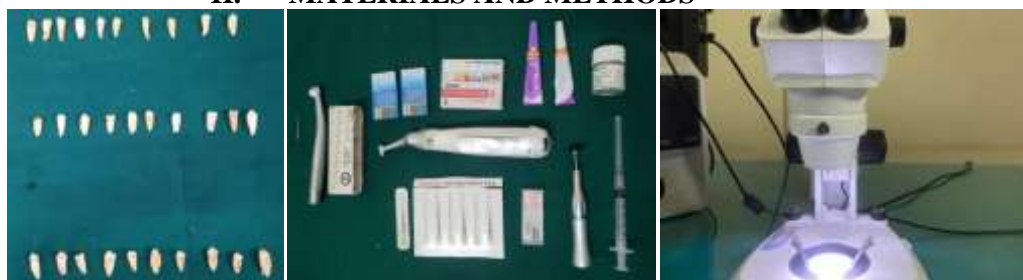The NeoEndo retreatment file system represents a recent advancement in rotary endodontic technology. It consists of three specifically designed files: N1 (size 30, 0.09 taper) for preparation of the coronal third, N2 (size 25, 0.08 taper) for the middle third, and N3 (size 20, 0.07 taper) for the apical third of the root canal. NeoEndo retreatment files are manufactured using proprietary heat treatment and microgrinding technology, which helps minimize the engagement zone. These files feature controlled memory, a parallelogram cross-section, and a positive cutting tip, all of which contribute to preventing ledge formation and reducing the risk of file fracture during retreatment. In comparison, HyFlex retreatment files are produced using an innovative, patent-pending technique that involves a specialized heating and cooling process to precisely control the material's memory.<sup>18,19</sup>

The recently introduced HyFlex Remover single-file retreatment system has simplified the retreatment procedure, offering greater convenience for clinicians. The HyFlex Remover retreatment system is commonly utilized in orthograde retreatment procedures. Developed in Switzerland, this system is specifically designed for effective retreatment and features a single file with a 7% taper and an apical diameter of size 30. It incorporates a minimally invasive 1 mm wire and is known for its high efficiency without the need for solvents. The file has non-cutting tips and is available in two lengths: 15.5 mm and 18.5 mm. The 15.5 mm version has an active blade only at the tip, whereas the 18.5 mm file features a blade that is active along its entire length.<sup>8,20</sup>

To date, no study has compared the retreatment efficacy of the HyFlex Remover, Neo Endo Retreatment files and Mani NRT GPR files, highlighting the need for this research. The objective of the present study was to evaluate and compare the effectiveness of these three systems—HyFlex Remover, Neo Endo Retreatment files and Mani NRT GPR retreatment files—in removing obturation material from root canals.



## II. MATERIALS AND METHODS



30 extracted mandibular premolar

Instruments and materials used

Stereomicroscope

A total of 30 human mandibular premolars recently extracted were selected and stored in sodium hypochlorite solution. The inclusion criteria involved teeth that presented fully formed apices, mesial roots with two completely separated canals from the orifice to the apex. Teeth that exhibited pulp calcifications, root resorption, previous endodontic treatment or root fracture, caries or developmental anomalies were excluded from the study. Soft tissue and calculus were mechanically removed from the root surfaces. The current investigation is an in vitro study where extracted teeth were used without any intervention/experimentation in human subjects.

Access cavities were prepared using round diamond burs mounted in a high-speed handpiece. After completing the access cavity preparation, size 10 K file was inserted in the root canal until it was just visible at the apical foramen. 1 mm was subtracted from this measurement to calculate the working length. The samples were decoronated subsequently to achieve a standard size of 15 mm by using a double diamond disc. A circumferential “staging platform” was established near the canal orifice, ensuring a uniform working length (WL) of 15mm in each tooth. Initial root canal treatment: Canal preparation was performed using step back technique to size 30 K file at working length, step back preparation was done till size 45 K file.

Irrigation was done between successive instruments with 5 ml sodium hypochlorite (2.5 %). On completion of instrumentation, canals were rinsed with EDTA (17 %) for 3 minutes, followed by final irrigation with 5 ml of sodium hypochlorite. Using the lateral compaction technique, the root canals were dried with paper points and obturated with gutta-percha and AH Plus sealer. The quality and extent of root fillings were evaluated with digital radiographs. Subsequently the access cavities were sealed with Cavit. The specimens were stored in an incubator at 37°C in 100% humidity for 4 weeks to allow the sealer to set completely.

Retreatment techniques: All specimen were retreated by a single operator. Teeth were randomly divided into 3 groups of ten specimen each (n=10). Temporary restorations were removed with size 4 round bur. Canals were irrigated with sodium hypochlorite (2.5 %). All instruments were discarded after use in five root canals. Retreatment was considered complete when no remnants of gutta percha and sealer were observed on instrument surface or in the irrigating solution, when the last file reached the working length, and the canal walls were smooth and free of visible debris.

### Neoendo Retreatment Files

Neoendo retreatment files were used in a sequential manner using a light apical pressure at a constant speed of 350 rpm and Torque: 1.5 N-cm as per the manufacturer’s instruction. Neoendo retreatment files N1 (size 30/0.09), N2 (size 25/0.08) and N3 (size 20/0.07) were used for the coronal, middle and apical one third respectively using crown down technique.

### Hyflex Remover

HyFlex Remover , a single file (size 30; 7% taper) was utilized to remove the obturation material, as per the instructions given by the manufacturer. Usage was carried out in pecking motions at 400 rpm with a torque of 2.5 Ncm.

### Mani Retreatment files

In the Mani GPR group, filling removal combined with simultaneous root canal preparation was initiated using the 1S instrument (size 70/0.04) and 2S instrument (size 50/0.04) in continuous rotation at 1000 rpm. The instrument was gradually advanced through the filling material along the straight portion of the canal until the curvature was reached, where it was maintained in activation for 1–2 seconds. This was followed by the use of the 3N instrument (size 40/0.04), which was advanced up to 2 mm short of the apex. And then 4N instrument (size 30/0.04) was used till the apex.



Assessment of the Efficacy of Rotary Files Systems in Removal of Gutta-percha

After the retreatment procedure, a diamond disc was used to separate the roots lengthwise. The amount of GP and sealer left was measured in three sections: At apical third (1 mm above the apex), middle third (8 mm from the apex), and coronal third (2 mm below the cemento-enamel junction). The samples were then examined using a stereomicroscope at a magnification of 20. Stereomicroscopes offer two primary benefits: the ability to analyze opaque specimens and the provision of a three-dimensional perspective of the sample.

The following scores were used to calculate the proportion of residual filler material in the root canal walls. (Ezzie et al)

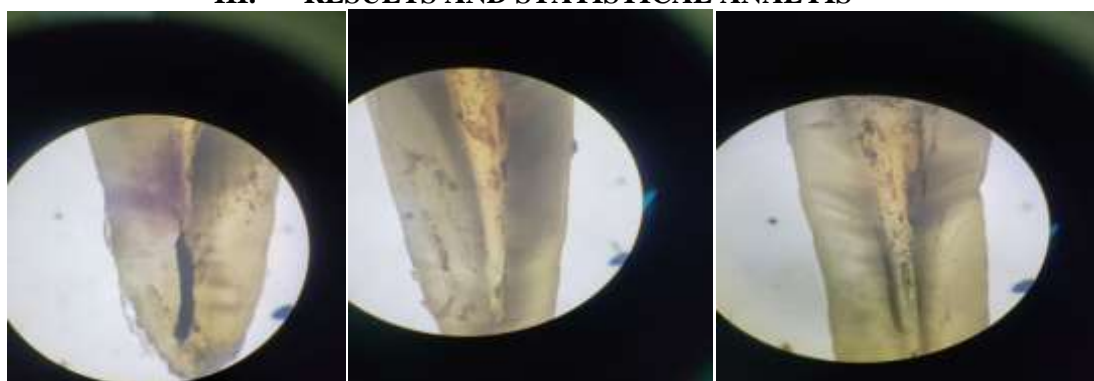
Score 1: No to minor presence of obturation debris (0–25%) on the dentinal surface.

Score 2: Some obturation debris (25–50%) on the dentinal surface.

Score 3: Moderate presence of obturation debris on the dentinal surface (50–75%).

Score 4: Obturation debris on the dentinal surface is abundant (>75%)

III. RESULTS AND STATISTICAL ANALYSIS



MANI FILES RETREATED NEO ENDO FILES RETREATED HYFLEX REMOVER FILES RETREATED

Comparison of mean Remaining Obturating material scores b/w 3 groups at different regions using Kruskal Wallis Test followed by Dunn's post hoc Test

Table with 10 columns: Region, Groups, N, Mean, SD, Min, Max, p-value, Sig. Diff, p-value. Rows include Coronal, Middle, and Apical regions for Groups 1, 2, and 3.

\* - Statistically Significant

Note: a. Kruskal Wallis Test & b. Dunn's Post hoc Test

Group 1: Hyflex Remover, Group 2: Neo-Endo Retreatment & Group 3: Mani Retreatment

The test results demonstrated that, for the Coronal region, Group 1 has a mean score of 1.20 (SD: 0.42), Group 2 has 1.80 (SD: 0.63), and

Group 3 has 1.90 (SD: 0.74).

The test indicates a significant difference among the groups (p=0.03). Dunn's post hoc test

shows significant differences between Group 1 with Groups, 2 and 3.

For the Middle region, Group 1 mean score was 1.80 (SD: 0.42), Group 2's is 2.30 (SD: 0.48), and Group 3's is 2.60 (SD: 0.52). The Test again indicates a significant difference (p=0.007), with Dunn's post hoc test showing significant differences between Group 1 with Groups 2 and 3.



For the Apical region, Group 1 has a mean score of 1.80 (SD: 0.42), Group 2 has 2.60 (SD: 0.52), and Group 3 has 3.50 (SD: 0.53).

The Test shows a highly significant difference (p<0.001), with Dunn's post hoc test indicating significant differences between all

groups. These results suggest that the amount of remaining obturation material significantly varies across different groups and regions, with Group 1 consistently having lower scores compared to Groups 2 and 3.

Comparison of mean Remaining Obturating material scores b/w different regions in each group using Friedman's Test followed by Wilcoxon Signed Rank post hoc Test

Groups	Region	N	Mean	SD	Min	Max	p-value <sup>a</sup>	Sig. Diff	p-value <sup>b</sup>
Group 1	Coronal	10	1.20	0.42	1	2	0.003*	C vs M	0.03*
	Middle	10	1.80	0.42	1	2		C vs A	0.008*
	Apical	10	2.20	0.42	2	3		M vs A	0.04*
Group 2	Coronal	10	1.80	0.63	1	3	0.02*	C vs M	0.04*
	Middle	10	2.30	0.48	2	3		C vs A	0.02*
	Apical	10	2.60	0.52	2	3		M vs A	0.18
Group 3	Coronal	10	1.90	0.74	1	3	0.001*	C vs M	0.04*
	Middle	10	2.60	0.52	2	3		C vs A	0.007*
	Apical	10	3.50	0.53	3	4		M vs A	0.01*

\* - Statistically Significant

Note: a. Friedman's Test & b. Wilcoxon Signed Rank Post hoc Test

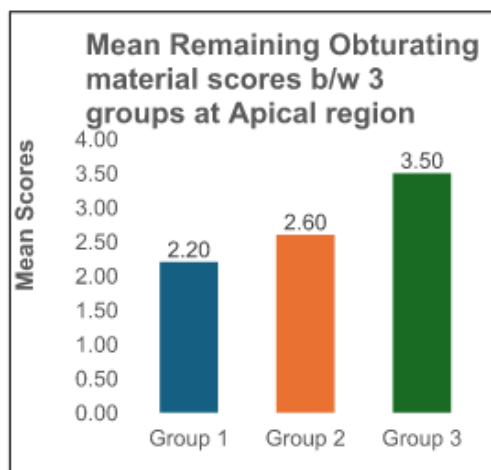
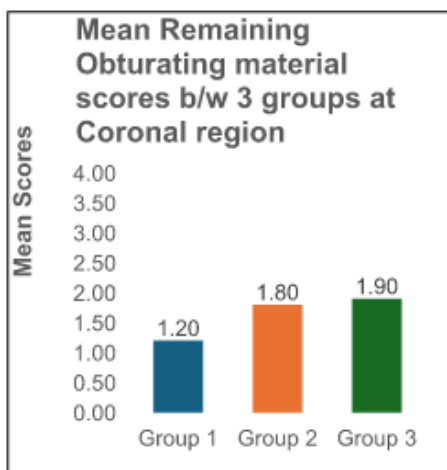
Group 1: In the Coronal region, the mean score is 1.20 (SD: 0.42), in the Middle region, it's 1.80 (SD: 0.42), and in the Apical region, it's 2.20 (SD: 0.42).

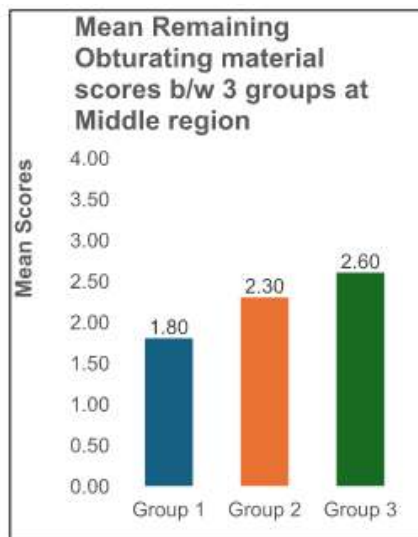
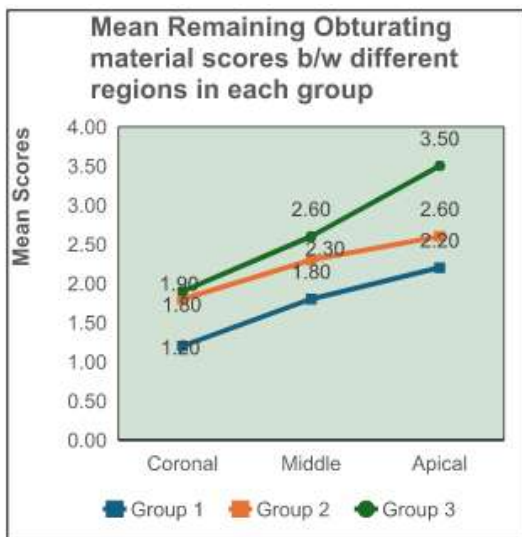
The p-value was 0.003, indicating significant differences. Post hoc analysis reveals significant differences between the Coronal and Middle regions (p=0.03), Coronal and Apical regions (p=0.008), and Middle and Apical regions (p=0.04), suggesting that the score increased significantly from Coronal to Apical Region.

• Group 2: In the Coronal region, the mean score is 1.80 (SD: 0.63), in the Middle region, it's 2.30 (SD: 0.48), and in the Apical region, it's 2.60 (SD: 0.52). The p-value was 0.02, indicating significant differences. Post hoc analysis shows significant

differences between the Coronal and Middle regions (p=0.04) and Coronal and Apical regions (p=0.02), but not between the Middle and Apical regions (p=0.18).

• Group 3: In the Coronal region, the mean score is 1.90 (SD: 0.74), in the Middle region, it's 2.60 (SD: 0.52), and in the Apical region, it's 3.50 (SD: 0.53). The p-value was 0.001, indicating significant differences. Post hoc analysis shows significant differences between all comparisons: Coronal and Middle regions (p=0.04), Coronal and Apical regions (p=0.007), and Middle and Apical regions (p=0.01), suggesting that the score increased significantly from Coronal to Apical Region.





#### IV. DISCUSSION

The primary cause of endodontic failure is the persistence of microbial infection within the root canal system and/or the periradicular tissues. The objective of nonsurgical endodontic retreatment is to remove as much gutta-percha and sealer as possible, thereby exposing residual necrotic tissue and bacteria that may contribute to periapical inflammation and pain. This facilitates subsequent chemomechanical re-instrumentation and disinfection of the canal system with antiseptic or antibacterial solutions, ultimately eliminating bacteria and restoring canal cleanliness. Post-treatment disease may develop due to untreated canals, insufficient cleaning, shaping, obturation, or final restoration of an endodontically treated tooth. It occurs when initial therapy fails to eliminate all bacteria from the canal system, when obturation does not effectively seal residual microorganisms, or when new bacteria gain entry into the disinfected and sealed canal space.<sup>1</sup>

Other factors that can lead to endodontic failure include complex root canal anatomy, positive microbial cultures, remnants of necrotic pulp tissue, fractured instruments, overfilled canals, mechanical perforations, root fractures, coronal leakage, as well as the presence of periradicular lesions and periodontal disease. These shortcomings can lead to pain or other postoperative complications, making retreatment necessary. As a less invasive option, nonsurgical retreatment is generally preferred over surgical intervention. Indeed, endodontic retreatment is now considered the treatment of choice for recurrent periapical infections, largely replacing endodontic surgery.<sup>21</sup>

When primary endodontic therapy fails, retreatment is considered a preferable alternative to extraction. A key objective of nonsurgical endodontic retreatment is the challenging task of thoroughly eliminating root canal filling material. Complete removal of these materials is recommended to enhance the chances of retreatment success. Nonetheless, well-filled curved canals pose unique challenges due to their complex anatomy, potentially compromising cleaning efficiency and increasing the risk of procedural errors. Previous studies have shown that rotary instruments are less time-consuming, safer, better preserve the anatomy of curved canals, and enhance the efficiency of canal preparation during retreatment procedures and less labor-intensive compared to conventional hand files.<sup>22-25</sup>

Ni-Ti files exhibit superelasticity, enabling more centered canal preparations with reduced transportation and fewer canal aberrations. Their greater taper also enhances irrigation effectiveness. When used in a crown-down approach with continuous reaming motion, these files demonstrate superior cutting efficiency. The superior cleaning ability of rotary systems may be attributed to the frictional heat they generate, which softens the gutta-percha and facilitates easier attainment of the working length. Additionally, rotary instruments are specifically designed to remove material in an apicocoronal direction during use.<sup>25</sup>

The clinical success rate of endodontic retreatment has been reported to range between 50% and 90%. This variability is influenced by several factors, including the patient's age, the type of teeth treated, anatomical alterations in the root canal system, the feasibility of removing coronal



restorations to gain access to the pulp chamber, and the techniques employed for eliminating the existing filling material. In this context, the present study utilized Hyflex Remover, Neo Endo, and Mani retreatment file systems to aid in the removal of gutta-percha and sealer from root canals previously obturated with AH Plus sealer.<sup>12</sup>

Complete removal of gutta-percha remains a challenge for all existing retreatment techniques. Residual material can compromise the effectiveness of disinfection procedures, including supplementary instrumentation, the action of irrigating solutions, and the efficacy of interappointment medications. In the present study, none of the retreatment techniques were able to completely eliminate gutta-percha or sealer remnants from the root canal. This outcome is consistent with previous reports by several investigators employing various retreatment instruments, techniques, and solvents, however, significant differences were observed between different file systems with respect to efficiency.<sup>12</sup>

In the present study, the roots were decoronated 15 mm from the apex to standardize the samples and minimize variations in root canal morphology. Stereomicroscopic evaluation was employed as it is considered a simple and reliable method, ensuring a constant distance between the specimen and the device, thereby enabling standardized imaging. The root canals were obturated using the lateral compaction technique prior to removal, as this method has been widely employed in several similar studies.<sup>9,26,27</sup>

In the present study, solvents were not employed because their use in facilitating obturation material removal remains controversial. While solvents can ease file penetration into the filled canal, they may also cause remnants of filling material to adhere firmly to the dentinal walls. Avoiding solvents also helped minimize bias, as the purpose was to evaluate the retreatment efficiency of the files alone, without adjunctive aids. The sealer selected was AH Plus, an epoxy-based resin sealer known for its strong adhesion to dentin, which makes removal more difficult. Compared to calcium hydroxide and zinc oxide–eugenol–based sealers, AH Plus demonstrates lower solubility and shrinkage. It is important to recognize that solvents may leave a hardened layer of gutta-percha adhered to the dentinal walls. Prolonged immersion can cause degradation of resin-based sealers, reducing their sealing ability and increasing the risk of bacterial leakage or reinfection. Moreover, the immersion medium itself may alter the chemical and mechanical

properties of both obturation materials and root canal dentin.<sup>8,28</sup>

The greatest accumulation of debris was observed in the apical third of the root canal compared to the cervical and middle thirds. This can be attributed to the increased anatomical complexity and instrumentation challenges in this region. The presence of curvatures in multiple planes, along with deep grooves and depressions on the dentinal walls of the apical third, likely accounts for these less-instrumented areas, making it difficult for NiTi instruments to effectively contact the entire canal surface.<sup>12</sup>

The ideal apical preparation size for treatment and retreatment remains a topic of considerable debate in endodontics. In the present study, the final preparation size was 30/0.07 for the Hyflex Remover, 30/0.04 for the Mani retreatment file system, and 20/0.07 for the Neo Endo retreatment system. Theoretically, the final preparation size should encompass the previous preparation along the length of the apical canal. Since persistent infection is the primary cause of post-treatment disease, larger apical preparations may be justified to enhance disinfection, although excessive enlargement should be avoided to prevent weakening of the root and increased fracture risk. Improved outcomes in infected teeth with apical periodontitis have been reported following larger apical preparations.<sup>29</sup>

In this study, a new gutta-percha remover, NRT-GPR, was utilized. One of its advantages is reduced risk of fracture at the tip, as stress concentration is minimized by its non-cutting tip design. In the event of fracture, the N3 and N4 instruments tend to break at the neck, making retrieval from the canal easier. A concern regarding the clinical use of the 1S and 2S Mani GPR instruments is their reduced flexibility due to stainless steel composition. The Mani NRT-GPR instruments were developed from the design of GPX stainless steel files. They feature a wide radial land and a neutral cutting angle, which lowers their cutting efficiency and screw-in effect but increases abrasion, explaining the manufacturer's recommendation for use without torque control. The NRT-GPR gutta-percha removal file operates at a higher speed (1000 rpm) and is available in stainless steel for removing gutta-percha from the cervical third, as well as in NiTi versions for use in the apical region of the canal. This instrument has a single cutting edge and one groove. Its cutting edge is made of R-Phase NiTi, which differs from conventional superelastic NiTi files, as it can undergo a certain degree of permanent deformation to better adapt to root canal curvatures.



Furthermore, with a minimum tip size of #30, it cannot adequately penetrate the apical gutta-percha in cases where the apical preparation is smaller than size #30.<sup>2,9,17,29</sup>

The Neoendo files possess a parallelogram-shaped cross-section with a positive rake angle. This design provides only one or two points of contact, thereby reducing binding and minimizing the risk of wedging, which enhances both cutting efficiency and overall performance. The increased volume further facilitates effective debris removal around the instrument. Moreover, the files feature an active cutting tip that allows for easier initial penetration.<sup>30</sup>

In the present study, residual gutta percha left after retreatment with the hyflex remover file was significantly less than neo endo retreatment and mani retreatment file systems. HyFlex Remover is designed with a modified triangular cross-section and is manufactured using C-wire technology. The HyFlex Remover system consists of a single retreatment instrument and demonstrated the least residual material among the systems tested. The superior performance of Hyflex Remover may be attributed to its positive rake angle, active cutting tip, greater taper of 7%, the larger apical size preparation (size 30), larger cross-sectional area and high buckling resistance. The combined influence of its cross-sectional design, active and nonactive tips, and alloy properties contributes to its effectiveness in removing filling materials.<sup>8,31,32</sup>

The present study had certain limitations, including a relatively small sample size and the exclusive use of natural teeth with straight canals, which did not account for the full range of canal morphology variations. Future research incorporating CBCT is recommended to enable more accurate volumetric analysis of the remaining gutta-percha. A limitation of this in vitro study is that its findings need to be validated through larger clinical trials. To obtain more reliable results, additional in vivo studies are required to accurately assess the efficacy of different retreatment systems in removing obturating materials.

## REFERENCES

- [1]. Baig MM, Kalgeri SH, Kansar N, et al. Effectiveness of Different Rotary Files Systems in Removal of Gutta percha During Endodontic Retreatments with or without Solvents: A Comparative Study. *J Contemp Dent Pract* 2023;24(9):688–691.
- [2]. Ali A, Hussain S, Metgud S, Mishra S, Sharma A, Gupta N. Comparative assessment of manual, rotary and reciprocating instruments for removal of root fillings, using stereomicroscope: An in vitro study. *Bangladesh Med Res Counc Bull.* 2019;45:54–61. doi:10.3329/bmrcb.v45i1.41809.
- [3]. Tasdemir T, Er K, Yildirim T, Celik D. Efficacy of three rotary NiTi instruments in removing gutta-percha from root canals. *Int Endod J* 2008;41:191-6.
- [4]. Schirrmeister JF, Meyer KM, Hermanns P, Altenburger MJ, Wrbas KT. Effectiveness of hand and rotary instrumentation for removing a new synthetic polymer-based root canal obturation material (Epiphany) during retreatment. *Int Endod J* 2006;39:150–6.
- [5]. Nasiri K, Wrbas KT. Elimination of *Enterococcus faecalis* in the root canal during the SARS-CoV-2 pandemic. *J Dent Sci.* 2022;17(4):1829-30.
- [6]. Oliveira MA, Venâncio JF, Pereira AG, Raposo LH, Biffi JC. Critical instrumentation area: influence of root canal anatomy on the endodontic preparation. *Br Dent J.* 2014;25:232-36.
- [7]. Alakabani TF, Faus-Llâcer V, Faus-Matoses I, Ruiz-Sánchez C, Zubizarreta-Macho Á, Sauro S, et al. The efficacy of rotary, reciprocating, and combined non surgical endodontic retreatment techniques in removing a carrier-based root canal filling material from straight root canal systems: A micro-computed tomography analysis. *J Clin Med.* 2020;9(6):1989.
- [8]. Singh I, Sinha DJ, Sharma P, Bedi K, Rani P, Vats S. Cone beam computed tomographic evaluation and fracture resistance of endodontically retreated teeth using hyflex remover, Mtwo, and ProTaper retreatment file systems: An in vitro study. *Saudi Endod J* 2024;14:56–62.
- [9]. Joseph M, Ahlawat J, Malhotra A, Murali-Rao H, Sharma A, Talwar S. In vitro evaluation of efficacy of different rotary instrument systems for gutta percha removal during root canal retreatment. *J Clin Exp Dent.* 2016;8(4):e355-60.
- [10]. Imura N, Kato AS, Hata GI, Uemura M, Toda T, Weine F. A comparison of the efficacy of conventional and new retreatment instruments to remove gutta-percha in curved root canals: An ex vivo study. *Int Endod J.* 2009;42:344-50.
- [11]. Ricucci D, Siqueira JF Jr, Bate AL, Pitt Ford TR. Histologic investigation of root



- canal treated teeth with apical periodontitis: a retrospective study from twenty-four patients. *J Endod* 2009;35:493–502.
- [12]. Kumar P, Sood H, Bhat SP, Lohar J, Punia SK, Bhargava R. Comparison of efficiency of manual (H-Files) and two rotary NiTi retreatment systems (Mtwo R files and HyFlex NT files) in removing Gutta percha from root canals obturated with two different sealers by using stereomicroscope – An in vitro study. *Endodontology* 2017;29:95–100.
- [13]. Kumar S, Joseph T, Prasanth K, Lakshminarayanan L. Comparative evaluation of gutta-percha removal using ProTaper retreatment files and Mtwo retreatment files – An in vitro study. *IOSR J Dent Med Sci.* 2020;19(6):49–56. doi:10.9790/0853-2006104956.
- [14]. Tejaswi S, Singh A, Manglekar S, Ambikathanaya UK, Shetty S. Evaluation of dentinal crack propagation, amount of gutta-percha remaining and time required during removal of gutta-percha using two different rotary instruments and hand instruments – An In-vitro study. *Niger J Clin Pract.* 2022;25(4):524-30.
- [15]. Fariniuk LF, Westphalen VP, Silva-Neto UX, Carneiro E, Baratto Filho F, Fidel SR, Fidel RA. Efficacy of five rotary systems versus manual instrumentation during endodontic retreatment. *Braz Dent J.* 2011;22(4):294-8. doi:10.1590/s0103-64402011000400006. PMID: 21861028.
- [16]. Akpınar KE, Altunbas, D, Kus, tarcı A. The efficacy of two rotary NiTi instruments and H-files to remove gutta-percha from root canals. *Medicina Oral, Patologia Oral Y Cirugia Bucal.* 2012;17(3):e506.
- [17]. Alberto Rubino G, de Miranda Candeiro GT, Gonzales Freire L, Faga Iglecias E, de Mello Lemos É, Luiz Caldeira C, Gavini G. Micro-CT Evaluation of Gutta-Percha Removal by Two Retreatment Systems. *Iran Endod J.* 2018;13(2):221-227. doi:10.22037/iej.v13i2.18599.
- [18]. Sagare SV, Chandra P, Kaur T, Ganorkar O, Khade A, Mehta SD. A comparative study of the efficacy of WaveOne and NeoEndo retreatment file system for the removal of gutta-percha from the root canal. *J Pharm Bioallied Sci.* 2021;13(Suppl 2):S1682.
- [19]. Surakanti JR, Venkata RC, Vemisetty HK, Dandolu RK, Jaya NK, Thota S. Comparative evaluation of apically extruded debris during root canal preparation using ProTaper™, Hyflex™ and Waveone™ rotary systems. *J Conserv Dent.* 2014;17:129-32.
- [20]. Sankar A, Solete P, Jeevanandan G, et al. Comparative Evaluation of Solite RS3 and HyFlex Remover Retreatment Files in Conserving Remaining Dentin Thickness During Endodontic Retreatment Using Cone Beam Computed Tomography: An In Vitro Analysis. *Cureus* 2024;16(4):e57805. doi:10.7759/cureus.57805.
- [21]. Kanaparthi A, Kanaparthi R. The comparative efficacy of different files in the removal of different sealers in simulated root canal retreatment—an in-vitro study. *J Clin Diagn Res.* 2016;10(5):ZC130–ZC133. doi:10.7860/JCDR/2016/17731.7845.
- [22]. Azarpazhooh A, Sgro A, Cardoso E, Elbarbary M, Lighvan NL, Badewy R, et al. A scoping review of 4 decades of outcomes in nonsurgical root canal treatment, nonsurgical retreatment, and apexification studies—Part 2: Outcome measures. *J Endod.* 2022;48(1):29-39.
- [23]. Joshi C, Hajoori M, Patel A, Somani M, Thumar S, Khunt A, Patel D, Desai N. Comparative evaluation of different retreatment files for gutta-percha removal from curved root canals accessed with novel ultra-conservative opening: an in-vitro study. *J Clin Diagn Res.* 2023 Mar;17(3):ZC37–ZC42. doi:10.7860/JCDR/2023/59885.17622.
- [24]. Aung NM, Myint KK. Diagnostic accuracy of CBCT for detection of second canal of permanent teeth: A systematic review and meta-analysis. *Int J Dent.* 2021;2021:1107471.
- [25]. Das S, De Ida A, Das S, Nair V, Saha N, Chattopadhyay S. Comparative evaluation of three different rotary instrumentation systems for removal of gutta-percha from root canal during endodontic retreatment: An in vitro study. *J Conserv Dent.* 2019;22(2):151–6.
- [26]. Karunakar P, Ranga Reddy MS, Karteek BS, Reddy CLC, Swetha C, Racha K, Waheed S. Evaluation of the efficacy of Neo-endo, Hyflex re-treatment file systems and H-files for removing gutta-percha from root canal treated tooth by



- using stereomicroscope—an in vitro study. *J Pharm Bioallied Sci.* 2024 Apr;16(Suppl 2):S1695–S1699. doi: 10.4103/jpbs.jpbs\_970\_23.
- [27]. Ankita A, Khetarpal A, Ahlawat M. Comparison of efficacy of three Ni-Ti retreatment instruments in removal of gutta-percha from root canal: An in vitro study. *J Conserv Dent.* 2022;25(4):345–349.
- [28]. Singh KB, Akhtar M, Nagar R, et al. Comparative Analysis of the Efficacy of Various Retreatment File Systems in the Removal of Gutta-Percha in Retreatment Cases and Time Taken During the Procedure: An In Vitro Cone Beam CT Study. *Cureus.* 2024;16(3): e55551. doi:10.7759/cureus.55551.
- [29]. Silveira SB, Alves FRF, Marceliano-Alves MF, Sousa JCN, Vieira VTL, Siqueira JF Jr, Lopes HPL, Provenzano JC. Removal of root canal fillings in curved canals using either Mani GPR or HyFlex NT followed by passive ultrasonic irrigation. *J Endod.* 2018;44(2):299–303.e1. doi:10.1016/j.joen.2017.09.012.
- [30]. Baranwal HC, Mittal N, Garg R, Yadav J, Rani P. Comparative evaluation of retreatability of bioceramic sealer (BioRoot RCS) and epoxy resin (AH Plus) sealer with two different retreatment files: An in-vitro study. *J Conserv Dent.* 2021;24(1):88-93.
- [31]. Staffoli S, Grande NM, Plotino G, Özyürek T, Gündoğar M, Fortunato L, et al. Influence of environmental temperature, heat treatment and design on the cyclic fatigue resistance of three generations of a single file nickel titanium rotary instrument. *Odontology.* 2019;107:301–7.
- [32]. Kim Y, Chang SW, Oh S. Buckling resistance, torque, and force generation during retreatment with D RaCe, HyFlex remover, and Mtwo retreatment files. *Restor Dent Endod.* 2023;48:e10.