



# Management of Ellis class II Fracture by fragment tooth reattachment: A case report

Dr. Rutuja Mane, Dr. Divya Naik, Dr. Sumanthini M V, Dr. Anuradha Patil,  
Dr. Amrut Bambawale

Department of Conservative Dentistry and Endodontics, MGM Dental College, Navi Mumbai, India

Date of Submission: 15-05-2024

Date of Acceptance: 25-05-2024

## ABSTRACT

Dental injuries to the anterior teeth are common. Injured anterior teeth require urgent treatment, and if left untreated, it may damage the entire tooth or even cause psychological damage to the patient. There are many different treatments for this condition; one of which is the reduction of the fracture itself. Reattaching broken fragments allows for immediate healing, restoration of function, aesthetic beauty, and is a faster, easier method. Due to its simplicity, natural beauty and preservation of tooth structure, tooth reduction should be the first choice and is a viable alternative to traditional procedures. Patient cooperation and understanding of treatment limitations are important for effective evaluation. This document describes the treatment of fractures in the anterior maxillary teeth by reimplantation of the same fracture. Reattachment of broken tooth fragments provides an advanced treatment method that instantly restores tooth function and beauty using a very effective and cost-effective method.

**Keywords:** Fragment reattachment, complicated crown fracture, trauma, resin composite

## I. INTRODUCTION

Injuries to the front teeth (mostly the upper incisors) are common in adult and paediatric dentistry. Having a conservative approach has many advantages.<sup>1</sup> These include preserving the colour and aesthetic appearance of natural teeth and ensuring that the rear incisal edge wears at the same rate as neighbouring teeth.<sup>2</sup> One option for the treatment of coronal tooth fractures is to replace the broken tooth when the tooth is broken and there is no or little damage due to disease.<sup>3</sup>

Recent developments in restorative materials, placement techniques, structural design

and bonding techniques facilitate the restoration of upper incisor teeth due to fracture. Tennery was the first to introduce the use of acid etching techniques to reattach cracks. Subsequently, Starkey and Simonsen have reported similar findings.<sup>4,5</sup>

It improves performance, beauty, aesthetics in a short time, thus preserving the original lines and alignment of the texture. Patient cooperation and understanding of treatment limitations are important for effective evaluation.<sup>6</sup> This article presents case report on the use of composite materials to repair an Ellis Class II fractured tooth.

## II. CASE REPORT

A 24-year-old patient reported to the conservative dentistry and endodontics department with a complaint of right maxillary central tooth fracture. The patient recovered the broken tooth from the site of injury and kept it in the environment (water). The injury occurred as a result of a fall approximately 3 hours ago. Intraoral and x-ray examination revealed an oblique coronal fracture involving enamel and dentin, extending to the palatal region.

The patient and his legal guardian were offered a variety of treatment options, including reattachment of broken teeth. After careful consideration of the pros, cons, prognosis, and cost of each treatment, the patient elected to reattach the broken tooth. It is important to note that the choice of restoration is offered only after it has been confirmed that the fracture is in good condition and shows excellent marginal adaptation of the fractured tooth. Clinical examination and x-ray revealed fracture of the right maxillary central incisor (**Fig. 1 & 2**).

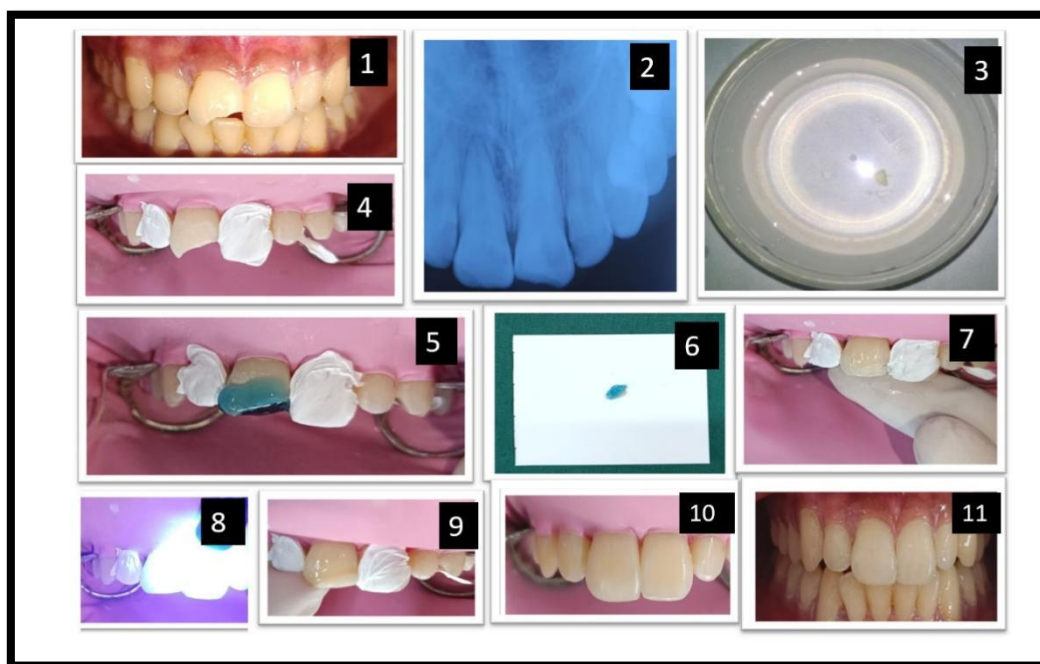
The fractured part was stored in saline for sometime. (Fig 3) After rubber dam placement, the proper fragment adaptation was checked and there was a placement of teflon tape on adjacent teeth.

Retaining grooves were prepared on the labial and palatal sides of 11 broken teeth and endless slopes were created along the entire broken edge. (Fig. 4) Then adjustment was done and fit was checked. The teeth were etched with 37% phosphoric acid (Prime Dental) for 30 seconds, and the fragments were etched for 15 seconds (Fig. 5 & 6).

The fragments were then rinsed and blot-dried with paper points, followed by the application of a bonding agent (Tetric N-Bond Universal) on both the tooth surfaces and the fragments.

The bonding agent was not cured, and the inner fragment and tooth surface was applied with dual core composite. The fragment was then held with an applicator tip supported by bee wax and approximated on the tooth and cured for 40 seconds to the facial and palatal surfaces of the tooth, while the fragment was kept in position under pressure. (Fig 7) The fracture line was masked with flowable composite applied over the bevel all around the tooth and light cured. (Fig 8 and 9)

After curing, diamond finishing bur was used to remove extra composite material. Finishing and polishing was done with polishing discs (Shofu). (Fig 10 & 11) Follow-up examinations were carried out at 3 and 6 months interval. The tooth remained normal in aesthetics and function.



**Fig 1** -Pre-operative clinical image with 11. **Fig 2** - Pre-operative IOPA. **Fig 3** - Fractured segment stored in normal saline. **Fig 4** - Grooves and tooth preparation done with 11 followed by placement of teflon tape on adjacent teeth. **Fig 5 and 6** - Etching with 37% phosphoric acid done on tooth and fractured fragment. **Fig 7**- Fragment segment was carefully seated on the remaining tooth. **Fig 8** - Curing of resin composite using light curing device. **Fig 9** - Placement of flowable composite over the bevel all around the tooth. **Fig 10** - Final composite restoration done with 11. **Fig 11** - Post-operative clinical view after fractured segment reattachment.

### III. DISCUSSION

The dentist plays an important role in the treatment of the injury, so he must consider the possibility of saving the injured tooth. Significant advances in bonding and composite materials have made the restoration of broken teeth not temporary restorations, but restorations with a positive effect. However, this method can only be used with the availability of intact tooth fragment.<sup>5</sup>

A treatment plan can be developed after the disease, endodontic, coronal and occlusal conditions are evaluated. With the development of dental technology, it is now possible to achieve good results by repairing broken teeth as long as biological materials, materials and procedures are followed correctly and quality controlled. Other factors that may influence the choice of procedure include the need for endodontic treatment,



continuity of bone, quality of fracture fit, and fracture pattern.<sup>6</sup>

In this case, the location of the broken bone, its morphology (uneasy crown fracture) and the presence of a balanced occlusion may be of interest in terms of treatment. The orientation of the fracture line is an important part of rehabilitation and directly affects the outcome of the tooth.<sup>7</sup> The use of natural tooth substance clearly eliminated problems of differential wear of restorative material, unmatched shades and difficulty of contour and texture reproduction associated with other restorative techniques.

Limitations are mainly due to detachment of remaining dental fragment; the fragment does not recover its original colour or bonding of the remaining fragment at the incorrect position. None of these adverse conditions occurred in the patient.<sup>7</sup>

The prognosis also depends on the fitness, contour, and surface finishing of subgingival restoration. The success rates of reattached fragments have been seen up to 90% for a follow-up period of up to 24 months.<sup>8</sup>

The reattachment of a coronal fragment seems to be a practical alternative to placement of conventional composite resin restorations in the management of fractured anterior teeth, as this method is simple, conservative, and provides satisfactory fragment retention and aesthetics. It also ensures complete restitution of the tooth's integrity.<sup>9,10</sup>

#### IV. CONCLUSION

For restoring esthetics and function reattachment is a successful technique. In patients with broken teeth, immediate esthetic restoration fragment reattachment fulfills the treatment goal. Tooth fragment reattachment offers an ultraconservative, safe, fast and esthetically pleasing result. Reattachment of the dental fragment as a restorative procedure has become possible with the improvement of adhesive techniques and restorative materials.

#### REFERENCES

- [1]. Shetty PP, Metgud S, Jain A, Dhillon G, Astekar M. A conservative single visit reattachment of fractured crown fragment. *Clin Pract.* 2012 Jul 11;2(3):e70.
- [2]. Basavanna R, Kapur R, Sharma N. A single visit, reattachment of fractured crown fragment. *Contemp Clin Dent.* 2010;1(3):168.
- [3]. Tennery N.T.: The fractured tooth reunited using the acid etch bonding technique. *Tex Dent J* 1988; 96: 16 – 17.
- [4]. Starkey P.E.: Reattachment of a fractured fragment to a tooth. *J Ind Dent Assoc* 1979; 58: 37 - 38. Simonsen R.J.: Restoration of a fractured central incisor using original teeth. *J Am Dent Assoc* 1982; 105: 646 – 648
- [5]. Simonsen R.J.: Traumatic fracture restorations: An alternative use of the acid etch technique. *Quint Int.* 1979; 10(2): 15 – 22.
- [6]. Chu FC, Yim TM, Wei SH. Clinical considerations for reattachment of tooth fragments. *Quintessence Int* 2000;31:385-91.
- [7]. Reis A, Loguercio AD, Kraul A, Matson E. Reattachment of fractured teeth: A review of literature regarding techniques and materials. *Oper Dent* 2004;29:226-33
- [8]. Yilmaz Y, Zehir C, Eyuboglu O, Belduz N. Evaluation of success in the reattachment of coronal fractures. *Dent Traumatol* 2008;24:151-8.
- [9]. Andreasen FM, Norén JG, Andreasen JO. Long-term survival of fragment bonding in the treatment of fractured crowns: a multicenter clinical study. *Pediatr Dentist Quintessence Intern.* 1995;26:669–81.
- [10]. Garcia FCP, Poubel DLN, Almeida JCF, Toledo IP, Poi WR, Guerra ENS, Rezende LVML. Tooth fragment reattachment techniques-A systematic review. *Dent Traumatol.* 2018 Jun;34(3):135-143.