



Management of Open Apex using Biodentine: Two Case Reports

Rahul Pai¹, Mohd Zeeshan Ahmad², K. Harish S. Shetty³, Nithin Suvarna⁴

^{1,2} Postgraduate student, Department of Conservative Dentistry and Endodontics, Yenepoya Dental College, Yenepoya (Deemed to be university), Mangaluru, Karnataka, India

^{3,4} Professor, Department of Conservative Dentistry and Endodontics, Yenepoya Dental College, Yenepoya (Deemed to be university), Mangaluru, Karnataka, India

Submitted: 10-09-2024

Accepted: 20-09-2024

ABSTRACT

Pulpal necrosis in an immature permanent tooth often leads to an open apex, which may further lead to the formation of periapical pathology. Such cases are often perceived as difficult to manage with conventional techniques and materials. These cases are usually treated by the apexification procedure. This article presents two such case reports wherein the open apex was treated by a single-step apexification procedure, using Biodentine™ as the material for the formation of an apical plug. Both cases showed favourable clinical and radiographic outcomes demonstrating the effectiveness of this material.

KEYWORDS: Apexification, apical plug, biodentine, immature permanent teeth, open apex

I. INTRODUCTION

Traumatic injuries or caries in immature permanent teeth often lead to necrosis of the pulp which results in the arrest of development of the root; thus causing the canals to have wide and open apices¹.

These canals are usually thin and fragile and are susceptible to root fracture. Adequate instrumentation and irrigation of these canals is often a challenge and it is usually difficult to achieve an adequate apical stop². This leads to an increased risk of overinstrumentation, extrusion of irrigating solutions, as well as overextension of obturating materials.

In such cases, the apexification procedure can be considered a suitable treatment option. The goal of apexification is to either induce closure of the apical foramen with calcified tissue or to create an artificial barrier at the apex^{1,3}. Historically, calcium hydroxide has been the material of choice for inducing a calcific barrier at the apex; however, it has several drawbacks, such as the need for multiple treatment visits and the long period required for closure of the apex, as well as the

susceptibility of the tooth to fracture due to long term exposure to calcium hydroxide^{1,4}.

The introduction of bioactive materials like Mineral trioxide aggregate (MTA) and other calcium silicate-based cements have allowed clinicians to perform apexification procedures in a single visit⁵. Biodentine™ (Septodont, St Maur des Fosses, France), a recently introduced calcium silicate-based cement, possesses excellent handling characteristics, which are due to its high viscosity and short initial setting time of 12 minutes⁶.

II. CASE REPORT 1

A 20-year old female patient reported to the Department of Conservative Dentistry and Endodontics, with the chief complaint of a discoloured upper tooth in the front region. The patient revealed a history of traumatic dental injury during her childhood 10 years ago. The patient was asymptomatic. There was no relevant medical history or any known drug allergies. On intraoral examination, there was yellowish discolouration of tooth 11. The tooth was not tender to percussion or on palpation. There was no associated pathologic mobility. There were no relevant soft tissue findings. Permanent restoration was noted on the palatal aspect of tooth 11, suggestive of previous dental treatment. However, the patient was not aware of the history of dental treatment. Pulp sensibility was checked with the EPT and cold test, both of which gave no response with tooth 11. The radiographic examination of the tooth revealed radiopaque material in the chamber space suggestive of previously attempted endodontic therapy, and a wide canal with an open apex and periapical radiolucency was noted (Figure 1).

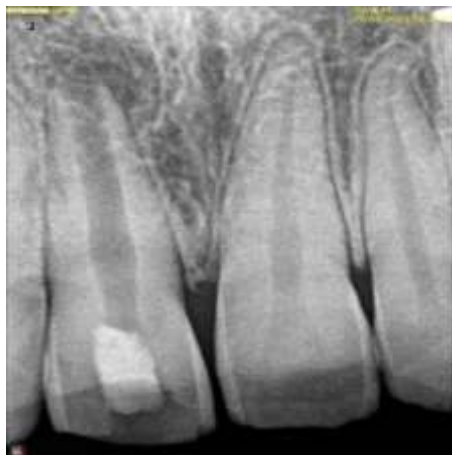

Fig 1: Pre-op Radiograph

The clinical diagnosis of tooth 11 was previously initiated therapy with asymptomatic apical periodontitis. A treatment plan of endodontic therapy with apexification followed by in-office bleaching with respect to tooth 11 was explained to the patient and informed consent was obtained for the same.

The tooth was anesthetized and an endodontic access cavity was established under rubber dam isolation. The working length was determined and later confirmed using a periapical radiograph (Figure 2).

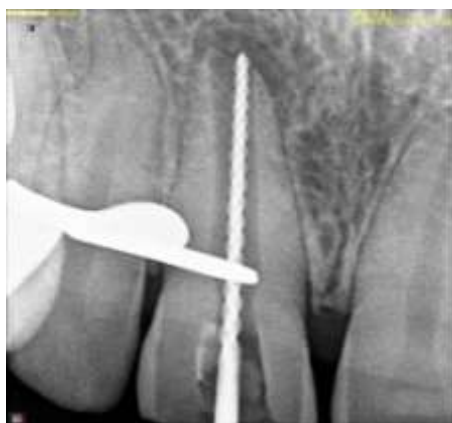

Fig 2: Working length determination

Shaping of the canal was done upto a 70K file used in circumferential filing strokes using light pressure against the already thin walls. The canal was thoroughly irrigated with 2.5% NaOCl (20 mL) using a single-side vented needle placed 3 mm short of the apex which was then activated using a sonic activator. The canal was then rinsed with normal saline solution. Sterile paper points were used to dry the canal after which a freshly prepared mix of Calcium hydroxide and 2% Chlorhexidine was used as intracanal dressing for 1

week. The patient was recalled a week later, the tooth was isolated under rubber dam and the calcium hydroxide dressing was removed by hand instrumentation, and irrigation was done with 2.5% NaOCl and 17% EDTA solution for 1 minute followed by a final rinse with 2.5 % NaOCl for 30s. The root canal was then dried with sterile paper points.

The mixture of Biodentine™(Septodont, St Maur des Fosses, France) was then prepared following the manufacturer's instructions and the material was placed inside the canal in increments. The increments were pushed towards the apex using a hand plugger until a plug of adequate thickness (5 mm) was formed (Figure 3).

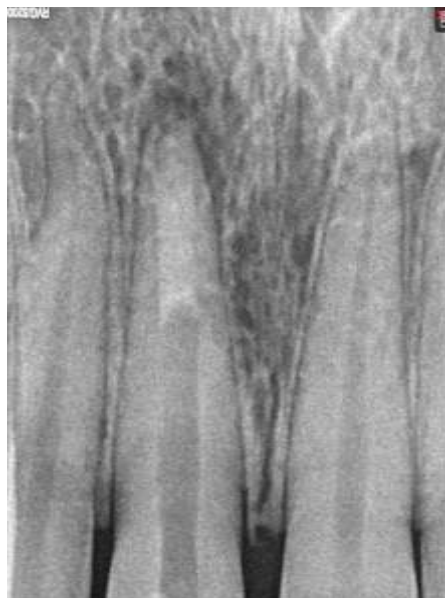


Fig 3: Apical Plug (5 mm)

Thermoplasticized obturation technique (Calamus Dual, DentsplyMaillefer, Switzerland) with AH Plus sealer (Dentsply, DE Trey GmbH, Konstanz, Germany) was used to fill the canal space up till the level of CEJ. Resin-modified glass ionomer cement (Ionoseal, VOCO GmbH, Cuxhaven, Germany) was used to seal the canal orifice (Figure 4).

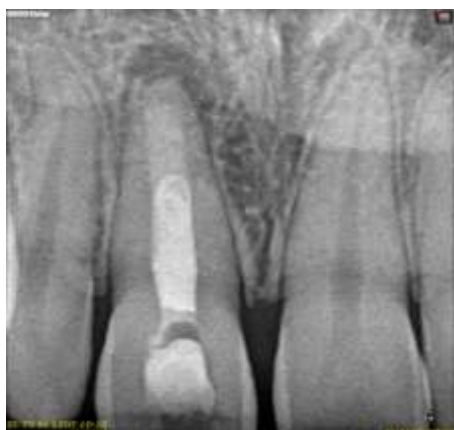

Fig 4: Thermoplasticized Obturation

The tooth was immediately restored with a Temporary filling material. In subsequent visits, the tooth was subjected to in-office bleaching procedure. After the bleaching treatment, the tooth was restored with composite resin (Tetric N-Ceram, Ivoclar Vivadent). One year post-operative radiograph revealed resolution of the periapical lesion (Figure 5).

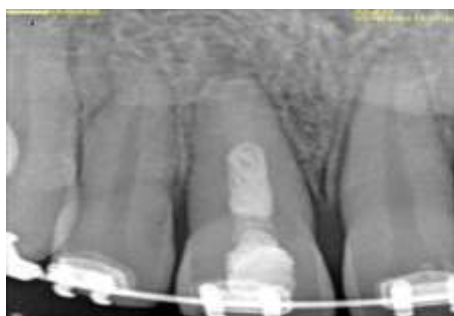

Fig 5: 1 year Follow up

The patient was asymptomatic and there were no clinical signs and symptoms of pathosis at the follow-up appointment.

III. CASE REPORT 2

A 25-year old female patient reported to the Department of Conservative Dentistry and Endodontics with a chief complaint of pain in the upper front tooth since 2 months. The patient revealed a history of traumatic dental injury during her childhood. The patient complained of associated pain that gets relieved on its own. There was no relevant medical history or any known drug allergies. The patient gave a history of previous dental treatment concerning the tooth of complaint. On intraoral examination, there was an open cavity noted on the palatal aspect of tooth 21 suggestive of previously attempted dental treatment. The tooth was tender to percussion. There was no associated

tenderness on palpation. There was no associated pathologic mobility. There were no relevant soft tissue findings. Pulp sensibility was checked with the EPT and cold test, both of which showed negative responses. The radiographic examination of the tooth revealed radiolucency in the chamber space suggestive of previously attempted endodontic therapy, and a calcified canal within a shortened root with blunt apex (Figure 6).

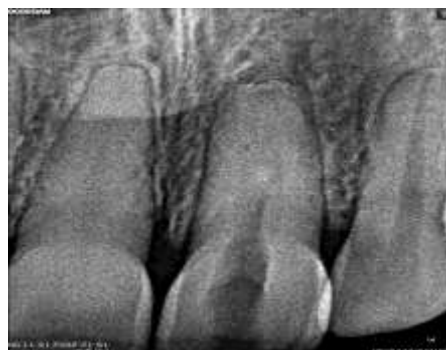

Fig 6: Pre-op Radiograph

There was no widening of the PDL space. The clinical diagnosis of tooth 21 was previously initiated therapy with symptomatic apical periodontitis. A treatment plan of endodontic therapy with respect to tooth 21 was explained to the patient and informed consent was obtained for the same.

The tooth was anesthetized and an endodontic access cavity was established under rubber dam isolation. The calcified canal was negotiated using C+ files (Dentsply, DE Trey GmbH, Konstanz, Germany), ultrasonic tips and U-files (Dr. Talal's Endo Kit, Woodpecker Medical Instrument Co., LTD) with the help of 17% EDTA solution. The working length was determined and later confirmed using a periapical radiograph (Figure 7).

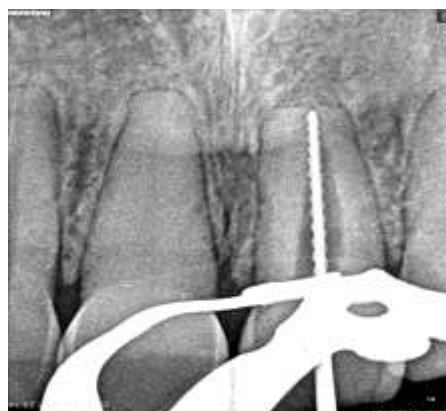


Fig 7: Working length determination



Shaping of the canal was done upto a master apical file size of 80K using step-back technique. However, it was noted post-instrumentation that, the canal terminus was over-prepared. Hence, the decision to place an apical plug of Biodentine™(Septodont, St Maur des Fosses, France) was made and informed to the patient. The canal was thoroughly irrigated with 2.5% NaOCl (20 mL) using a single-side vented needle placed 3 mm short of the apex which was then activated using a sonic activator. The canal was then rinsed with normal saline solution. Sterile paper points were used to dry the canal after which a freshly prepared mix of Calcium hydroxide and 2% Chlorhexidine was used as intracanal dressing for 1 week. The patient was recalled a week later, the tooth was isolated under rubber dam and the calcium hydroxide dressing was removed by hand instrumentation, and irrigation was done with 2.5% NaOCl and 17% EDTA solution for 1 minute followed by a final rinse with 2.5 % NaOCl for 30s. The root canal was then dried with sterile paper points.

The mixture of Biodentine™(Septodont, St Maur des Fosses, France) was then prepared following the manufacturer's instructions and the material was placed inside the canal in increments. The increments were pushed towards the apex using a hand plugger. A plug of adequate thickness (4 mm) was formed, which was confirmed radiographically (Figure 8).

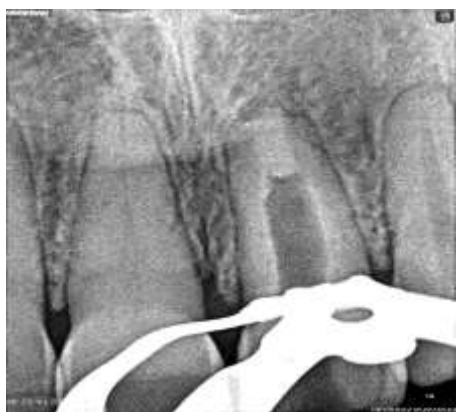

Fig 8: Apical Plug (4 mm)

Thermoplasticized obturation technique (Calamus Dual, DentsplyMaillefer, Switzerland) with AH Plus sealer (Dentsply, DE Trey GmbH, Konstanz, Germany) was used to fill the canal space up till the level of CEJ (Figure 9).

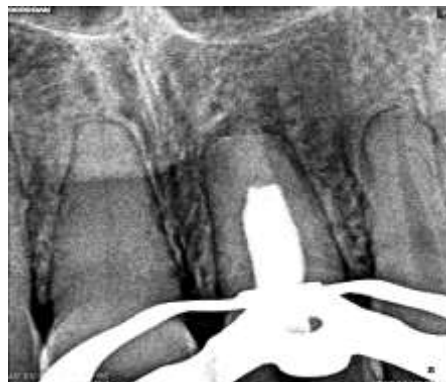


Fig 9: Thermoplasticized Obturation

Resin-modified glass ionomer cement (Ionoseal, VOCO GmbH, Cuxhaven, Germany) was used to seal the canal orifice. The tooth was immediately restored with composite resin (Tetric N-Ceram, Ivoclar Vivadent).

IV. DISCUSSION

Apexification is defined as a method of inducing a calcified apical barrier or continued apical development of an incompletely formed root in teeth with necrotic pulp⁷. The apical plug is crucial for sealing and preventing bacterial leakage³. In recent years, MTA has been the material of choice for apexification procedures. However, due to certain drawbacks such as long setting time, discoloration potential, poor handling characteristics and low washout resistance, this material is gradually being replaced by newer calcium silicate-based cements².

Biodentine™ (Septodont, St Maur des Fosses, France) has a modified powder composition with the addition of setting accelerators and softeners which have drastically improved the physical properties of this material and shortened the setting time, making it much more user-friendly compared to MTA⁸. The powder is composed of tricalcium silicate, dicalcium silicate, calcium carbonate, calcium oxide and zirconium oxide. The liquid consists of a water-soluble polymer and calcium chloride, which accelerates the setting reaction. This material is indicated for permanent dentin replacement, direct and indirect pulp capping, pulpotomy, repair of furcation and root perforations, retrograde root-end filling, and apexification procedures⁵.

Due to surface crystal growth within dentinal tubules, there is better sealing ability between Biodentine and dentin⁵. Studies have also shown the presence of a "mineral infiltration zone" at the material-dentin interface⁹. When used as an apical plug, the release of calcium ions and the presence of Si-OH groups induce apical sealing



through the deposition of apatite onto the surface of the root¹⁰.

V. CONCLUSION

The improved properties of the material and the favorable clinical and radiographic outcomes noted in both case reports demonstrate that Biodentine™ may be considered an efficient alternative to the conventional apexification materials.

REFERENCES

- [1]. Tolibah YA, Kouchaji C, Lazkani T, Ahmad IA, Baghdadi ZD. Comparison of MTA versus Biodentine in apexification procedure for nonvital immature first permanent molars: a randomized clinical trial. *Children*. 2022 Mar 14;9(3):410.
- [2]. Aeran H, Sharma M, Tuli A. Biodentine: Material of choice for apexification. *International Journal of Oral Health Dentistry*. 2021;7(1):54-6.
- [3]. Vidal K, Martin G, Lozano O, Salas M, Trigueros J, Aguilar G. Apical closure in apexification: a review and case report of apexification treatment of an immature permanent tooth with biodentine. *Journal of endodontics*. 2016 May 1;42(5):730-4.
- [4]. Andreasen JO, Farik B, Munksgaard EC. Long-term calcium hydroxide as a root canal dressing may increase risk of root fracture. *Dental traumatology*. 2002 Jun;18(3):134-7.
- [5]. Niranjana B, Shashikiran ND, Dubey A, Singla S, Gupta N. Biodentine—a new novel bio-inductive material for treatment of traumatically injured tooth (single visit apexification). *Journal of clinical and diagnostic research: JCDR*. 2016 Sep;10(9):ZJ03.
- [6]. Musale PK, Kothare S. Non-surgical endodontic management of immature permanent mandibular first molar: a 3 year follow-up. *European Archives of Paediatric Dentistry*. 2018 Oct;19:373-7.
- [7]. Sheehy EC, Roberts GJ. Use of calcium hydroxide for apical barrier formation and healing in non-vital immature permanent teeth: a review. *British dental journal*. 1997 Oct;183(7):241-6.
- [8]. Bajwa NK, Jingerwar MM, Pathak A. Single visit apexification procedure of a traumatically injured tooth with a novel bioinductive material (Biodentine). *International journal of clinical pediatric dentistry*. 2015 Jan;8(1):58.
- [9]. Koubi G, Colon P, Franquin JC, Hartmann A, Richard G, Faure MO, Lambert G. Clinical evaluation of the performance and safety of a new dentine substitute, Biodentine, in the restoration of posterior teeth—a prospective study. *Clinical oral investigations*. 2013 Jan;17:243-9.
- [10]. Trubiani O, D'arcangelo C, Di Iorio D, Di Nardo Di Maio F, Caputi S. Dental pulp stem cells bioadhesivity: evaluation on mineral-trioxide-aggregate. *International journal of immunopathology and pharmacology*. 2007 Feb;20(1_suppl):81-6.