



## Mandibular Nerve Neurectomy in Trigeminal Neuralgia: Breaking the Pain Cycle through Evidence and Experience

Dr. Pinnamaneni Kavya<sup>1\*</sup>, Dr. Chunduri Nagendra Srinivas<sup>2</sup>, Dr. MD Yousuf Qureshi<sup>3</sup>, Dr. Aishwarya Venkat<sup>4</sup>

<sup>1</sup>Post-graduate student, Department of Oral and Maxillofacial Surgery, Malla Reddy Institute of Dental Sciences, Malla Reddy Vishwavidyapeeth (Deemed to be), Suraram, Hyderabad, Telangana, India.

<sup>2</sup>Professor & Head of the Department, Department of Oral and Maxillofacial Surgery, Malla Reddy Institute of Dental Sciences, Malla Reddy Vishwavidyapeeth (Deemed to be), Suraram, Hyderabad, Telangana, India.

<sup>3</sup>Professor, Department of Oral and Maxillofacial Surgery, Malla Reddy Institute of Dental Sciences, Malla Reddy Vishwavidyapeeth (Deemed to be), Suraram, Hyderabad, Telangana, India.

<sup>4</sup>Post-graduate student, Department of Oral and Maxillofacial Surgery, Malla Reddy Institute of Dental Sciences, Malla Reddy Vishwavidyapeeth (Deemed to be), Suraram, Hyderabad, Telangana, India.

Date of Submission: 10-09-2025

Date of Acceptance: 20-09-2025

### ABSTRACT

Trigeminal Neuralgia (TN) is a debilitating condition characterized by recurrent, electric shock-like pain localized to one side of the face. It predominantly affects individuals over the age of 40, with a higher incidence observed in females. First-line management typically involves pharmacological agents that modulate nerve excitability. However, a significant number of patients eventually experience inadequate relief or intolerable side effects, necessitating alternative interventions. In refractory cases, surgical modalities such as peripheral neurectomy can offer substantial pain control. Despite its effectiveness, the potential for nerve regeneration may contribute to symptom recurrence over time. This article presents four clinical cases alongside an in-depth exploration of current evidence surrounding the management of TN.

**Keywords:** Trigeminal neuralgia, Tic doloureux, Mandibular division, Peripheral neurectomy, Trigger point

### I. INTRODUCTION

Trigeminal neuralgia (TN) is a debilitating condition marked by unilateral, brief, and intense pain in one or more branches of the trigeminal nerve. First described by John Fothergill in 1773, it is occasionally called Fothergill's disease or Prosopalgia Dolorosa. According to the International Classification of Headache Disorders, 2nd edition (ICHD-II), TN is characterized by brief, electric shock-like pain triggered by minimal stimuli such as washing, shaving, smoking, talking, or brushing teeth, and may occur spontaneously. TN primarily affects the 2nd and 3rd divisions of the trigeminal nerve, especially on the right side,

and can significantly impact the individual's quality of life (QoL). The initial treatment usually involves medical management, with carbamazepine as the preferred medication. However, long-term use may lead to reduced effectiveness and side effects, sometimes necessitating surgical intervention for those who do not respond to or cannot tolerate medications. Surgical options are generally categorized into Gasserian Ganglion-level and Peripheral Procedures. Peripheral neurectomy (PN) is a minimally invasive technique that involves removing the postganglionic segment of the affected nerve branch. While PN is low-cost and involves minimal risks, pain recurrence remains a common issue. This article presents four cases of TN involving the mandibular division successfully treated with PN and reviews the relevant literature on TN and its management strategies.

### CASE REPORTS

#### CASE 1

A 51-year-old male presented to the Department of Oral and Maxillofacial Surgery with a one-year history of unilateral, sharp, radiating pain in the left lower back tooth region. This pain was exacerbated by activities like eating and smiling and significantly impaired his daily activities. Examinations revealed generalized attrition of the teeth and trigger zones at the left corner of the mouth and lower lip. A diagnostic block of the mental nerve using 2% lignocaine with 1:80,000 adrenaline provided complete symptom relief for 120 minutes, confirming the involvement of the mental nerve and indicating trigeminal neuralgia. The patient was scheduled for a peripheral neurectomy under local anesthesia. An intraoral vestibular incision was made, and a full-

thickness mucoperiosteal flap was raised to expose the mental foramen. The mental nerve was then avulsed, and the foramen was obliterated using a hydroxyapatite bone graft. Hemostasis was

achieved, and the incision was closed with 3-0 silk sutures. Postoperatively, the patient had an uneventful recovery, remained symptom-free for one year, and was not on any medication. (Fig. 1)

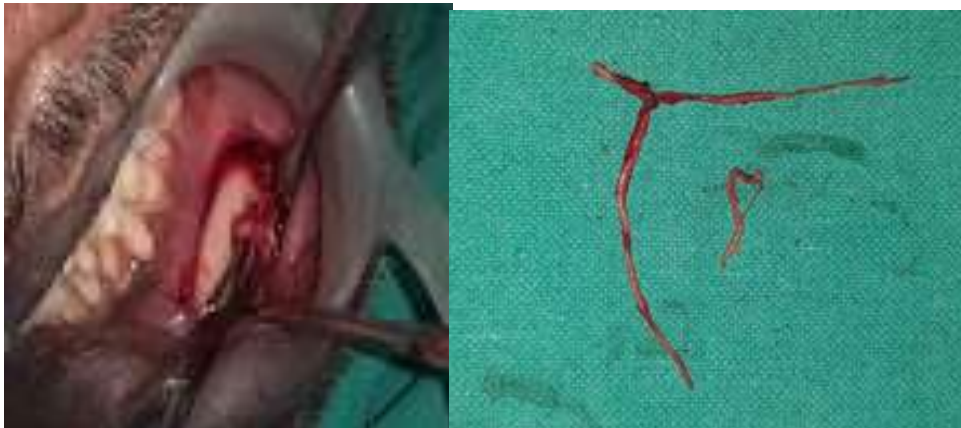

Fig. 1. Skeletonization of the mental nerve (left). Avulsed mental nerve (right)

#### CASE 2

A 56-year-old female visited the Department of Oral and Maxillofacial Surgery with sharp, radiating pain in her lower left jaw for the past 5 to 6 months. A year ago, she was symptom-free but developed similar pain that led to a peripheral neurectomy of the left mental nerve in 2022, providing relief for one year. The pain returned with sudden onset, and continuous intensity, and was aggravated by eating, gargling, and brushing, despite taking Pregabalin 50 mg for 6 months. She had previously undergone tooth extractions of teeth 24, 31 and 37. Upon examination, trigger zones were noted in the left angle region. Nerve blocks using 2% lignocaine with 1:80,000 adrenaline confirmed the involvement of the inferior alveolar nerve, supporting a diagnosis of trigeminal neuralgia. In

November 2023, she received a 1.2 ml alcohol injection into the inferior alveolar nerve, which relieved her pain for 2 months. A second injection followed, providing relief for 1.5 months. By May 2024, she reported recurrence and was diagnosed with trigeminal neuralgia involving the mental and long buccal nerves, leading to a scheduled peripheral neurectomy. After confirming normal hematological parameters, the procedure was performed under local anesthesia. The mental nerve neurectomy followed her previous surgical approach, and the long buccal nerve was accessed through a vestibular incision. The nerve was carefully dissected and avulsed, and the wound was closed with non-resorbable sutures. The patient had an uneventful recovery and has remained symptom-free for 7 months without any medications. (Fig. 2)

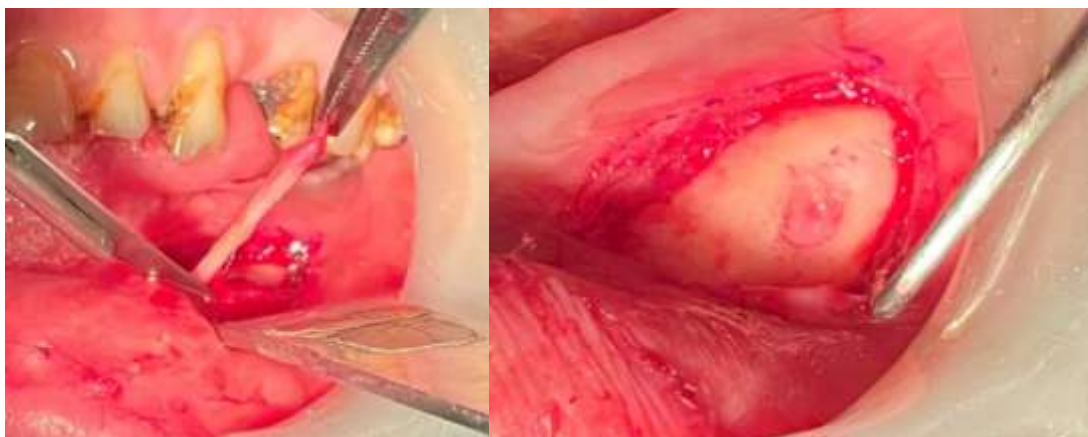

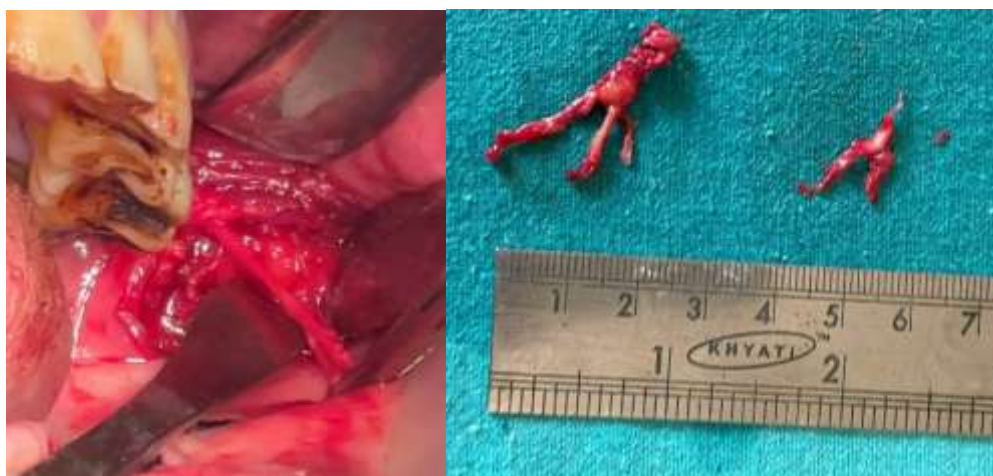


Fig. 2. Skeletonization of the mental nerve (upper left). Obliteration of the mental foramen with bone wax (upper right). Long buccal nerve exposed (lower left). Avulsed nerves (lower right)

Cases 3 and 4 involved trigeminal neuralgia in a 56-year-old female (Case 3) affecting the mental nerve, and a 51-year-old female (Case 4) affecting the inferior alveolar nerve. Case 3 (Fig. 3) was treated similarly to Case 1, while Case 4 (Fig. 4) underwent an inferior alveolar nerve

neurectomy through Dr. Ginwalla's Inverted Y-incision. Both patients received antibiotics and analgesics postoperatively and recovered without complications. Case 3 has been symptom-free for 9 years, and Case 4 for 7 years, with no need for further medication.

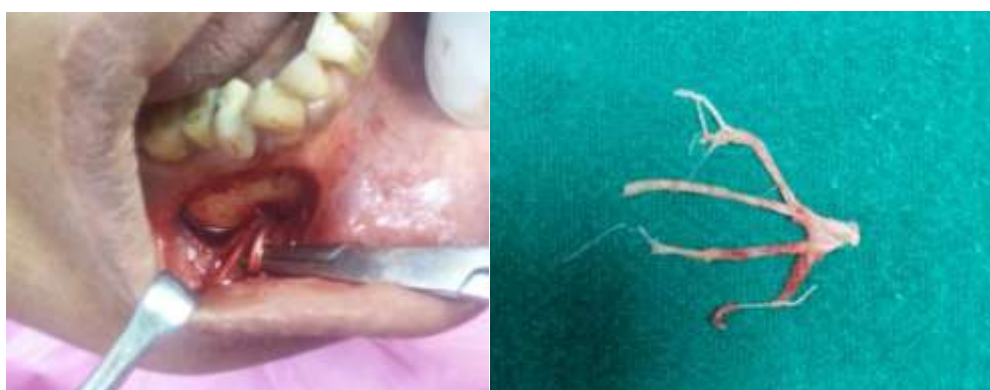

Fig.3. Skeletonization of the mental nerve (left). Avulsed mental nerve (right)

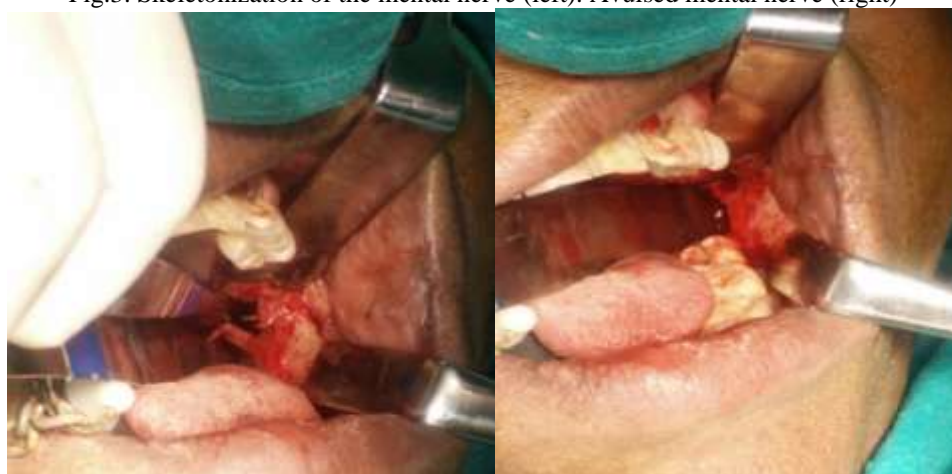


Fig. 4. Inferior alveolar nerve skeletonization (left). Inferior alveolar nerve neurectomy (right)



## II. DISCUSSION

Trigeminal neuralgia (TN) is a neurological disorder marked by sudden, severe facial pain. It is the most commonly diagnosed form of neuralgia, with an incidence of 4 cases per 100,000 people and an average onset age of around 50 years. The condition is more prevalent in females, with gender ratios between 1:2 and 2:3. TN usually affects one side of the face: the maxillary branch in 35% of cases, the mandibular branch in 30%, both branches in 20%, the ophthalmic and maxillary in 10%, the ophthalmic branch alone in 4%, and all branches in just 1%. Diagnosis relies on the patient's clinical history of pain episodes and established diagnostic criteria. Sweet's criteria to diagnose trigeminal neuralgia are:

1. The pain is paroxysmal.
2. The pain may be provoked by a light touch to the face (trigger zone).
3. The pain is confined to trigeminal distribution.
4. The pain is unilateral.
5. The clinical sensory examination is normal.

The differential diagnosis of TN includes conditions such as cluster headaches, dental pain, giant cell arteritis, glossopharyngeal neuralgia, intracranial tumors, migraine, multiple sclerosis, otitis media, paroxysmal hemicrania, post-herpetic neuralgia, sinusitis, short-lasting unilateral neuralgiform headache with conjunctival injection and tearing (SUNCT), and temporomandibular joint disorders.<sup>4</sup>

Treatment options for trigeminal neuralgia (TN) include both pharmacologic and surgical approaches. Medications such as carbamazepine, oxcarbazepine, lamotrigine, gabapentin, and topiramate, either alone or in combination, are commonly used to manage symptoms. If medical treatment is ineffective or not well tolerated, surgical options may be considered based on the patient's specific condition.<sup>10,11</sup>

- Non-invasive technique:
  - Peripheral neurectomy
  - Alcohol injections
  - Cryotherapy
  - Selective radio frequency thermocoagulation
- Invasive technique<sup>11</sup>:
  - Open microvascular decompression,
  - Percutaneous:
    - Radiofrequency rhizotomy
    - Retrogasserian glycerol rhizotomy
    - Balloon compression of the trigeminal nerve
    - Stereostatic radiosurgery –gamma knife.

Peripheral neurectomy, first practiced in the 18th century, stands as one of the oldest surgical methods for managing trigeminal neuralgia (TN). This procedure involves the excision of the terminal branches of the trigeminal nerve, providing precise, effective, and long-lasting pain relief. It can be performed on various branches, including the supraorbital, supratrochlear, infratrochlear, lacrimal, infraorbital, inferior alveolar, lingual, and mental nerves. Notably, this minimally invasive surgery is straightforward and safe, making it suitable for outpatient procedures under local anesthesia. As a result, peripheral neurectomy is an appealing option for patients seeking relief from the debilitating pain associated with TN.<sup>12</sup>

Peripheral neurectomy offers significant advantages over peripheral nerve blocks using agents like alcohol or phenol, which can lead to complications such as tissue toxicity, inflammation, fibrosis, and burning alcohol neuritis. Research indicates that patients who have experienced both alcohol neurolysis and peripheral neurectomy found the latter to be less painful and more effective in providing long-lasting pain relief. For example, Ngeow and Nair<sup>13</sup> Reported a case where botulinum toxin provided partial relief, but definitive pain control was achieved through peripheral neurectomy. Khanna and Galinde<sup>14</sup> Documented pain relief lasting 24 months for infraorbital nerve neurectomies and 26 months for mental nerve neurectomies. Similarly, Quinn<sup>15</sup> Reported on 112 neurectomies performed on 63 patients, noting pain relief durations ranging from 24 to 32 months, with follow-up periods extending up to 9 years. Grantham<sup>16</sup> Observed an average pain relief duration of 33.2 months in a series of 55 patients, with follow-ups ranging from 6 months to 8 years.

Despite its effectiveness, one of the primary limitations of peripheral neurectomy is the regenerative potential of the trigeminal nerve. Over time, nerve fibers can regenerate, which may lead to a return of pain. To address this issue, the obturation of the nerve's foramen has been performed using biocompatible materials such as fat, titanium screws, gold foils, or silicone, with varying degrees of success. In the study conducted by Lamichhane NS et al., two patients experienced a recurrence of neuralgic pain within 48 hours after the neurectomy; however, this pain resolved spontaneously shortly thereafter.<sup>6</sup> Shah et al. observed similar outcomes.<sup>5</sup> Notably, in 1886, Geo R. Fowler noted that in cases with a peripheral origin, residual pain after neurectomy often subsided after a few days.<sup>17</sup>



Peripheral neurectomy is a reliable and straightforward option for managing trigeminal neuralgia (TN), especially for elderly or debilitated patients, due to its simplicity and good tolerance. However, the potential adverse effects can vary depending on the nerve branch involved. These may include paresthesia, facial sensory loss, weakness or paralysis of the masseter muscle, and, in rare cases, loss of the corneal reflex. Although these risks are infrequent, they should be carefully considered alongside the benefits when deciding on this procedure for TN management.

### III. CONCLUSION

There is no single best surgical treatment for trigeminal neuralgia, but each case presents a unique opportunity for evaluation and hope. Peripheral neurectomy stands out as a viable and effective option—a minimally invasive procedure that gently removes the terminal branches of the trigeminal nerve. As one of the oldest and most patient-friendly surgical interventions, it can be performed under local anesthesia, offering a path forward for the elderly, those facing serious systemic conditions, or patients with limited life expectancy. Its cost-effectiveness, minimal complications, and affordability make it a practical choice, empowering patients who seek relief without the burden of more invasive procedures.

### CONFLICT OF INTEREST

No potential conflict of interest relevant to this article was reported.

### FUNDING

No funding to declare

### ACKNOWLEDGEMENTS

The legal permission and informed consent were obtained from the patients.

All authors have made a substantive contribution to this study and/or manuscript, and all have reviewed the final paper prior to its submission.

### REFERENCES

- [1]. Zuba LP. Treatments For Painful Post-Traumatic Trigeminal Neuropathy: A Literature Review and Clinical Case Report. *J Dent Oral Sci* [Internet]. 2023 Sep 30 [cited 2024 Jun 5]; Available from: <https://maplespub.com/article/treatments-for-painful-post-traumatic-trigeminal-neuropathy-a-literature-review-and-clinical-case-report>
- [2]. Scrivani SJ, Mehta N, Mathews ES, Maciewicz R. Clinical criteria for trigeminal neuralgia. *Oral Surg Oral Med Oral Pathol Oral Radiol Endod*. 2004 May;97(5):544; author reply 544-545.
- [3]. Nilesh K. Pain Control and Quality of Life after Peripheral Neurectomy in Patients with Refractory Trigeminal Neuralgia. *World J Dent*. 2021 Jul 15;12(4):278–84.
- [4]. Abd-Elseyed A, editor. *Trigeminal Nerve Pain: A Guide to Clinical Management* [Internet]. Cham: Springer International Publishing; 2021 [cited 2024 Jun 4]. Available from: <http://link.springer.com/10.1007/978-3-030-60687-9>
- [5]. (PDF) The Role of Peripheral Neurectomies in the Treatment of Trigeminal Neuralgia in Modern Practice [Internet]. ResearchGate. [cited 2024 Dec 25]. Available from: [https://www.researchgate.net/publication/279782961\\_The\\_Role\\_of\\_Peripheral\\_Neurectomies\\_in\\_the\\_Treatment\\_of\\_Trigeminal\\_Neuralgia\\_in\\_Modern\\_Practice](https://www.researchgate.net/publication/279782961_The_Role_of_Peripheral_Neurectomies_in_the_Treatment_of_Trigeminal_Neuralgia_in_Modern_Practice)
- [6]. Lamichhane N, Du X, Li S, Poudel D. Effectiveness of peripheral neurectomy in refractory cases of trigeminal neuralgia. *J Orofac Sci*. 2016;8(2):86.
- [7]. Murali R, Rovit RL. Are peripheral neurectomies of value in the treatment of trigeminal neuralgia? An analysis of new cases and cases involving previous radiofrequency gasserian thermocoagulation. *J Neurosurg*. 1996 Sep;85(3):435–7.
- [8]. Cerovic R, Juretic M, Gobic MB. Neurectomy of the trigeminal nerve branches: Clinical evaluation of an “obsolete” treatment. *J Cranio-Maxillofac Surg*. 2009 Oct;37(7):388–91.
- [9]. Reddy GV, Reddy MRH, Krishna IV, Sultana R. Peripheral Neurectomy of Infraorbital Nerve - A Treatment Option for Trigeminal Neuralgia: A Case Report. 2015;1(9).
- [10]. Xu R, Xie ME, Jackson CM. Trigeminal Neuralgia: Current Approaches and Emerging Interventions. *J Pain Res*. 2021 Nov; Volume 14:3437–63.
- [11]. Bick SKB, Eskandar EN. Surgical Treatment of Trigeminal Neuralgia. *Neurosurg Clin N Am*. 2017 Jul;28(3):429–38.
- [12]. Ali FM, Prasant MC, Aher VA, Safiya T, Pai D, Kar S. Peripheral neurectomies: A treatment option for trigeminal neuralgia in rural practice. *J Neurosci Rural Pract*. 2012 May;03(02):152–7.



- [13]. Ngeow WC, Nair R. Injection of botulinum toxin type A (BOTOX) into trigger zone of trigeminal neuralgia as a means to control pain. *Oral Surg Oral Med Oral Pathol Oral Radiol Endod.* 2010 Mar;109(3):e47-50.
- [14]. Khanna JN, Galinde JS. Trigeminal neuralgia. Report of 140 cases. *Int J Oral Surg.* 1985 Aug;14(4):325–32.
- [15]. Quinn JH. Repetitive peripheral neurectomies for neuralgia of second and third divisions of trigeminal nerve. *J Oral Surg Am Dent Assoc* 1965. 1965 Nov;23(7):600–8.
- [16]. Grantham EG, Segerberg LH. An evaluation of palliative surgical procedures in trigeminal neuralgia. *J Neurosurg.* 1952 Jul;9(4):390–4.
- [17]. Fowler GR. I. The Operative Treatment of Facial Neuralgia. *Ann Surg.* 1886 Apr;3(4):269–320.