

## Molluscum Contagiosum in a Immunocompetent Patient; A case series of four cases.

Dr.Shailendra Yadav  
Corresponding Author  
Assistant Professor  
Dept of Pathology  
GMC Nagpur

Dr.Mukesh Waghmare  
Assistant Professor  
Dept of Pathology  
GMC Nagpur

Dr.Sneha Sangrame  
senior resident  
GMC Nagpur

Date of Submission: 20-12-2023

Date of Acceptance: 30-12-2023

**ABSTRACT:**Molluscum contagiosum [MC] is a common skin and mucosal disease caused by MC pox virus family. Lesions manifests both in immunocompromised and immunocompetent individuals as variable, discrete, umbilicated papules on face, trunk, thigh, near genital organs and rarely oral mucosa.

**Keywords:**Mollouscum contagiosum,virus ,skin .

### I.INTRODUCTION

Molluscum contagiosum[MC] is a common childhood viral infection of squamous epithelium of the skin appearing as pearly-white, dome-shaped umbilicated papules. Acquisition of the virus follows contact with infected persons or contaminated objects and sources, such as swimming pools. It is observed with a higher frequency in tropical climates. Molluscumcontagiosum virus cannot be propagated in vitro. Therefore these cases are mostly diagnosed clinically and the diagnosis is confirmed by the demonstration of characteristic molluscum bodies from the lesions.

#### Case History

A 5yr old female child was brought to the dermatology OPD with multiple, domeshaped, pearly-white umbilicated lesions on the posterior aspect of left thigh (Figure 1). A clinical diagnosis of Molluscum contagiosum was made. Under strict aseptic conditions, the lesions were biopsied; the sample thus obtained was sent for histopathology

examination in formalin to confirm the clinical diagnosis.

#### Case history

A 40 years female attended dermatology opd with multiple well defined umbilicated vesicles to bullous lesion present over left forearm, chest and perineum. A clinical diagnosis of Molluscum contagiosum was made.Under strict aseptic conditions, the lesions were biopsied; the sample thus obtained was sent for histopathology examination in formalin to confirm the clinical diagnosis.

Differential diagnosis 1]Herpes simplex infection 2] Cryptococcosis 3]Penicillois 4] Histoplasmosis.

#### Case history

A 17 years male came to ophthalmology outpatient department with history of multiple umbilicated nodules over face and around eyes. excision biopsy was taken from lower lid margin.

Differential diagnosis

1]molluscum contagiosum

#### Case history

A 1.5 year male came to dermatology out patient department with history of single dusky red lesion of left thigh since five months. Radiofrequency ablation biopsy was taken.

Differential diagnosis 1]mollouscum contagiosum

Figure 1 Figure 2

DOI: 10.35629/5252-0506435438 | Impact Factor value 6.18 | ISO 9001: 2008 Certified Journal Page 435

**International Journal Dental and Medical Sciences Research**

Volume 5, Issue 6, Nov-Dec 2023 pp

435-438 [www.ijdmsrjournal.com](http://www.ijdmsrjournal.com) ISSN: 2582-6018

Figure 1



Figure 2

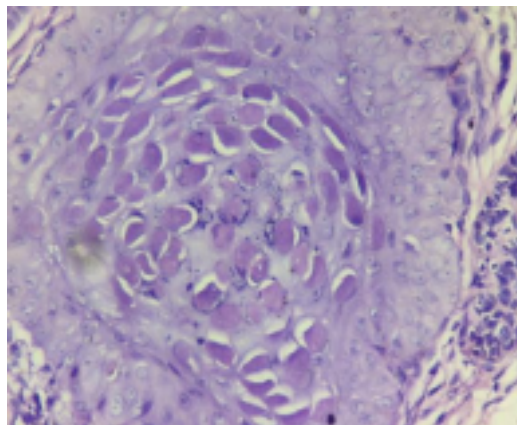
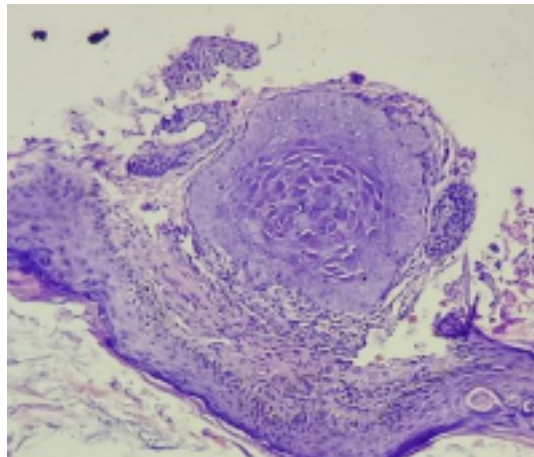


Figure 3



Histologically, molluscum contagiosum is characterized by molluscum bodies (also known as Henderson-Patterson bodies) in the epidermis, above the stratum basale, which consist of cells with abundant large granular eosinophilic cytoplasmic inclusion bodies (accumulated virions) and a small nucleus that has been pushed peripherally.

## II. RESULTS AND DISCUSSION

Molluscum bodies are the largest known inclusion bodies measuring about 30-35 microns in diameter. They are virus transformed keratinocytes composed of large numbers of virus particles embedded in a protein matrix. MC is a superficial viral infection. It was first described by Pateman in the year 1957. It is caused by MC virus type I in children and MC virus type II in immune compromised individuals. It is caused by MC virus which is a DNA virus, usually seen in immune compromised states like

HIV. The clinical presentation of lesions in children is frequently seen on skin, neck, arms, armpits and hands and mucous membrane of oral cavity. But in case of sexually active adults with AIDS, lesions are seen on genital, abdominal and inner parts of thighs. The lesions are usually self-limiting in immune competent patients, whereas extensive and cause disfigurement when associated with HIV. MC is mostly transmitted by direct skin to skin contact and infects epidermal keratinocytes where the virus replication occurs in the cytoplasm. Lesions are most commonly noted as semi transparent papules with central concavity or punctuation at the center with dense elastic consistency at site of inoculation of virus. The lesions may or may not be associated with itching.<sup>4</sup> These lesions can be confirmed by biopsy. Histopathological examination shows inverted proliferation of epithelium in lobulated pattern which is cup shaped. The cytoplasm of spinous cells show large eosinophilic and later basophilic viral inclusion bodies called molluscum

DOI: 10.35629/5252-0506435438 | Impact Factor value 6.18 | ISO 9001: 2008 Certified Journal Page 436

**International Journal Dental and Medical Sciences Research**

Volume 5, Issue 6, Nov-Dec 2023 pp 435-438 [www.ijdmsrjournal.com](http://www.ijdmsrjournal.com) ISSN: 2582-6018

bodies or Henderson Paterson bodies. Each developed nodule empties pox virus particle into the central crater which can be visualized by electron microscopy. Similar histopathological features were seen in the present case and were also reported by Jang et al<sup>6</sup> and Nandini et al<sup>3</sup>. Usually small MC lesions are self-limiting and heal by themselves. MC can be treated by various treatment modalities. Smaller lesions are self-limiting and heal by themselves.<sup>3</sup> Persistent lesions need intervention.

Various treatment modalities include topical applications, cryosurgery, lasers and curettage. Most commonly used topical applications which are effective are imiquimod, cantharidin, potassium hydroxide, 5% podophyllotoxin.<sup>7</sup> Curettage is found to be most effective treatment with fewer side effects under anesthesia. Mutairi N conducted a comparative study with cryosurgery and imiquimod and concluded that imiquimod is painless and recommended in children, whereas cryotherapy is rapidly effective and less expensive than imiquimod in treating large solitary or few lesions. Jang H S et

al treated the erupted papules of MC with topical imiquinod cream and oral immunomodulating agents like cemitidine which showed resolution of lesions.<sup>6</sup>Kalasannavar SB et al have adapted a novel ayurvedic approach in treating MC using Apamarga Kshara as local application and BilvadiAgada prescribed orally for ten days showed healing lesions without scarring.<sup>5</sup> Pulse dye laser also has shown successful rate of more than 95% in treating individual lesions.

### III.CONCLUSION

Molluscum contagiosum is a viral disease generally seen in immunocompromised states like HIV but can also manifest in immunocompetent individuals as found in the present case. Being MC rare in immunocompetent patients, it is important

to consider MC as one of the differential diagnosis clinically in a non HIV patient. Histologically shows classic Henderson-Paterson bodies. Smaller lesions are self-limiting and larger lesions need topical application.

Molluscum contagiosum virus cannot be propagated in vitro. The cases are mostly diagnosed

clinically and the diagnosis is confirmed by the demonstration of characteristic molluscum bodies from the lesions.

### REFERENCES

- [1]. Bateman F .Molluscumcontagiosum:Shelley WB, Crissey JT, editors .Classics in Dermatology. Springfield, IL: Charles C Thomas;1953.p20
- [2]. Fenner F. Poxviruses. In: Fields BN,KnipeDM,editors. Virology 2nd ed New York:Raven press;1990
- [3]. Moss B. Poxviridae and their replication In:Fields BN,,knipe DM, MelnickJL,editors. Virology.2 edNewYork: Raven press;1990
- [4]. Dhar S, Jain S,Verma G, Tanwar RK. Disseminated and atypical molluscumcontagiosum in an AIDS patient. Indian j Dermatol,Venerol and Leprol 1996;62:331-2
- [5]. Janniger CK,Schwartz RA, Molluscumcontagiosum in children 1953 52; 194-6
- [6]. Parr RP, Burnett JW, Garon CF. Ultrastructural characterization of the MollouscumContagiosum virus genome,virology1977,81;247-56.
- [7]. Kumar, et al: Robbins and cotran Pathologic Basis of Disease; 7/e 2004 pg1266-67