



Nonsurgical retreatment and intracanal separated instrument bypass in a mandibular molar with periapical lesion – A Case Report

Dr.Sambath K, Dr.Sreeja J,Dr. Mali G Nair, Dr. Jincy Alex

^{1,4}Junior Resident, Dept of Conservative Dentistry and Endodontics, Government DentalCollege,Trivandrum

²Additional Professor, Dept of Conservative Dentistry and Endodontics, Government DentalCollege,Trivandrum

³Professor&HOD, Dept of Conservative Dentistry and Endodontics, Government DentalCollege,Trivandrum.

Date of Submission: 25-06-2024

Date of Acceptance: 05-07-2024

ABSTRACT: The separation of endodontic instruments during a root canal procedure is a complication that can hinder the cleaning and shaping procedures, which can affect the outcome of endodontic treatment. One effective technique for managing broken instruments is the instrument bypass technique that not only offers the advantage of preserving the remaining dentin in the root canal but also avoid the need for surgical intervention. This paper presents conservative retreatment of a root canal treated mandibular molar with instrument separation in middle third of the mesial root and a periapical lesion.

Keywords: Broken instrument, instrument bypass, periapical lesion, retreatment

I. INTRODUCTION

Instrument separation in the root canal is one of the most common procedural mistakes encountered during endodontic therapy by a clinician. Instrument separation happens during cleaning and shaping, not just with students and general practitioners, but even with professional and seasoned clinicians, despite taking all precautions.¹ The term “broken instruments” applies not only to separated files, but can also be applied to Gates-Glidden burs, carbon- steel or stainless steel (SS) endodontic files (K-files, Hedström files, barbed broaches, reamers), nickel-titanium (NiTi) rotary instruments, lateral spreaders, peeso reamers, spiral fillers and irrigation needles.^{2,3} The prognosis of endodontic therapy depends on the amount of contamination of the canal at the moment of separation of the instrument and the presence of apical pathology. A broken file within the root canal may also block the access to the apical third of the root.⁴

Endodontic hand and rotary files are the most commonly used instruments for the removal of infected and affected dentin and for smoothing and shaping of canal walls. Stainless steel instruments are more susceptible to breakage due to excessive torque, while NiTi rotary files typically fracture due to torsional stress and cyclic fatigue.⁵

Nickel-titanium (NiTi) instruments have become extremely popular in endodontic practice nowadays. NiTi instruments can revert to their original shape after use, making them more flexible than stainless steel instruments. With the advent of super elastic NiTi instruments, the efficiency of endodontic cleaning and shaping has greatly improved, especially in the curved canals.^{6,7}

However, the advent of the NiTi alloy has not resulted in a lower incidence of endodontic instrument fracture and NiTi files can be broken in the root canals without any significant evidence of damage on their surfaces. The fracture rate of NiTi rotary instruments has been reported as being between 1.3% and 10%. The fracture of rotary instruments can affect the entire prognosis of root canal therapy.⁸

Clinical studies indicate that the frequency of overall endodontic instrument separation (either rotary or hand files) ranges from 1.83% to 8.2%. The frequency of rotary instrument separation ranges between 0.13% and 10% and includes several kinds and types of instruments. The manual instrument separation frequency is 0.25% to 6%. When treating molars, the frequency of instrument separation is highest (77% - 89%). Compared to upper molars, lower molars have a higher chance of separation during treatment (50% to 55%).⁹ In a study conducted by Spili et al.², the healing rates of teeth with periapical lesions were 87% for cases with a fractured instrument and 93% for matched controls after at least one year.

Both conservative and surgical methods can be used to treat instrument separation. For nonsurgical methods, the following choices might be available:

- Instrumentation and obturation of coronal portion beyond the fragment;
- Bypassing of the fragment;
- Fragment removal⁴

There is no exact definition for failure of endodontic treatment among endodontists. Most clinicians would agree that an endodontically treated tooth can be considered successfully treated if there is no pain or other clinical symptoms, or more precisely,



if the tooth's function is preserved.¹⁰. However, an inflammatory lesion that was previously absent from the periapical tissue, its persistence, or even its enlargement following endodontic therapy, is a definite sign of failed endodontic treatment¹⁰. Radiographic evaluation of endodontic treatment is the main method of monitoring outcome of the treatment.^{11,12}

Prior to retreatment, it is important to consider all options in relation to the time, cost and prognosis of therapy, and to decide between nonsurgical (orthograde) retreatment, surgical retreatment, or extraction.¹³ Endodontic retreatment includes removal of material from the root canal space, detection of all deficiencies, and repair of pathological or iatrogenic defects, followed by shaping and cleaning, and finally obturation.¹⁴The clinical decision should be based on thorough knowledge of success rate of each; treatment options, constraints of the root canal accommodating the fragment, the stage of root canal instrumentation at which the instrument separated, the expertise of the clinician, armamentaria available, possible associated complications, the strategic importance of the tooth involved, and the presence/or absence of periapical pathosis¹¹.

The present case report, illustrates the nonsurgical retreatment and intracanal separated instrument bypass in left mandibular first molar with periapical lesion, with a one year follow up for the same.

II. CASE PRESENTATION

A 24-year-old female patient, reported to the Conservative Dentistry and Endodontics Department, complaining of pain and swelling in relation to left mandibular first molar teeth for one month. The patient's dental history revealed a previous endodontic treatment and crown restoration of the same tooth 10 years back.

The patient was apparently healthy. Clinical examination revealed that the patient's oral hygiene was fair. Despite typical periodontal probing and normal tooth mobility, swelling on the buccal side of involved tooth (#36 according to FDI numbering system) and severe pain on percussion test were seen.

Initial radiographic evaluation of the tooth showed inadequate root canal treatment with large periapical radiolucency and massive bone resorption around the mesial and distal roots. (Fig.A) In addition, further careful radiographic observation revealed two broken instruments in mesiobuccal and mesiolingual root canals, close to the middle third of root canal. (Fig.B) Periapical radiographic evaluation of the adjacent second molar tooth (#37 according to FDI numbering system) revealed adequate root canal filling

with no periapical lesion. Both the molars were coronally restored with metal crowns

The tooth was diagnosed with symptomatic AP. Possible treatment options were thoroughly explained to the patient comprising:

- (i) simple extraction of tooth #36 with/without replacement with dental implants,
- (ii) endodontic retreatment of tooth #36 and apicoectomy of the roots
- (iii) endodontic retreatment of tooth #36 with instrument bypass
- (iv) endodontic retreatment with instrument retrieval.

The patient wished to keep her tooth with minimum possible complications; consequently, the endodontic retreatment of tooth #36 with instrument bypass was thoroughly explained to the patient, and her informed consent was formally obtained.

In the first appointment, after administration of local anaesthesia, removal of metal crown was done. After tooth isolation with rubber dam, necessary coronal restoration of tooth #36 was removed, an appropriate access cavity was prepared, and canal orifices were cautiously investigated, probed, and located. Using xylene, previous root canal obturation materials were completely removed, and canals were carefully irrigated with 3% sodium hypochlorite (NaOCl; Hyposol, PrevestDenPro limited). Then, the root canal system was chemo mechanically cleaned, shaped, and copiously irrigated with normal saline.

The instrument bypass approach was applied as follows: Following the glide path of the mesiobuccal and mesiolingual canals of 36, the fragments were loosened with the #6 K-file. The file was then re-inserted slowly and carefully to negotiate the root canal beyond the broken fragment of instrument in order to better debride and disinfect the canal. The file was slowly inserted in between the dentinal wall and fractured instrument thus, avoiding placing the K-file directly on top of the broken file. Once the catch was felt, the hand file was not removed at that point. Performing a gentle in and out movement using a #6 K-file, followed by a #8 K-file while ensuring copious canal irrigation resulted in bypass of the blocked canal. On the radiograph, the patency of the canal was determined at 21mm from the coronal reference point (working length) using a #10 K-file. Hand filing up to #20 K-file was done to reduce the risk of further instrument separation. Working lengths of remaining distal canal was taken and chemo-mechanical preparation of the two mesial canals were enlarged to 25.04% and distal canal was enlarged to 25.06%. In the mesiobuccal and mesio lingual canals, a place-pull, rotate, and withdrawal movement rather than a filling

motion was done along with copious irrigation. Normal Saline, 3% NaOCl, and 17% EDTA were used for irrigation and disinfection of the canals.

Due to large periapical changes, creamy mixture of calcium hydroxide was introduced into the canal till the working length using a counter clockwise motion with # 20 k file and a temporary restoration was placed. Follow up was done after 4 weeks and the patient was asymptomatic. Calcium hydroxide dressing was flushed out with copious irrigation with normal saline. The root canal did not dry after using absorbent paper points, a slight exudate was present. Double antibiotic paste (Ciprofloxacin and Metronidazole ,1:1 ratio in glycerine) was then applied to control the persistent infection. Using Cavit, temporary restoration was placed. Further follow-up radiographs were taken at 2 months (Fig C, D), and the tooth was obturated. The root canals were then filled using a gutta-percha cone and resin-based sealer using a single cone obturation technique (Fig E). And at 4 months follow-up visit (Fig F), it was seen that there was complete resolution of the radiolucency w.r.t 36, following which a post endodontic crown was given. The patient reported no complaint in regards to swelling and pain on percussion thereafter.

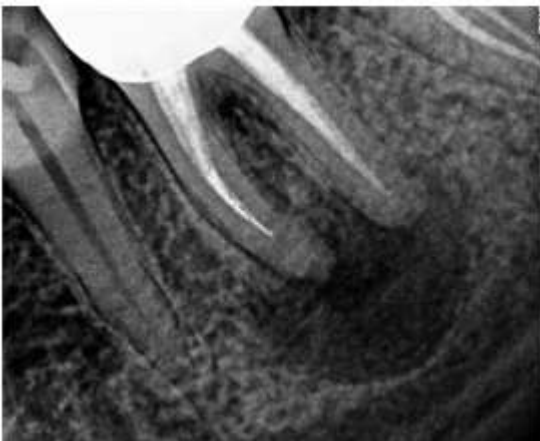


Fig A. Preoperative Radiograph Showing Periapical Radiolucency #36

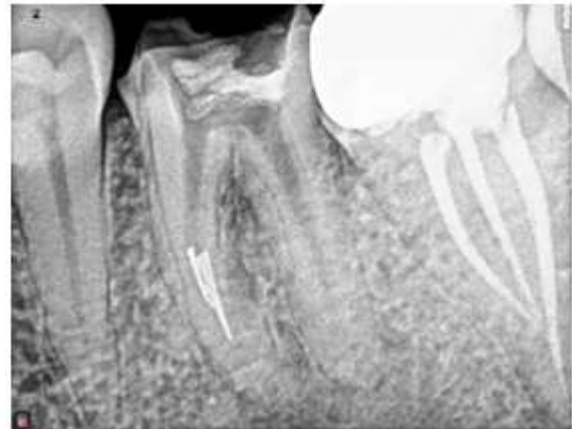

Fig B. Fractured Instrument in MB And ML Root Canals Of #36 After GP Removal

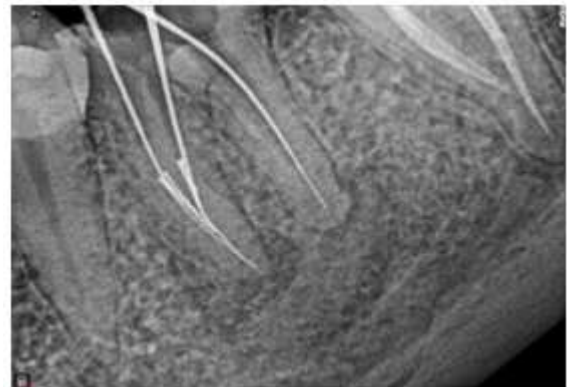


Fig C. Two Month Follow Up Radiograph Showing Healing Periapical Radiolucency #36 And Bypass of Separated Instrument with WL

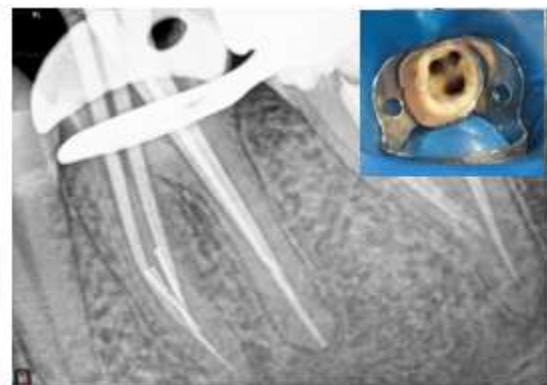


Fig D. Master cone Radiograph

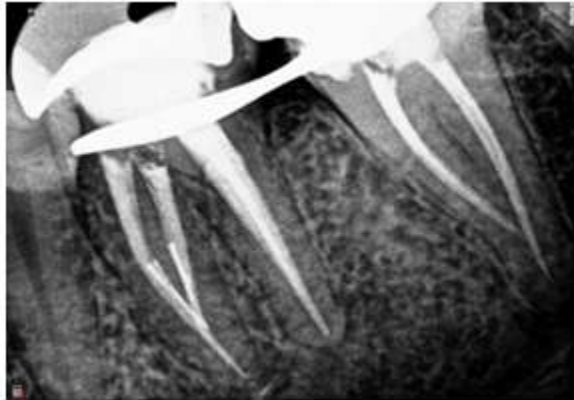


Fig E . Immediate Post Obturation

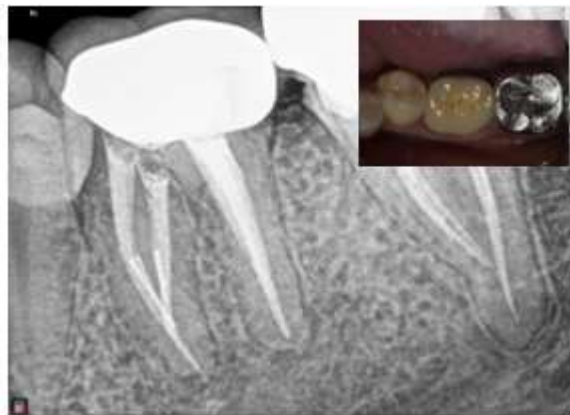

Fig F. Four Month Followup With PFM Crown In Place

III. DISCUSSION:

Procedural errors in endodontics may happen during every endodontic treatment. They can be the result of factors over which the operator may or may not have control.¹⁵ Intracanal separation of instruments usually prevents access to the apex, which impedes thorough cleaning and shaping of the root canal and thus may compromise with the outcome of endodontic treatment and reduce the chances of successful treatment.¹⁶

The separation of nickel–titanium rotary instruments was reported to range between 1.3% and 10%, whereas separation rates of stainless-steel instruments reported to range between 0.25% and 6%.^{17,18} There are many reasons for separation of rotary files but most common reasons are cyclic fatigue and torsional failure.¹⁹

Separated instruments can be handled conservatively or surgically. The conservative methods such as leaving the fragment in situ and filling the root canal to the coronal level of the instrument, bypassing

these segment or removing it from the root canal are considered favourable and preferred whenever possible.²⁰

The main determinant for removal of the separated instrument is the location of the fragment in the root canal and its relation to the root curvature.¹⁵ If the fragment is situated coronal to the curve, removal of the fragment is possible; on the other hand, if the separation occurs beyond the curvature the retrieval is deemed impossible. Attempts to remove fractured instruments can lead to ledge formation, over enlargement and transportation of prepared root canal or can lead to perforation. Hence the clinician has to evaluate the options of attempting to remove the instrument, bypassing it or leave the fractured fragment in the canal. The decision making should be made with the consideration for pulp status, canal infection, canal anatomy, position of the fragment and the type of fractured instrument.

This article describes a case of instrument separation management by instrument bypass. As the fragment separation is within and beyond the middle third curvature and also the two mesial canals of the mandibular molar have separated instruments canal exploration for retrieval will lead to more root dentine removal and at the same time the cleaning and shaping of apical third of mesial root canal got necessitated by periapical pathology involved.

IV. CONCLUSION:

The fractured instrument itself is not a reason for endodontic failure, but the results of the separation, such as blockage of the root canal and creating an obstacle for the proper instrumentation, irrigation and obturation may compromise the long-term prognosis of the tooth involved. Separation of endodontic instruments in the root canal does not necessarily lead to endodontic failure and even in cases when the instrument cannot be removed choosing the adequate treatment procedure can strongly benefit the long-term prognosis of the tooth involved.

REFERENCES

- [1]. Chandak M, Sarangi S, Dass A, Khubchandani M, Chandak R. Demystifying Failures Behind Separated Instruments: A Review. *Cureus*. 2022 Sep 26;
- [2]. Spili P, Parashos P, Messer HH. The Impact of Instrument Fracture on Outcome of Endodontic Treatment. 2005.
- [3]. McGuigan MB, Louca C, Duncan HF. Endodontic instrument fracture: Causes and prevention. *Br Dent J*. 2013 Apr 13;214(7):341–8.



- [4]. Kikly A, Nabiha D, Fouad B, Chadlia Belghith A, Glii W, Hodroj LF, et al. Broken file: bypass or ultrasonic removal technique Ology Broken file: bypass or ultrasonic removal technique. 2023; Available from: <https://www.researchgate.net/publication/372166566>
- [5]. Doumari B, Drouri S, El Kharroubi S, Skalli R, Benkiran I. Management of Intracanal Separated Instrument Using Bypassing and Braiding Techniques: Case Reports. *European Journal of Dental and Oral Health*. 2024 Feb 28;5(1):1–4.
- [6]. Vaudt J, Bitter K, Neumann K, Kielbassa AM. Ex vivo study on root canal instrumentation of two rotary nickel-titanium systems in comparison to stainless steel hand instruments. *Int Endod J*. 2009 Jan;42(1):22–33.
- [7]. Lopes HP, Ferreira AAP, Elias CN, Moreira E JL, Machado de Oliveira JC, Siqueira JF. Influence of Rotational Speed on the Cyclic Fatigue of Rotary Nickel-Titanium Endodontic Instruments. *J Endod*. 2009 Jul;35(7):1013–6.
- [8]. Adl A, Shahravan A, Farshad M, Honar S. Success rate and time for bypassing the fractured segments of four NiTi rotary instruments. *Iran Endod J*. 2017;12(3):349–53.
- [9]. Vouzara T, el C, Lyroudia K. Separated instrument in endodontics: Frequency, treatment and prognosis. *Balkan Journal of Dental Medicine*. 2018;22(3):123–32.
- [10]. Daokar Dr S. Endodontic Failures-A Review. *IOSR Journal of Dental and Medical Sciences*. 2013;4(5):5–10.
- [11]. Huuonen S, Ørstavik D. Radiographic follow-up of periapical status after endodontic treatment of teeth with and without apical periodontitis. *Clin Oral Investig*. 2013 Dec;17(9):2099–104.
- [12]. Fernández R, Cadavid D, Zapata SM, Álvarez LG, Restrepo FA. Impact of three radiographic methods in the outcome of nonsurgical endodontic treatment: A five-year follow-up. *J Endod*. 2013 Sep;39(9):1097–103.
- [13]. Clifford J, Ruddle DD. Nonsurgical retreatment: Post and Broken instrument Removal. *Journal of endodontics*. 2004(6):35–45.
- [14]. Ruddle CJ. Nonsurgical Endodontic Retreatment. *J Calif Dent Assoc* [Internet]. 1997 Nov 1;25(11):769–96. Available from: <https://www.tandfonline.com/doi/full/10.1080/19424396.1997.12221622>
- [15]. Choksi D, Idnani B, Kalaria D, Patel RN. Management of an Intracanal Separated Instrument: A Case Report. Vol. 8, *IEJ Iranian Endodontic Journal*. 2013.
- [16]. Kunhappan S, Kunhappan N, Patil S, Agrawal P. Retrieval of separated instrument with instrument removal system. *Journal of the International Clinical Dental Research Organization*. 2012;4(1):21.
- [17]. Crump MC, Natkin E. Relationship of broken root canal instruments to endodontic case prognosis: a clinical investigation. *J Am Dent Assoc*. 1970;80(6):1341–7.
- [18]. Al-Fouzan KS. Incidence of rotary ProFile instrument fracture and the potential for bypassing in vivo.
- [19]. Nair RK, Kurup N. Management of Instrument Separation: A Case Series. *Conservative Dentistry and Endodontic Journal*. 2019 Dec 1;4(2):39–43.
- [20]. Borisova-Papancheva T, Stankova S, Georgieva S. Conservative Management Of Intracanal Separated Endodontic Instruments Treatment Decisions And Related Factors. Vol. 3, *Scripta Scientifica Medicinae Dentalis*. 2017.