



Patterns of Mandible Involvement, Histopathological Features, and Clinical Outcomes in Gingivo-Buccal Complex Squamous Cell Carcinoma: A Tertiary Rural Centre Study

Patel D¹, Jain V², Thakur P², Sharma M¹, Pawar A¹, Bhatt D¹, Sangani H¹

¹ Junior Resident, Department of Radiation Oncology, DBVP Rural Medical College, PIMS, Loni, Maharashtra, India.

² Professor & Head, Department of Radiation Oncology, DBVP Rural Medical College, PIMS, Loni, Maharashtra, India.

Date of Submission: 03-02-2026

Date of Acceptance: 12-02-2026

ABSTRACT

Background:

Gingivo-buccal complex squamous cell carcinoma (GBC-SCC) is highly prevalent in India and is characterised by advanced presentation and frequent mandibular involvement. The pattern of bone invasion has important prognostic and therapeutic implications.

Objectives:

To evaluate patterns of mandibular involvement, associated histopathological features, and clinical outcomes in patients with GBC-SCC treated at a rural tertiary care centre.

Methods:

This prospective observational study was conducted at a tertiary care rural centre. It included histopathologically confirmed gingivo-buccal complex squamous cell carcinoma (GBC-SCC) patients who underwent definitive surgical management, with adjuvant therapy administered as indicated. Mandibular involvement was assessed using preoperative imaging, intraoperative findings, and histopathological examination, and categorised as absent, superficial cortical erosion, deep cortical erosion, marrow invasion, or mandibular canal involvement. Clinical outcomes, postoperative morbidity, and treatment response were systematically evaluated.

Results:

A total of 43 patients cases has been registered as per inclusion criteria. The cohort showed a strong male predominance with 33 patients (76.7%). Most patients presented with advanced disease, with 35 patients (81.4%) in Stage III–IV. Segmental mandibulectomy was required in cases with marrow or canal involvement, while marginal mandibulectomy was used for superficial erosion. Mandibular involvement was present in 13 patients (30.2%), most commonly superficial cortical erosion in 7 patients (16.3%). Perineural invasion in 4 patients (9.3%), lymphovascular invasion in 7 patients (16.3%), and extranodal extension in 10

patients (23.3%). An initial complete response was achieved in 32 patients (74.4%), but disease failure increased on follow-up. Trismus was the most frequent treatment-related morbidity, observed in 40 patients (93%).

Conclusion:

Depth and patterns of mandibular invasion emerged as important prognostic determinants in GBC-SCC (Gingivo-buccal complex-squamous cell carcinoma). Tumours with deep marrow and mandibular canal involvement were associated with more aggressive histopathological features and inferior clinical outcomes, often requiring segmental resection and intensified adjuvant therapy. These findings highlight the importance of early diagnosis and structured postoperative rehabilitation in improving survival and quality of life.

Keywords: Gingivo-buccal carcinoma, mandibular invasion, marginal mandibulectomy, segmental mandibulectomy, trismus, IMRT

I. INTRODUCTION

Squamous cell carcinoma of the oral cavity remains a major public health problem in India, with the gingivo-buccal complex being the most commonly affected subsite in tobacco-chewing populations [1,2]. GBC-SCC is distinct from other oral cancers due to its strong association with smokeless tobacco, advanced presentation, and high propensity for mandibular invasion [3,5].

Up to 62% of GBC-SCC cases show radiological or pathological of mandibular involvement at presentation [5,10]. The route of invasion may be superficial cortical erosion, medullary spread, or involvement of the mandibular canal via the inferior alveolar nerve [10,11]. These patterns have significant prognostic implications, influencing surgical decision-making and survival outcomes [9,10].

Recent evidence suggests that not all bone invasion is equivalent; deep marrow or canal involvement is associated with significantly worse



disease-free survival compared to superficial cortical erosion [6] influence. This has led to proposals such as the Marrow and Mandibular Canal (MMC) staging system, which better stratifies risk than conventional AJCC staging [6].

Histopathological factors such as poor differentiation, perineural invasion (PNI), lymphovascular invasion (LVI), depth of invasion, and pattern of invasion (POI) further influence prognosis and recurrence risk [14].

Given the high burden of GBC-SCC in rural India and the need for optimised management strategies, [16,17] this study aimed to analyse patterns of mandibular involvement, correlate them with histopathological features, and assess clinical outcomes.

II. MATERIALS AND METHODS

This prospective observational study was conducted in the Department of Radiation Oncology at a tertiary care rural hospital in Maharashtra, India, between January 2024 to January 2026. The study included histo-pathologically confirmed patients with gingivo-buccal complex squamous cell carcinoma (GBC-SCC) who underwent definitive surgical management, followed by adjuvant therapy where indicated. Approval was obtained from the Institutional Ethics Committee, and written informed consent was obtained from all participants in the local language.

All eligible patients who presented during the study period were enrolled consecutively, yielding a total sample of 43 patients. Only patients who underwent primary surgical treatment, had preoperative contrast-enhanced computed tomography (CECT) imaging available, and completed at least seven months and fifteen days of follow-up were included. Patients with distant metastasis at presentation, previous head and neck malignancy, or incomplete medical records were excluded.

Demographic and clinical variables, including age, gender, addiction history, primary tumour site, and clinical stage, were recorded. Preoperative CECT findings were used to assess mandibular involvement, which was further correlated with the final histopathology. Mandibular

involvement was classified as absent, superficial cortical erosion, deep cortical erosion, marrow invasion, or mandibular canal involvement.

Surgical management was planned based on the extent of mandibular involvement. Patients with superficial cortical erosion underwent marginal mandibulectomy, whereas those with deep cortical, marrow, or canal involvement underwent segmental mandibulectomy with appropriate reconstruction. Histopathological parameters, including tumour grade, depth of invasion, perineural invasion (PNI), lymphovascular invasion (LVI), and extranodal extension (ENE) were documented.

Adjuvant radiotherapy was delivered using intensity-modulated radiotherapy (IMRT) as per institutional protocol, based on pathological risk factors.

Treatment response was evaluated using RECIST 1.1 criteria at scheduled follow-ups. Patients were followed up clinically and radiologically at regular intervals to assess disease status and functional outcomes.

Statistical analysis was performed using descriptive statistics. Associations between categorical variables were analysed using the Chi-square test at a 5% level of significance.

III. OBSERVATIONS AND RESULTS

Patient Characteristics

The study included 43 histo-pathologically confirmed patients with gingivo-buccal complex squamous cell carcinoma (GBC-SCC). There was a marked male predominance, with 33 patients (76.7%) being male and 10 patients (23.3%) female. The majority of patients belonged to the 40–50-year age group, reflecting the cumulative exposure to tobacco-related carcinogens in this population.

Clinical Stage at Presentation

Most patients presented with locally advanced disease. Stage III–IV disease was observed in 35 patients (81.4%), and T4a tumours were documented in 11 patients (25.6%). Clinically node-negative disease (cN0) was present in 14 patients (32.6%), indicating a substantial burden of occult nodal disease despite advanced primary tumours.

Table 1: Clinicopathological Features of the Patients (n = 43)

Variable	Category	n (%)
Age (years)	<30	1 (2.3)
	30–40	6 (14.0)
	40–50	14 (32.6)
	50–60	10 (23.3)
	>60	12 (27.9)
Gender	Male	33 (76.7)



	Female	10 (23.3)
Primary site	Buccal mucosa	29 (67.4)
	Gingivo-buccal/labial sulcus	13 (30.2)
	Alveolar ridge	1 (2.3)
Histopathology (biopsy)	Well-differentiated SCC	22 (51.2)
	Moderately differentiated SCC	21 (48.8)
Stage grouping	Stage I	3 (7.0)
	Stage II	5 (11.6)
	Stage III	12 (27.9)
	Stage IVA	11 (25.6)
	Stage IVB	12 (27.9)

Patterns of Mandibular Involvement

Mandibular involvement was identified in 13 patients (30.2%). Among these, superficial cortical erosion was the most common pattern, observed in 7 patients (16.3%), followed by deep cortical erosion in 4

patients (9.3%). Marrow invasion and mandibular canal involvement were each seen in one patient (2.3%). The majority of patients (30/43; 69.8%) had no radiological or pathological evidence of mandibular involvement. [Figure 1]

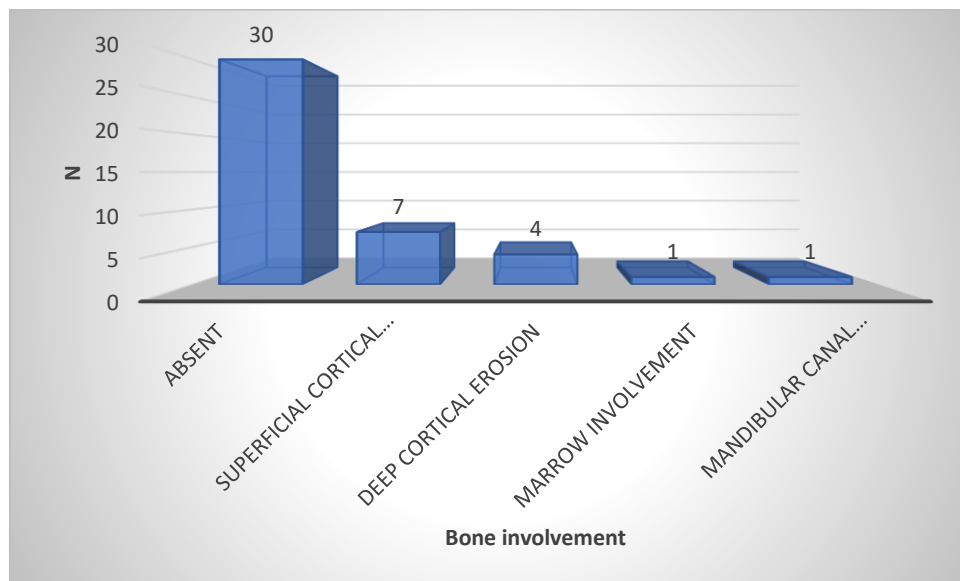


Figure 1: Bone involvement-wise distribution of the patients

Surgical Management and Reconstruction

Surgical management was individualised based on the extent of mandibular involvement. Among the 43 patients, wide local excision with reconstruction was the most common primary procedure, performed in 30 patients (69.8%), indicating that most tumours were suitable for clearance with adequate margins. Composite resection with reconstruction was required in 12 patients (27.9%), reflecting more extensive local disease, while bite resection was done in only 1 patient (2.3%). Regarding bony resection, no jaw resection was needed in 10 patients (23.3%). Marginal mandibulectomy was performed in 9 patients (20.9%), and hemi-mandibulectomy in 6 patients (14.0%). Partial maxillectomy was done in 3 patients (7%), and combined segmental

mandibulectomy with marginal maxillectomy in 1 patient (2.3%). All patients underwent neck dissection, with Modified Radical Neck Dissection (MRND) in 40 patients (93%) and Supra-omohyoid Neck Dissection (SOHND) in 3 patients (7%). Reconstruction was most commonly performed using a pectoralis major myocutaneous (PMMC) flap in 22 patients (51.2%), followed by free fibula flap in 10 patients (23.3%). Postoperative recovery was uneventful in 33 patients (76.7%).

Histopathological Findings

Moderately differentiated squamous cell carcinoma was the most frequent histological grade. Poor differentiation was significantly associated with deep bone invasion. Perineural invasion (PNI) was present in 4 patients (9.3), and extranodal extension (ENE)



was present in 10 patients (23.3%), and were more frequently observed in cases with medullary or canal involvement.

Adjuvant Treatment

All patients requiring adjuvant radiotherapy +/- chemotherapy received intensity-modulated radiotherapy (IMRT). The mean interval between surgery and initiation of radiotherapy was approximately seven weeks. Treatment compliance was satisfactory in 39 patients (90.7%), with only a

small proportion experiencing unplanned treatment interruptions.

Treatment Response and Follow-up

At the first follow-up, a complete response was achieved in 32 patients (74.4%). However, this declined to 28 patients (65.1%) at subsequent follow-ups, reflecting disease progression in a subset of patients. By the third follow-up, 6 patients (14%) had expired. [Figure 2]

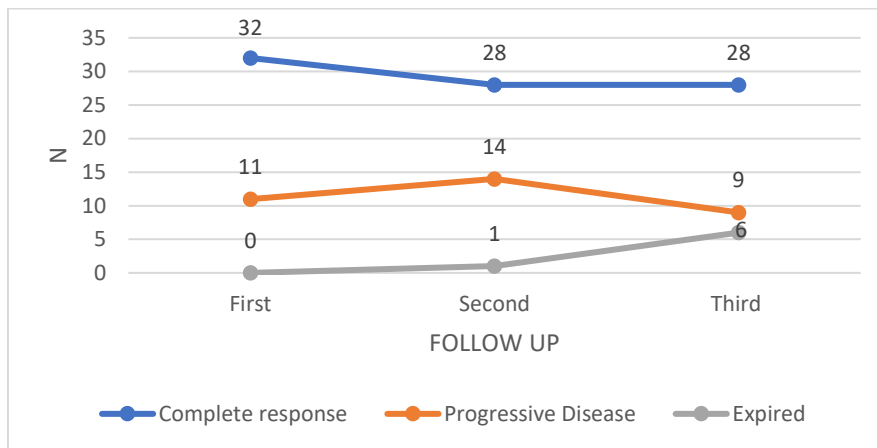


Figure 2: Follow up Response Status wise distribution of the study

Treatment-Related Morbidity

Trismus was the most common treatment-related morbidity, observed in 40 patients (93%), predominantly Grade I–III. Skin reactions were mostly Grade I, and low-grade mucositis was seen in 2 patients (4.7%). No life-threatening radiation toxicity was documented.

IV. DISCUSSION

Gingivo-buccal complex squamous cell carcinoma (GBC-SCC) represents a distinct subset of oral cavity malignancies in the Indian subcontinent and continues to impose a substantial disease burden, largely attributable to betel quid and areca nut chewing [1,2,3]. Despite advances in surgical techniques, radiotherapy planning, and multimodality treatment, locoregional failure, functional morbidity, and mortality remain significant challenges [4]. The present prospective observational study from a rural tertiary care centre in Maharashtra provides real-world insights into patterns of mandibular involvement, histopathological features, surgical decision-making, and clinical outcomes in GBC-SCC. The findings underscore the critical influence of tumour biology, depth of bone invasion, and healthcare access on treatment outcomes in a resource-limited setting [5,6].

In the present cohort, a high proportion of patients presented with advanced disease, with 81.4% in Stage III–IV and 25.6% having pT4a tumours. This pattern aligns with observations from Sankaranarayanan et al. and Coelho et al., who reported that oral cancers in rural India are frequently diagnosed at advanced stages due to patient-mediated delays, lack of awareness, and limited access to specialised care [7,8]. Similarly, Chaturvedi et al. highlighted that the site distribution and advanced presentation of GBC-SCC in India differ markedly from Western populations, where tongue and floor-of-mouth cancers are more common and present earlier [9].

The mean symptom duration before presentation in many Indian cohorts exceeds 4–5 months, which allows for progressive local extension into deeper tissues, including the mandible [10]. This delay remains a major contributor to poor outcomes, as advanced T stage is consistently associated with higher recurrence rates and inferior survival in oral squamous cell carcinoma (OSCC) [10, 11,20].

Mandibular invasion was identified in 30.2% of patients in this study, most commonly as superficial cortical erosion (16.3%). However, deeper patterns of invasion—such as deep cortical erosion, marrow invasion, and mandibular canal involvement—were associated with significantly



worse outcomes. These findings are consistent with Mahajan et al., who demonstrated that the depth and pattern of bone invasion have greater prognostic relevance than mere presence of bone involvement, proposing the Marrow and Mandibular Canal (MMC) staging system as superior to AJCC-8 T staging alone, as per Mahajan A et al. [12].

Similarly, Lee et al. reported that radiologically detected mandibular canal involvement was a stronger predictor of locoregional recurrence and mortality than histopathological perineural invasion alone, emphasising the importance of imaging-based assessment in preoperative planning (Brandwein-Gensler M et al) [14]. Chaukar et al. also demonstrated that routes of tumour entry into the mandible correlate with prognosis and should influence surgical decision-making, as per Ramasubramanian S et al. [15].

The present study supports these observations by demonstrating that patients with marrow or canal involvement required segmental mandibulectomy and had poorer disease control compared to those with only superficial cortical erosion, a finding also supported by Patel et al. and O'Brien et al. [18,17].

Histopathological features in this study showed a strong association with the depth of bone invasion. Perineural invasion (9.3%), lymphovascular invasion (16.3%), and extranodal extension (23.3%) were significantly more frequent in patients with deep mandibular involvement. Pandey et al. similarly demonstrated that marrow and canal invasion were commonly associated with aggressive histological features and higher nodal metastasis rates, as per Patel RS et al. [18].

Perineural invasion is particularly relevant in GBC-SCC because of the proximity to the inferior alveolar nerve. Tumours spreading along the mandibular canal often exhibit more aggressive behaviour and a higher risk of locoregional failure, as also reported by Lee et al. [14]. Brandwein-Gensler et al. further emphasised that the pattern of invasion and tumour budding are stronger prognostic markers than margin status alone, as per Nutting CM et al. [19].

These findings reinforce the need for routine reporting of depth of invasion, pattern of invasion, PNI, LVI, and ENE in pathology reports, as they provide crucial prognostic information beyond conventional TNM staging, as per Nutting CM et al. and Cooper JS et al. [19,20].

Surgical management in this study was appropriately tailored to the extent of mandibular involvement. Marginal mandibulectomy was performed for superficial cortical erosion, preserving mandibular continuity and improving functional

outcomes, consistent with recommendations by Shah and Patel et al. [16,21]. In contrast, segmental mandibulectomy was required for deep cortical, marrow, or canal involvement to achieve oncologically safe margins, as supported by Mahajan et al. and O'Brien et al. [12,17].

Although segmental mandibulectomy increases reconstructive complexity and postoperative morbidity, it remains essential for adequate disease control in advanced cases [16,17,18]. The predominance of PMMC flap reconstruction (51.2%) in this cohort reflects pragmatic decision-making in a rural setting, balancing cost, expertise, and postoperative recovery, as also described by Shah JP et al. [16].

All high-risk patients in this study received IMRT-based adjuvant radiotherapy +/- chemotherapy. IMRT has been shown to reduce toxicity while maintaining excellent locoregional control, particularly by sparing critical structures such as the mandible, parotid glands, and spinal cord, as demonstrated in the PARSPORT trial as per Nutting CM et al. [19].

The high compliance rate (90.7%) and acceptable mean time to radiotherapy +/- chemotherapy initiation (~7 weeks) are commendable in a rural tertiary care centre. However, literature consistently suggests that delays beyond 6–8 weeks after surgery are associated with higher recurrence rates, emphasising the need for further reduction in treatment intervals, as per Nutting CM et al [19].

Although an initial complete response was achieved in 74.4% of patients, this declined to 65.1% on subsequent follow-ups, with 14% mortality by the third follow-up. This pattern is characteristic of locally advanced head and neck cancers, where early locoregional control is often followed by later failures in a biologically aggressive subset of patients, as per Zhu Y et al. and Mahajan A et al. [5,6].

Cooper et al. demonstrated that patients with ENE, PNI, or positive margins benefit significantly from concurrent chemoradiation, suggesting that risk-adapted intensification of therapy may improve outcomes in high-risk GBC-SCC, as per Cooper JS et al. [20].

A striking finding of this study was the very high incidence of trismus (93%), predominantly Grade I–III. Dijkstra et al. reported similar findings and emphasised that trismus results from fibrosis of masticatory muscles due to combined surgical trauma and radiotherapy, as per Dijkstra PU et al. [21].

This study strongly supports the need for mandatory prehabilitation and structured postoperative physiotherapy programs, including jaw exercises and stretching devices, to reduce long-term



disability and improve quality of life, as per Dijkstra PU et al. [21].

The decline in complete response over time and the strong impact of mandibular invasion patterns suggest that conventional AJCC TNM staging alone is insufficient to fully capture tumour aggressiveness in GBC-SCC [6,13,14]. Incorporating radiological bone invasion patterns, depth of invasion, and histopathological risk factors (PNI, LVI, ENE) into staging systems may provide better prognostic stratification, as per Mahajan A et al, Lee C et al. and Brandwein-Gensler M et al. [6,13,14].

Future research should focus on integrating imaging-based bone invasion patterns with molecular biomarkers and tumour budding models to refine risk assessment and personalise treatment strategies as per Brandwein-Gensler M et al. [14].

V. CONCLUSION

This prospective observational study provides important insights into patterns of mandibular involvement, surgical management, treatment outcomes, and functional morbidity in patients with gingivo-buccal complex squamous cell carcinoma treated at a rural tertiary care centre. Most patients presented with advanced-stage disease, reflecting delayed diagnosis in a resource-limited setting. Mandibular invasion was observed in nearly one-third of patients, with deeper patterns of bone involvement associated with more aggressive histopathological features and poorer clinical outcomes.

Overall, the study findings highlight the critical interplay between tumour biology, depth of mandibular invasion, stage at diagnosis, surgical decision-making, and access to timely adjuvant therapy. Strengthening early detection of oral cancers, improving referral pathways, ensuring timely multimodality treatment, and implementing structured rehabilitation programs—especially for trismus—are essential to improve survival, functional outcomes, and quality of life in patients with GBC-SCC, particularly in rural and resource-constrained settings.

VI. LIMITATIONS

The relatively small sample size, single-centre design, and limited follow-up duration for some patients may restrict the generalizability of the findings. The absence of multivariate analysis and limited access to advanced imaging or molecular profiling further constrain detailed prognostic evaluation.

REFERENCES

- [1]. Warnakulasuriya S. Global epidemiology of oral and oropharyngeal cancer. *Oral Oncol.* 2009;45:309-16.
- [2]. Gupta B, Johnson NW, Kumar N. Global epidemiology of head and neck cancers: a continuing challenge. *Oncology.* 2016;91(1):13-23.
- [3]. IARC Working Group. Betel-quid and areca-nut chewing and some areca-nut derived nitrosamines. *IARC Monogr Eval Carcinog Risks Hum.* 2004;85:1-334.
- [4]. Misra S, Chaturvedi A, Misra NC. Management of gingivobuccal complex cancer. *Ann R Coll Surg Engl.* 2008;90:546-53.
- [5]. Zhu Y, Li B, Liu H, et al. Prognostic factors and related complications/sequelae of squamous cell carcinoma located in the gingivobuccal complex. *World J Surg Oncol.* 2022;20:240.
- [6]. Mahajan A, Dhone N, Vaish R, et al. Prognostic impact of pattern of mandibular involvement in gingivo-buccal complex squamous cell carcinomas: Marrow and Mandibular Canal staging system. *Front Oncol.* 2022;11:752018.
- [7]. Sankaranarayanan R, Ramadas K, Amarasinghe H, et al. Oral cancer: prevention, early detection, and treatment. In: *Cancer: Disease Control Priorities.* 3rd ed. World Bank; 2015.
- [8]. Coelho KR. Challenges of the oral cancer burden in India. *J Cancer Epidemiol.* 2012;701932.
- [9]. Chaturvedi P, Vaishampayan SS, Nair S, et al. Oral SCC arising in oral submucous fibrosis: a distinct disease. *Head Neck.* 2013;35:1404-10.
- [10]. Pandey M, Rao LP, Das SR, et al. Patterns of mandibular invasion in oral SCC of the mandibular region. *World J Surg Oncol.* 2007;5:12.
- [11]. Chaukar DA, Dandekar M, Kane S, et al. Routes of mandibular invasion in GBC cancers: histopathology and imaging correlation. *Oral Oncol.* 2018;86:181-7.
- [12]. Mahajan A, Ahuja A, Sable N, et al. Imaging in oral cancers: comprehensive overview. *Oral Oncol.* 2020;104:104658.
- [13]. Lee C, Choi YJ, Jeon KJ, et al. Prognostic implications of combined imaging and histologic criteria in SCC with mandibular invasion. *J Clin Med.* 2020;9(5):1335.
- [14]. Brandwein-Gensler M, Teixeira MS, Lewis CM, et al. Histologic risk assessment in oral SCC. *Am J Surg Pathol.* 2005;29:167-78.



- [15]. Ramasubramanian S, Pandiar D, Krishnan RP, et al. Correlation of bony invasion with nodal metastasis and survival in oral SCC. *Cureus*. 2023;15:e42887.
- [16]. Shah JP. The role of marginal mandibulectomy in oral cancer. *Arch Otolaryngol Head Neck Surg*. 2002;128:604-5.
- [17]. O'Brien CJ, Adams JR, McNeil EB, et al. Influence of bone invasion and extent of mandibular resection on local control. *Int J Oral Maxillofac Surg*. 2003;32:492-7.
- [18]. Patel RS, Dirven R, Clark JR, et al. Prognostic impact of extent of bone invasion in oral carcinoma. *Laryngoscope*. 2008;118:780-5.
- [19]. Nutting CM, Morden JP, Harrington KJ, et al. PARSPORT trial: IMRT vs conventional radiotherapy in head and neck cancer. *Lancet Oncol*. 2011;12:127-36.
- [20]. Cooper JS, Pajak TF, Forastiere AA, et al. Postoperative chemoradiotherapy for high-risk head and neck cancer. *N Engl J Med*. 2004;350:1937-44.
- [21]. Dijkstra PU, Huisman PM, Roodenburg JL. Criteria for trismus in head and neck oncology. *Int J Oral Maxillofac Surg*. 2006;35:337-42.