



Post Hanging Unilateral Vocal Cord Palsy- A Case Report

Dr. Virginia Pame, Dr. Musuka. G. Narzary, Dr. Smrity Rupa Borah Dutta

Final Year Department Of Ent, Silchar Medical College

Senior Resident Department Of Ent, Silchar Medical College

Head Of The Department Department Of Ent, Silchar Medical College

Submitted: 15-10-2022

Accepted: 31-10-2022

I. INTRODUCTION

Hanging is a leading cause of suicide with high mortality rate of 70%. Due to which complications in the survivors after typical hanging have not been well characterized. Vocal cord paralysis is a rare complication.

Vocal cord palsy can occur due to many causes. The most common being during thyroid surgery, followed by malignant neoplasms, trauma i.e. hyoid bone fracture and central nervous system disorders. Sometimes it can be idiopathic also.

Respiratory symptoms such as hoarseness, and dyspnea could occur after vocal cord palsy which may require surgery.

Here, we present a case of unilateral vocal cord palsy in a patient of typical hanging.

II. CASE HISTORY

A 75-year-old man presented to the emergency department following suicidal hanging. He was immediately shifted to ICU as he was not

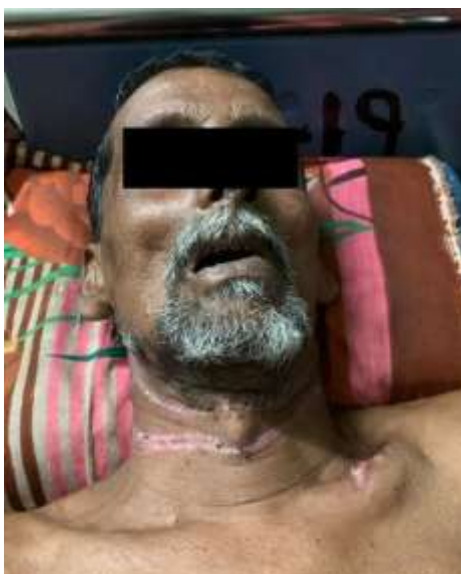maintaining SPO₂ (78%) in room air. After 1 week of conservative treatment in ICU he was shifted to ENT department after his vitals were stabilized.

The patient then gradually developed breathy voice, hoarseness and inability to speak loudly and weak cough. Following which the patient was advised for direct laryngoscopy and CT scan.

The patient's airway remained stable and was therefore treated conservatively. Tracheostomy was not required.

INVESTIGATION

- RBC was within normal limits.
- Xray soft tissue neck was normal.
- CT scan showed medialization of right vocal cord with no disruption of laryngeal framework.
- Direct laryngoscopy showed failure of the left sided vocal cord to adduct with compensatory medialization of right vocal cord.



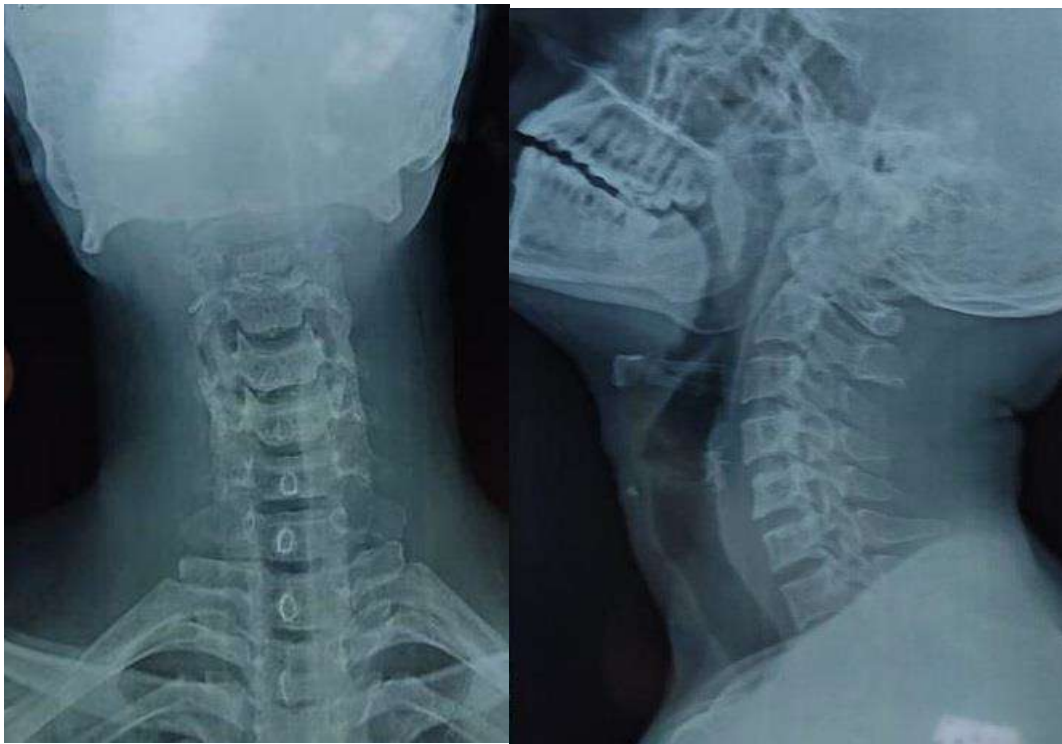


FIG.1 X-Ray neck AP and Lateral view

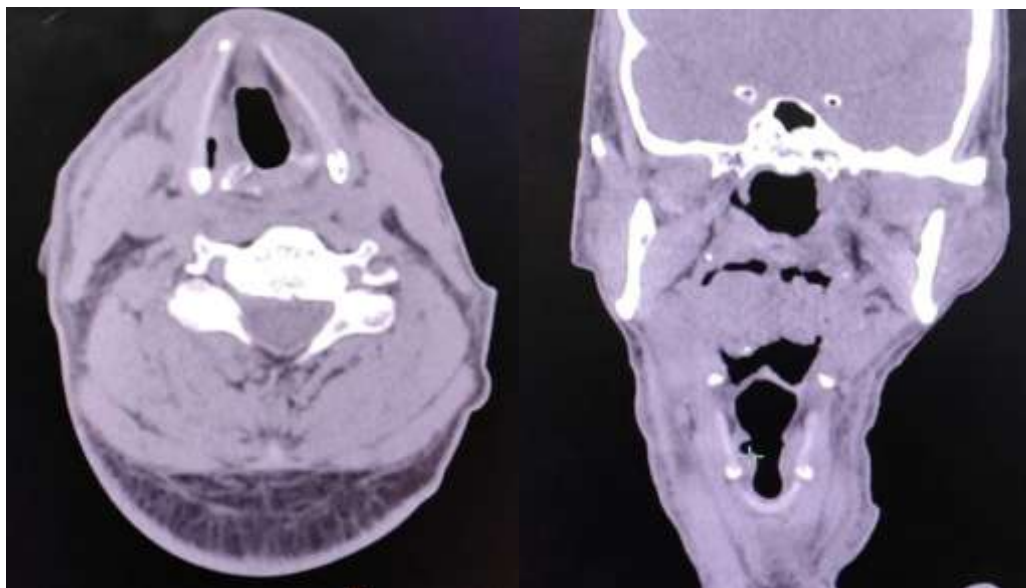


FIG.2- Non enhancedCT scan of neck

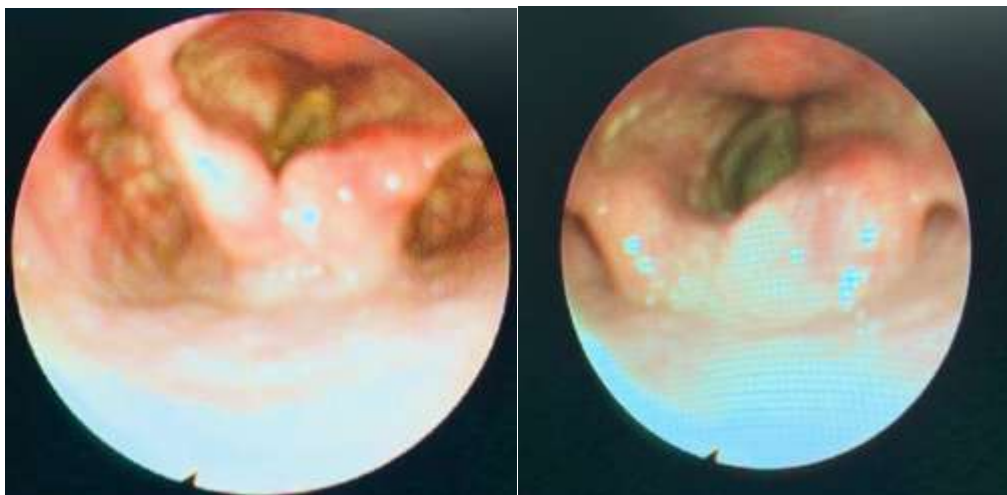


FIG.3- Laryngoscopic view of Vocal cords

III. DISCUSSION

In this case, the patient was apparently normal before and immediately after the suicidal hanging. Later on, he gradually developed signs of vocal cord palsy. No swelling, oedema or subcutaneous emphysema was seen. Although his Xray soft tissue neck was normal, his CT scan showed medialization of right vocal cord with no disruption of laryngeal framework. There is failure of left sided vocal cord to adduct when visualized through direct laryngoscopy. Our case report indicates that impaired unilateral vocal cord movement following neck injury could become apparent after hospitalization and may improve with conservative management without the need of surgical intervention.

IV. CONCLUSION

Vocal cord paralysis is uncommon following typical hanging although other traumatic causes amount to about one-third cases of laryngeal nerve palsies. Hence, careful assessment of the airways in patients following hanging is necessary to evaluate laryngeal nerve injury.

REFERENCES

- [1]. Levine RJ, Sanders AB, LaMear WR. Bilateral vocal cord paralysis following blunt trauma to the neck. *Ann. Emerg. Med.* 1995; 25: 253–5
- [2]. Uzun I, Buyuk Y, Gurpinar K. Laryngo-hyoid fractures in suicidal hanging: a prospective autopsy study with an updated review and critical appraisal. *J. Forensic Leg. Med.* 2017; 14: 406–9
- [3]. Latoo M, Lateef M, Nawaz I, Ali I. Bilateral recurrent laryngeal nerve palsy following blunt neck trauma. *Indian J.*

Otolaryngol. Head Neck Surg. 2007; 59: 298–9.

- [4]. Singh B, Kumar S, Kumar V. Blunt laryngotracheal injury following accidental strangulation. *Injury.* 2003 Dec;34(12):937–939