



Primary Ewings sarcoma of kidney: A case report.

Taskeen Mehmood^[1], Aadil Najeed^[2], Mushtaq Ahmad Sofi^[3], Huma Mehmood^[4]

^[1]Senior Resident, Department of Radiation Oncology, SKIMS, Srinagar, J&K, India.

^[2]MD Resident, Department of Radiation Oncology, SKIMS, Srinagar, J&K, India.

^[3]Assistant Professor, Department of Radiation Oncology, SKIMS, Srinagar, J&K, India.

^[4]Senior Resident, Department of Pathology, GMC Srinagar, J&K, India.

Date of Submission: 05-05-2023

Date of Acceptance: 15-05-2023

ABSTRACT:

One of the rarest tumours in adulthood is extra-skeletal Ewing's sarcoma, which accounts for fewer than 1% of renal tumours.. The primary location of a tumour determines the clinical features leading to non specific signs and symptoms, with the radiological imaging being non specific too and and diagnosis dependent on pathological findings, the early treatment is compromised when more common tumours are lined as differentials. This results into to the poor prognosis overall as it is a high grade malignant tumour showing early metastasis. We present a first of its kind case from kashmir. Therefore, this entity ought to always be considered when dealing with renal masses in young patients.

Keywords: Ewings Sarcoma, Renal Mass, Chemotherapy.

I. INTRODUCTION:

The Ewing's sarcoma family of tumors represents a group of small round cell neoplasms including:

- Osseous and extra osseous Ewing's sarcoma.
- Soft tissue primitive neuroectodermaltumors (PNET).
- Askin's Tumour(1).

However Ewing's sarcoma and Primitive neuroectodermal tumours were originally described as two distinct entities but since both share cytogenetic and histologically characteristics, they have been clubbed in Ewing's sarcoma family of tumours (2). With only a few hundred instances recorded globally, Ewing's sarcoma of the kidney is one of a small number of renal primary sarcomas. (3). The vague presentation along with non indicative radiological findings and its rarity lead to Ewing's sarcoma being mistaken for other more prevalent tumours of kidney(4). In addition to that renal Ewing's sarcoma is a highly malignant rapidly growing tumour that metastasises early to lung, bone and lymph node, thus making it indispensable to distinguish it from other renal entities (5). Here we present a case of adult renal

ewings sarcoma who was diagnosed and managed in our hospital.

II. CASE PRESENTATION:

A 35 year old male, smoker, no co morbidities presented to us with colicky pain in left flank since two months, which was relieved by over the counter analgesics. He also had hematuria for the same duration. He had no other significant medical history. Due to deterioration of symptoms an Ultrasonography of abdomen and pelvis was performed which revealed a solid lesion at mid pole of left kidney extending upto upper pole, measuring 8.32*6.15*7.53 cms. A CT urography was done which showed similar findings of a 9.6*8.1 cm mass occupying the mid pole of left kidney and bulging into renal pelvis. A staging CECT of chest, abdomen and pelvis was performed which described the said lesion with rest of the scan being normal. In order to confirm the diagnosis an ultrasound guided biopsy of left renal mass was performed, which on histopathological examination showed features of Ewing's sarcom/ primitive neuroectodermal tumour. Further staging work up was done in form of PET-CT which showed a 10.6*6.8cm mass in left kidney with SUV max of 22.3. The bone marrow was reported normal on pathological examination.

The diagnosis was confirmed by the histopathological examination and Immuno histochemistry. Patient was subsequently treated with multi agent chemotherapy.

III. DISCUSSION:

Renal cell carcinoma is the cause of more than 90% of kidney masses while renal sarcomas are rare variety of neoplasms, accounting for <1% of masses in kidney.Ewing's sarcoma of kidney is a very aggressive tumour that predominantly affects young adults with slight male predominance(6).

Sarcomas of kidney usually tend to be asymptomatic unless large enough to produce signs and symptoms, with average size ranging anywhere



between 5.5 to 23cms. The clinical features are uncharacteristic occurring in decreasing frequency of pain [85%], palpable mass [60%] and hematuria [37%] (7). The imaging on ultrasonography, computer tomography or magnetic resonance imaging of renal sarcomas and renal cell carcinoma are indistinguishable. Therefore the diagnosis is based on pathological findings and immuno histochemistry(8).

Ewing's sarcoma of kidney is a particularly aggressive tumour showing early metastasis, with most common site being lungs followed by liver and bone. On presentation 25 to 50% of patients have already developed metastasis(9). As a result Ewing's sarcoma of kidney requires aggressive treatment, however there is no consensus on its treatment. Most commonly it has been treated with surgical resection (radical nephrectomy) followed by adjuvant systemic therapy. The cytotoxic agents that have been used include vincristine, Ifosfamide, Doxorubicin, Actinomycin D, Etoposide and Cyclophosphamide. Radiotherapy upto a dose of 50 to 60Gy has been employed only in case of residual disease or positive margins in adjuvant settings(10).

Despite aggressive treatment the prognosis and survival rate of renal Ewing's sarcoma patients is dismal, with median survival being 15 months however those with disease restricted to kidney 5y overall survival is 45 to 55%(11).

IV. CONCLUSION:

Ewing's sarcoma of kidney is a rare and infrequent diagnosis of renal malignancy. It occurs in young adults and tends to be highly aggressive with non specific clinical and radiological features. The diagnosis is based on histopathology and immuno histochemistry. Thus all these factors cause delay in diagnosis and treatment of a highly aggressive tumour. Therefore Ewing's sarcoma of kidney should always be considered among differentials in young patients with renal mass.

Consent:

The patient's and his attendant's written informed consent was acquired before the report and its accompanying photos could be published.

Funding:

Authors declare that no grant was received for this research from any funding agency in the public, commercial or not for profit sectors.

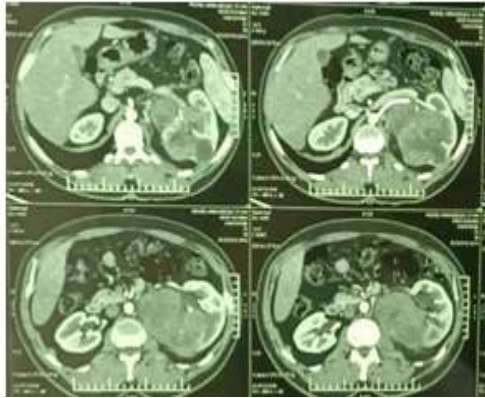
Competing Interest:

Authors declare there is no conflict of interest.

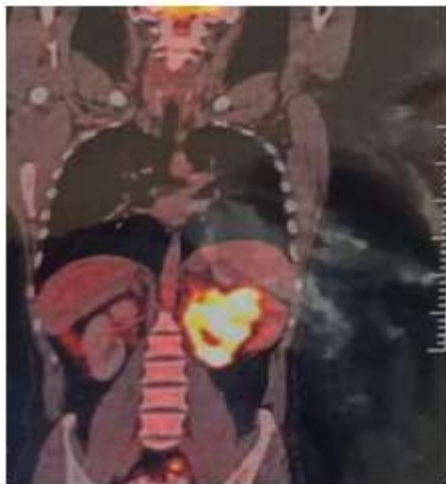REFERENCES:

- [1]. Potratz, J.C.; Dirksen, U.; Jürgens, H.; Craft, A. Ewing Sarcoma: Clinical State-of-the-Art. *Pediatr. Hematol. Oncol.* 2012, 29, 1–11.
- [2]. Maria Fernanda Arruda Almeida, Madhavi Patnana, Brinda Rao Korivi, Neda Kalhor, and Leonardo Marcal; Ewing Sarcoma of the Kidney: A Rare Entity, Case Reports in Radiology Volume 2014, Article ID 283902.
- [3]. J.Ellinger, P.J.Bastian, S.Hauser, K.Bierman n, and S.C.Mu'ller, "Primitive neuroectodermaltumor: rare, highly aggressive differential diagnosis in urologic malignancies," *Urology*, vol. 68, no. 2, pp. 257–262, 2006.
- [4]. Boulay, G.; Sandoval, G.J.; Riggi, N.; Iyer, S.; Buisson, R.; Naigles, B.; Awad, M.E.; Rengarajan, S.; Volorio, A.; McBride, M.J.; et al. Cancer-Specific Retargeting of BAF Complexes by a Prion-like Domain. *Cell* 2017, 171, 163–178.e19.
- [5]. Li Cheng, Yujie Xu, Hong Song, Houbao Huang and Dong Zhuo; A rare entity of Primary Ewing sarcoma in kidney; *BMC Surg* (2020) 20:280
- [6]. Apratim Roy Choudhury, Swarna Gupta Jain, Anjuna Reghunath, Rohini Gupta Ghasi, Navpreet Kaur and Sachin Kolte; Primary Ewing's sarcoma of the kidney: a rare masquerader of renal cell carcinoma on imaging; *Egypt J Radiol Nucl Med* (2022) 53:53.
- [7]. J. R. Angel, A. Alfred, A. Sakhuja et al., "Ewing's sarcoma of the kidney," *International Journal of Clinical Oncology*, vol. 15, pp. 314–318, 2010
- [8]. R. E. Jimenez, A. L. Folpe, R. L. Lapham et al., "Primary Ewing's sarcoma/primitive neuroectodermaltumor of the kidney: a clinicopathologic and immunohistochemical analysis of 11 cases," *American Journal of Surgical Pathology*, vol. 26, no. 3, pp. 320–328, 2002.
- [9]. Doroudinia a, ahmadi s, Mehrian p, et al. *BMJ Case Rep* 2019;12:e227198. doi:10.1136/bcr-2018-227198
- [10]. Muhammad Sadiq, Iftikhar Ahmad, Jamila Shuja, Khushnaseeb Ahmad; Primary Ewing sarcoma of the kidney: a case report and treatment review; *CEN Case Rep*.

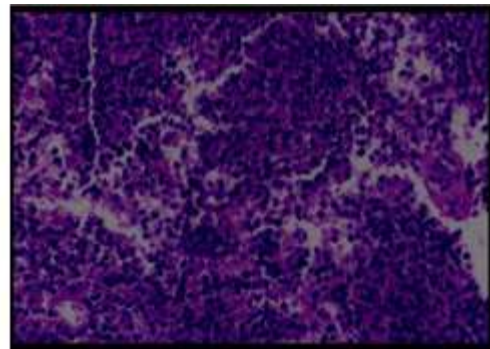
- [11]. Krishnendumaiti, Akash Agarwal, Chanda Datta, Dilip Kumar pal; Primary Ewings Sarcoma of Kidney: A Case Report; Journal of Clinical and Diagnostic Research. 2018 Jun, Vol-12(6): PD03-PD04.




(a). CT image of left renal mass.



(b). PET CT image of left renal mass



(c). HPE



(D). CD 99 FLI-1 DESMIN