



Pyrexia of Unknown Origin in a Patient with Ankylosing Spondylitis: A Rare Case of Concurrent Adult-Onset Still's Disease

Dr Anamitra Hait¹, Dr.Sarbani Sengupta², Dr Arbind Kumar Chaudhary^{3**}

1. Assistant Divisional Medical Officer Of Indian Railways Medical Service , In-Charge Of ICU And Internal Medicine, K G Hospital, Chittaranjan Locomotive Works, Chittaranjan, Paschim Bardhaman, Pin 71331,

2. Ex HOD of HOD/ Medicine and Rheumatology , medicine department of B R Singh hospital ,Parikshit Roy Lane, Near Sealdah Bus Stop, Beliaghata, Kolkata, West Bengal 700009

3. Assistant Professor Of Pharmacology, Government Erode Medical College And Hospital, Tamil Nadu, India

Submitted: 25-11-2024

Accepted: 05-12-2024

ABSTRACT

Background: Ankylosing spondylitis (AS) is a chronic inflammatory disease affecting the axial skeleton, with systemic symptoms such as fever being uncommon. Adult-onset Still's disease (AOSD) is an autoinflammatory condition characterized by high-grade fever, rash, and polyarthritis. The co-occurrence of AS and AOSD is extremely rare and presents significant diagnostic challenges. This case report outlines the complexities involved in identifying and managing such an overlap.

Case Presentation: A 37-year-old male with a history of AS presented with pyrexia of unknown origin (PUO), bilateral asymmetric polyarthritis, and a transient skin rash. Laboratory findings showed elevated inflammatory markers (CRP: 322 mg/L, ESR: 82 mm/hr), hyperferritinemia (>10,000 ng/mL), hyperleukocytosis (16,000/mm³) with neutrophil predominance, and normocytic normochromic anemia (hemoglobin: 9 g/dL). Extensive infectious and immunological investigations were negative, while PET CT revealed metabolically active lymphadenopathy. Biopsies excluded malignancy and macrophage activation syndrome. A diagnosis of AOSD was established based on Fautrel and Yamaguchi criteria. The patient's treatment was shifted from NSAIDs to corticosteroids (prednisone 1 mg/kg/day), leading to significant improvement, followed by maintenance therapy with DMARDs to sustain remission.

Conclusion: This case highlights the importance of considering AOSD in AS patients presenting with PUO and systemic inflammation. Timely diagnosis and appropriate treatment can reduce complications. Further studies are needed to explore the pathophysiological links and optimize management strategies.

Keywords: Ankylosing spondylitis; Adult-onset Still's disease; Pyrexia of unknown origin; Systemic inflammation; PET-CT scan; Sacroiliitis; Hyperferritinemia; Lymphadenopathy; Autoimmune diseases; Hypermetabolic activity.

I. INTRODUCTION

Ankylosing spondylitis (AS) is a chronic inflammatory disease primarily affecting the axial skeleton, leading to progressive stiffness and pain. It is the most prevalent form of spondyloarthritis, with hallmark features including sacroiliitis and enthesitis. Systemic manifestations such as fever are uncommon in AS, and their presence often prompts consideration of alternative or concurrent diagnoses. Adult-onset Still's disease (AOSD) is a rare systemic autoinflammatory disorder characterized by high spiking fevers, evanescent salmon-colored rash, and arthritis. The etiology of AOSD remains elusive, but it is believed to involve dysregulation of the innate immune system, leading to excessive production of pro-inflammatory cytokines such as interleukin-1 (IL-1), interleukin-6 (IL-6), and tumor necrosis factor-alpha (TNF- α) (Jamilloux et al., 2014). The simultaneous occurrence of AS and AOSD is exceedingly rare, with limited cases documented in medical literature. A case series by Akkoc et al. (2008) reported three patients with AS and one with axial spondyloarthritis who also fulfilled the criteria for AOSD, highlighting the diagnostic challenges posed by overlapping clinical features. Similarly, Niasse et al. (2021) described a Senegalese patient with AS who developed AOSD, emphasizing the need for heightened clinical vigilance in such scenarios(1,2,3).

The objective of this case report is to present a rare instance of a patient with established AS who developed pyrexia of unknown origin (PUO), ultimately diagnosed as AOSD. This case



underscores the importance of considering AOSD in AS patients presenting with unexplained fever and systemic inflammatory signs, after excluding infectious and neoplastic causes.

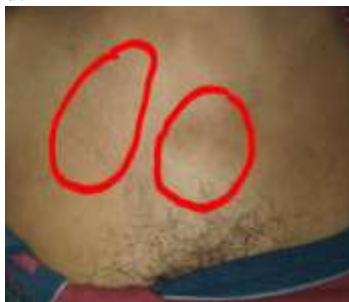II. CASE PRESENTATION

Patient Information

A 37-year-old male, previously diagnosed with ankylosing spondylitis (AS) in 2021 based on the ASAS and modified New York criteria, presented with a radiographic axial form of the disease. The patient was HLA-B27 positive and had been managed with nonsteroidal anti-inflammatory drugs (NSAIDs) for symptom control since diagnosis.

Clinical Features

In January 2022, the patient developed pyrexia of unknown origin (PUO), with fever fluctuating between 38°C and 39.5°C for one month. Additional symptoms included bilateral asymmetric polyarthritis and a transient, evanescent skin rash that resolved spontaneously. On physical examination, small, palpable axillary lymph nodes were noted.



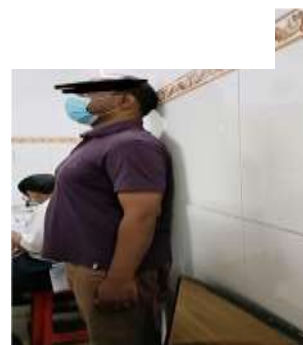Pic.1: Axillary lymphadenopathy highlighted by red markings, indicating systemic inflammation.



Pic.2: Kyphotic posture with structural deformity and pelvic imbalance due to ankylosing spondylitis.



Pic.3: Forward bending test showing restricted lumbar spine flexibility, suggesting spinal ankylosis.



Pic.4: Loss of lumbar lordosis and thoracic spine mobility evident in standing posture against the wall.



Pic.5: Limited forward bending reflecting thoracolumbar stiffness and restricted hamstring flexibility.

Diagnostic Workup

The patient underwent an extensive diagnostic evaluation (summarized in **Table 1**). Key findings included:

- Elevated markers of inflammation: CRP (322 mg/L) and ESR (82 mm/hr).
- Severe hyperferritinemia (>10,000 ng/mL, 100 times normal levels).
- Hyperleukocytosis (16,000/mm³) with neutrophil predominance (87%).



- Normocytic normochromic anemia with hemoglobin at 9 g/dL and a normal platelet count of 420,000/mm³.
- Mildly elevated AST (50 IU/L) with normal ALT levels (37 IU/L).
- Negative results for infectious markers, including hepatitis, HIV, and tuberculosis, as well as autoimmune markers like rheumatoid factor, anti-CCP antibodies, and antinuclear antibodies.
- PET-CT revealed metabolically active lymphadenopathy (Figure 1).
- Biopsies of bone marrow and lymph nodes demonstrated reactive hyperplasia with no

evidence of malignancy or macrophage activation syndrome.

The diagnosis of **adult-onset Still's disease (AOSD)** was made using the **Yamaguchi criteria**:

- **Major criteria:** Persistent fever, bilateral polyarthritis, transient evanescent rash, and leukocytosis with neutrophil predominance.
- **Minor criteria:** Axillary lymphadenopathy, abnormal liver function (elevated AST), and negative autoimmune markers.
- **Exclusion of other causes:** Comprehensive workup ruled out infections and malignancies.

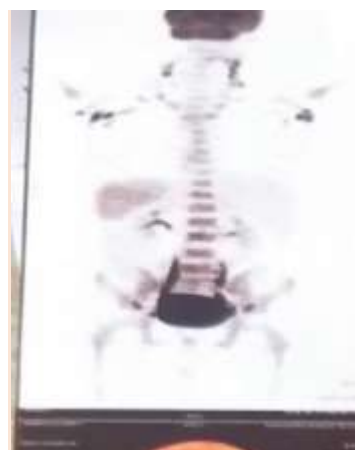The patient fulfilled **four major criteria** and **three minor criteria**, exceeding the diagnostic

Table 1. Laboratory and Diagnostic Findings

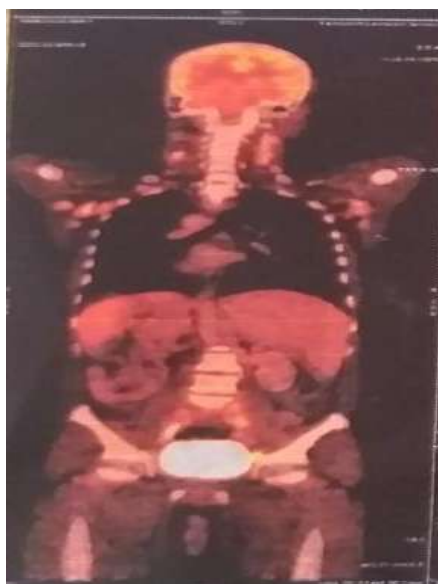Test	Result	Normal Range
CRP	322 mg/L	<5 mg/L
ESR	82 mm/hr	<20 mm/hr
Ferritin	>10,000 ng/mL	20–300 ng/mL
Leukocyte Count	16,000/mm ³	4,000–11,000/mm ³
Neutrophils	87%	40–75%
Hemoglobin	9 g/dL	13–17 g/dL
Platelets	420,000/mm ³	150,000–450,000/mm ³
AST	50 IU/L	5–40 IU/L
ALT	37 IU/L	5–40 IU/L
Autoimmune Markers	Negative	Negative
PET-CT	Metabolically active lymph nodes	No activity
Bone Marrow Biopsy	Reactive hyperplasia	No abnormalities

Radiological Examination

Radiological evaluation was pivotal in diagnosing the systemic inflammation associated with the patient's condition. **Positron Emission Tomography-Computed Tomography (PET-CT)** was performed to assess inflammatory activity and rule out malignancies or infections. The grayscale PET-CT scan (**Figure 6**) revealed hypermetabolic activity along the axial skeleton, particularly in the sacroiliac joints and vertebral column, consistent with active inflammation characteristic of ankylosing spondylitis. The colored PET-CT scan (**Figure 7**) demonstrated widespread metabolic activity, including significant tracer uptake in peripheral lymph nodes and the axial skeleton, indicating systemic inflammation. These findings corroborated the presence of hyperinflammatory states associated with adult-onset Still's disease, in addition to underlying ankylosing spondylitis.



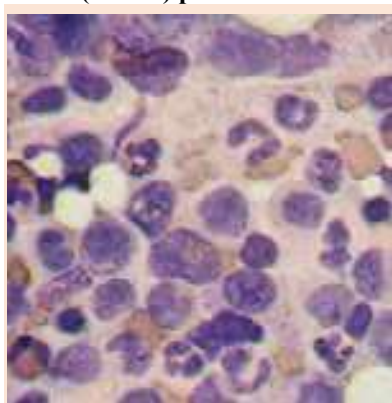
Pic 6: Grayscale PET-CT scan showing hypermetabolic activity along the sacroiliac joints and vertebral column, indicative of active inflammation in ankylosing spondylitis.



Pic 7: Colour PET-CT scan highlighting systemic inflammation with increased uptake in peripheral lymph nodes and the axial skeleton, supporting the diagnosis of a hyperinflammatory condition

Lymph Node Biopsy

The lymph node biopsy revealed **reactive hyperplasia**, characterized by a polymorphic population of cells including lymphocytes, plasma cells, and histiocytes. No evidence of malignancy, such as atypical lymphoid infiltrates or metastatic deposits, was observed. The findings were consistent with an inflammatory process, excluding conditions like lymphoma or other neoplastic causes. These results corroborated the systemic inflammatory state associated with **adult-onset Still's disease (AOSD)** picture 8.

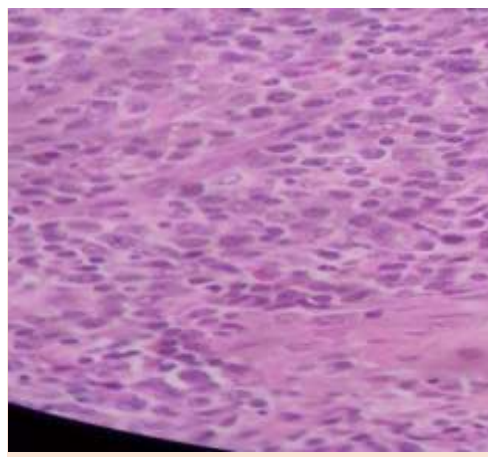


Pic 9 : Lymph node biopsy showing reactive hyperplasia with no evidence of malignancy.

Bone Marrow Biopsy

Picture 9, showing the bone marrow biopsy showed **normal cellularity**, with trilineage hematopoiesis preserved. Reactive changes were

evident, including an increased proportion of granulocytes, consistent with systemic inflammation. No morphological evidence of malignancy, such as abnormal megakaryocytes or blast infiltration, was identified. Furthermore, there were no findings indicative of macrophage activation syndrome (MAS), such as hemophagocytosis. These biopsy results helped to confirm the absence of hematological malignancies or other bone marrow disorders as potential causes of the patient's systemic symptoms.



Pic 9 : Bone marrow biopsy displaying preserved cellular architecture and reactive changes, with no signs of malignancy or macrophage activation syndrome (MAS).

Diagnostic Relevance

The combined findings of the lymph node and bone marrow biopsies played a crucial role in ruling out malignancy and supporting the diagnosis of AOSD. Together with imaging and laboratory results, these histopathological investigations established the hyperinflammatory nature of the condition while excluding other differential diagnoses, including lymphoma, leukemia, and macrophage activation syndrome.

Treatment Course

The patient's treatment was modified following the diagnosis of adult-onset Still's disease (AOSD), established using Fautrel and Yamaguchi criteria. NSAIDs were discontinued, and corticosteroids (prednisone 1 mg/kg/day) were initiated. This intervention resulted in rapid clinical improvement. Over time, corticosteroids were gradually tapered, and the patient was transitioned to disease-modifying antirheumatic drugs (DMARDs) for long-term disease control.



Follow-Up and Outcomes

The patient achieved sustained remission with no recurrence of fever or inflammatory symptoms. Routine follow-up assessments, including laboratory evaluations and imaging, confirmed the resolution of systemic inflammation. The patient continues on DMARD therapy with regular monitoring to ensure long-term disease management. This case underscores the diagnostic and therapeutic challenges associated with the coexistence of AS and AOSD, particularly in the context of PUO. Early recognition and tailored treatment were pivotal in achieving favorable outcomes.

III. DISCUSSION

Ankylosing spondylitis (AS) and adult-onset Still's disease (AOSD) are two distinct yet occasionally overlapping inflammatory disorders, each with unique clinical features and pathophysiological mechanisms. AS is primarily a chronic inflammatory condition affecting the axial skeleton, characterized by symptoms such as back pain, stiffness, and sacroiliitis. AOSD, on the other hand, is a systemic autoinflammatory disorder presenting with high spiking fevers, evanescent rash, and polyarthritis. The coexistence of these two conditions is extremely rare and presents a diagnostic challenge due to overlapping inflammatory markers and clinical features. This case provides an opportunity to explore the complexities of managing a patient exhibiting both diseases(4,5).

Comparison with Literature

Reports of simultaneous AS and AOSD in medical literature are limited, reflecting the rarity of this combination. Akkoc et al. (2008) presented a series of cases in which three patients with AS and one with axial spondyloarthritis also met the diagnostic criteria for AOSD. These patients exhibited a combination of symptoms such as inflammatory back pain, fever, rash, and arthritis. The clinical overlap observed in this case is consistent with their findings, particularly the presence of high-grade fever and systemic inflammatory markers. Another case, reported by Niasse et al. (2021), involved a Senegalese patient with AS who later developed AOSD. This case also highlighted the importance of distinguishing AOSD from other causes of systemic inflammation in patients with AS. While rare, these reported cases emphasize the need for heightened awareness among clinicians when patients with AS present

with systemic symptoms such as fever and rash, which are not typically associated with AS alone.

This case stands out due to its thorough diagnostic approach, which included the use of PET-CT to identify metabolically active lymphadenopathy and biopsy confirmation to rule out malignancy. Such meticulous evaluation adds to the existing literature, demonstrating the importance of combining clinical acumen with advanced diagnostic tools(6,7,8).

Shared Pathophysiology

The coexistence of AS and AOSD may be explained by shared inflammatory pathways involving cytokines and innate immune dysregulation. AS is mediated primarily by tumor necrosis factor-alpha (TNF- α) and interleukin-17 (IL-17), which contribute to chronic inflammation and the characteristic pathological bone formation. AOSD, however, is driven by cytokines such as interleukin-1 (IL-1), interleukin-6 (IL-6), and interleukin-18 (IL-18), leading to systemic manifestations such as fever and rash.

Despite these differences, both conditions are categorized as polygenic autoinflammatory disorders, suggesting potential commonalities in their immune mechanisms. For instance, excessive activation of the innate immune system, particularly through the IL-1 pathway, has been implicated in both diseases. In AOSD, IL-1 plays a central role in the autoinflammatory cascade, while in AS, TNF- α and IL-17 are predominant but are not exclusive to the condition. The interplay between these cytokines might explain the occasional coexistence of AS and AOSD in certain individuals. Further research is warranted to elucidate these mechanisms and explore potential genetic predispositions or environmental triggers(9).

Diagnostic Challenges

Diagnosing AOSD in a patient with preexisting AS is inherently challenging due to significant clinical and laboratory overlaps. Both conditions can present with systemic inflammation, joint involvement, and elevated markers such as CRP, ESR, and ferritin. This overlap can obscure the diagnosis of AOSD, particularly when classic features like evanescent rash are transient or absent.

In this case, the patient presented with PUO, polyarthritis, and hyperinflammatory markers, including an ESR of 82 mm/hr, CRP of 322 mg/L, and hyperferritinemia exceeding 10,000 ng/mL. These findings necessitated a comprehensive diagnostic workup to exclude other causes of systemic inflammation. The negative



results for infectious markers (e.g., hepatitis, tuberculosis, HIV) and autoimmune tests (e.g., rheumatoid factor, antinuclear antibodies) were critical in narrowing the differential diagnosis.

Imaging studies, particularly PET-CT, provided valuable insights by revealing metabolically active lymphadenopathy. Biopsies of the lymph nodes and bone marrow further confirmed reactive hyperplasia, effectively ruling out malignancies such as lymphoma or macrophage activation syndrome (MAS). The final diagnosis of AOSD was established using Fautrel and Yamaguchi criteria, emphasizing the importance of these diagnostic tools in complex cases(10).

Implications for Clinical Practice

This case highlights the critical need for clinicians to consider AOSD in patients with AS who present with unexplained fever, rash, and systemic inflammation. The overlapping features of these conditions require a systematic approach to rule out infectious and malignant causes before attributing the symptoms to AOSD.

From a therapeutic perspective, this case underscores the importance of tailoring treatment strategies to address both diseases simultaneously. The initial treatment with NSAIDs for AS was insufficient to control the systemic inflammation associated with AOSD. The subsequent use of corticosteroids (prednisone at 1 mg/kg/day) proved effective in resolving the patient's symptoms, highlighting the role of immunosuppressive therapy in managing AOSD. Transitioning to disease-modifying antirheumatic drugs (DMARDs) for long-term control further demonstrates the importance of a stepwise approach to treatment.

The insights gained from this case may influence future diagnostic protocols and treatment guidelines. For example, the utility of PET-CT imaging and biopsy in ruling out malignancy and confirming reactive hyperplasia could be incorporated into diagnostic algorithms for similar cases. Additionally, the shared inflammatory pathways between AS and AOSD suggest that biologic therapies targeting cytokines such as IL-1, IL-6, and TNF- α may have a role in treating patients with overlapping features.

IV. CONCLUSION

The coexistence of AS and AOSD, though rare, is a clinically significant phenomenon that requires careful consideration in patients presenting with systemic inflammatory symptoms. This case illustrates the importance of a thorough diagnostic approach, including the exclusion of infections and malignancies, and highlights the role of targeted

immunosuppressive therapy in managing such complex cases. Further research into the shared pathophysiology of AS and AOSD may pave the way for more effective diagnostic tools and therapeutic strategies, ultimately improving outcomes for patients with overlapping inflammatory conditions.

Key Learning Points

1. **Consider Adult-Onset Still's Disease (AOSD) in Patients with Ankylosing Spondylitis (AS) and Unexplained Fever**

Clinicians should maintain a high index of suspicion for AOSD in patients with AS who present with systemic symptoms such as persistent fever, polyarthritis, and elevated inflammatory markers.

2. **Thorough Diagnostic Evaluation is Essential**

A systematic approach, including comprehensive infectious and immunological workups, imaging studies (e.g., PET-CT), and biopsies, is crucial to rule out infections, malignancies, and other inflammatory conditions in patients with overlapping symptoms.

3. **Hyperferritinemia as a Diagnostic Clue**

Markedly elevated ferritin levels, often exceeding 10,000 ng/mL, can be a key indicator of AOSD and help distinguish it from other inflammatory or infectious conditions in complex cases.

4. **Tailored Treatment Strategies are Critical**

Management requires addressing both conditions simultaneously. While NSAIDs and biologics are effective for AS, systemic corticosteroids and DMARDs are essential for controlling the systemic inflammation of AOSD.

5. **Importance of Recognizing Shared Pathophysiology**

Understanding the shared inflammatory pathways involving cytokines like IL-1, IL-6, and TNF- α can guide the use of targeted therapies and improve outcomes in patients with overlapping AS and AOSD.

ABBREVIATIONS:

1. **AS:** Ankylosing Spondylitis
2. **AOSD:** Adult-Onset Still's Disease
3. **PUO:** Pyrexia of Unknown Origin
4. **PET-CT:** Positron Emission Tomography-Computed Tomography
5. **CRP:** C-Reactive Protein
6. **ESR:** Erythrocyte Sedimentation Rate
7. **IL:** Interleukin
8. **TNF- α :** Tumor Necrosis Factor-alpha



9. **DMARDs:** Disease-Modifying Antirheumatic Drugs
10. **NSAIDs:** Nonsteroidal Anti-Inflammatory Drugs
11. **MAS:** Macrophage Activation Syndrome
12. **HLA-B27:** Human Leukocyte Antigen B27

REFERENCE:

- [1]. Akkoc N, Sari I, Birlik M, Pay S, Binicier O, Akar S, et al. Ankylosing spondylitis and spondylarthropathy presenting with a clinical picture of adult onset Still's disease: Case series. *Rheumatology*. 2008;47(9):1436-1438. Available from: <https://academic.oup.com/rheumatology/article/47/9/1436/1791724>
- [2]. Niasse M, Ndao AC, Bouchrane R, Charifah S, Bah A, Diallo S. Ankylosing spondylitis associated with adult Still's disease: The first Senegalese case report. *Journal of Rare Diseases Research & Treatment*. 2021;6(2):1-4. Available from: <https://www.rarediseasesjournal.com/articles/ankylosing-spondylitis-associated-with-adult-stills-disease-the-first-senegalese-case-report.html>
- [3]. Jamilloux, Y., Gerfaud-Valentin, M., Henry, T., & Sève, P. (2014). Treatment of adult-onset Still's disease: A review. *Therapeutics and Clinical Risk Management*, 10, 455–462. <https://doi.org/10.2147/TCRM.S53109>
- [4]. Hirooka Y, Okuda S, Sugiyama M, Shiga T, Nozaki Y, Kinoshita K, et al. Case Report: A Rare Case of Elderly-Onset Adult-Onset Still's Disease in a Patient With Systemic Lupus Erythematosus. *Frontiers in Immunology*. 2022;13:822169. Available from: <https://www.frontiersin.org/articles/10.3389/fimmu.2022.822169/full>
- [5]. Zaber K, Fareed E. Adult Onset Still's Disease (AOSD) - A Case Report. *Bahrain Medical Bulletin*. 2002;24(3). Available from: <https://www.bjmrp.org/content/adult-onset-stills-disease-case-report>
- [6]. Cawkwell L, Fraser A. Ankylosing spondylitis: current approaches to management. *Prescriber*. 2006;19 September: 15-23. Available from: <https://wchh.onlinelibrary.wiley.com/doi/pdf/10.1002/psb.419>
- [7]. Mayo Clinic Staff. Ankylosing spondylitis - Symptoms & causes. Mayo Clinic. 2023. Available from: <https://www.mayoclinic.org/diseases-conditions/ankylosing-spondylitis/symptoms-causes/syc-20354808>
- [8]. Barhum L. What Are the Early Signs of Ankylosing Spondylitis? *Verywell Health*. 2024. Available from: <https://www.verywellhealth.com/early-signs-of-ankylosing-spondylitis-5272183>
- [9]. Mayo Clinic Staff. Ankylosing spondylitis - Diagnosis & treatment. Mayo Clinic. 2023. Available from: <https://www.mayoclinic.org/diseases-conditions/ankylosing-spondylitis/diagnosis-treatment/drc-20354813>
- [10]. The Sun. 'World's most folded man' finally stands up straight after 28 years thanks to life-changing surgery. *The Sun*. 2024. Available from: <https://www.the-sun.com/health/11228440/folded-man-ankylosing-spondylitis-surgery>