



## Spectrum of Thyroid Swellings and Disorders: A Hospital Based Study in Manipur

<sup>1</sup>Ranjita Achom, <sup>2</sup> Yengkhom Sanatomba Singh, <sup>3</sup> Vishal Salam, <sup>4</sup> Thokchom Amata Leima, <sup>5</sup> Yumnam Ramesh, <sup>6</sup> L. Sushila

<sup>1,2</sup> Associate Professor, <sup>3,4,5</sup> PGT, <sup>6</sup> Professor and HOD

<sup>1,2,3,4,5</sup>, Department of Surgery, <sup>6</sup> Department of Pathology Jawaharlal Nehru Institute of Medical Sciences (JNIMS) Imphal.

Submitted: 15-12-2021

Revised: 28-12-2021

Accepted: 31-12-2021

**ABSTRACT:** Diseases of the thyroid gland is a common clinical problem having a prevalence of (4-7 %) in the general population. Thyroid is an endocrine gland located in front of the neck and swelling of the gland can occur due to various disease condition. The aim of this paper is to study the spectrum of thyroid swellings and disorders among the patients attending the general Surgery department JNIMS for two years from April 2019 to march 2021. Altogether 56 patients were included in the study. 40 were females and 16 were males. Maximum cases were seen between (4-6)<sup>th</sup> decade of life. Out of 56 cases, majority were benign ie, 30 cases comprising of simple colloid goitre. Remaining 22 cases were malignant, all of which were papillary thyroid carcinomas. 2 cases each of thyroiditis and Hurthle cell adenoma were also found among the benign lesion. So, diseases of the thyroid gland is found more commonly in female, middle aged group and most of the swellings are of benign origin. And among the malignancy, papillary carcinoma is the commonest one.

**KEYWORDS:** Goitre, Thyroiditis, Colloid, Papillary, FNAC, HPE.

### I. INTRODUCTION :

Thyroid is an endocrine gland situated in front of the neck in close proximity to the thyroid cartilage. The word thyroid is derived from the Greek "thyros" meaning "shield" because it was originally considered to protect the larynx [1]. Diseases of the thyroid gland are one of the commonest endocrine disorders in India as well as in the world. A recently released report [2] shows that 300 million people in the world are suffering

from this endocrine problem and 42 million of these diseased are residing in India [3]. It is postulated that the incidence of thyroid nodule increases with age, in women, in people with iodine deficiency, and after radiation exposure. A report suggests a prevalence of (2-6)% with palpation, (19-35)% with ultrasound, and (8-65)% in autopsy data [4] while a prevalence of (4-7)% has been estimated in another [5]. The prevalence of goitre is different according to the geographical region, age and sex [6].

The spectrum of thyroid disorders ranges from underactive hypo to overactive hyperthyroidism, simple to toxic nodules, benign to malignant lesions. Almost one third of the world's population live in areas of iodine deficiency [7]. Even though it affects the entire population, most cases are reported from South-East Asia, Latin America and Central Africa [8].

### II. MATERIALS AND METHODS :

It is a prospective study of all the patients presenting with thyroid swelling in the Department of Surgery at Jawaharlal Nehru Institute of Medical Sciences, JNIMS Porompat for a period of two years from April 2019 to march 2021.

### III. RESULTS:

A total of 56 patients with thyroid swelling were taken for the study. The age ranges from (10-70) years. Maximum cases are seen in the age group (51-60) years followed by (31-40) years in female and (41-50) years in male, as shown in table (1) & fig. (1)

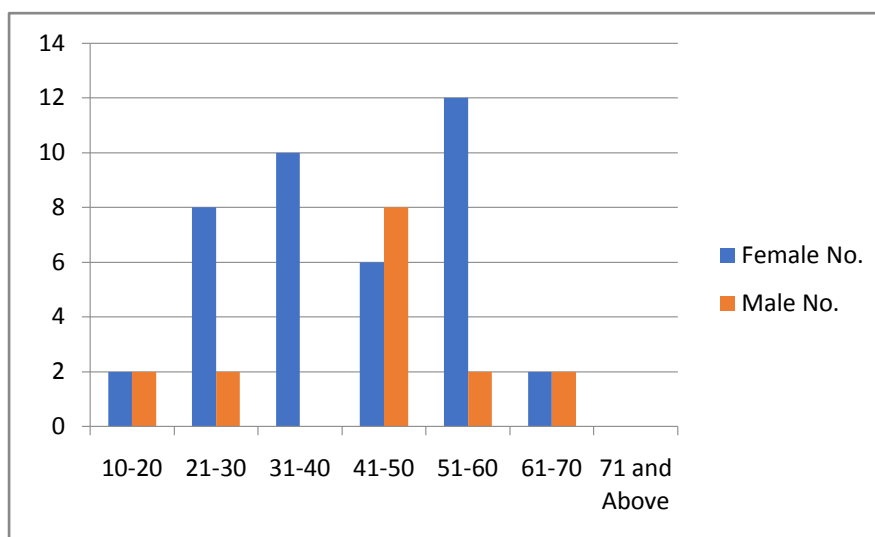
TABLE 1: Age and Sex distribution:

AGE IN YEARS	NO. OF FEMALE	NO. OF MALE
10-20	2	2
21-30	8	2
31-40	10	0



41-50	6	8
51-60	12	2
61-70	2	2
71 and Above	0	
TOTAL	40(71.4%)	16(28.57%)

Fig.1 Age and Sex distribution:



Majority of the patients were female accounting for 40 cases ( 71 % ) with male to female ratio of 2 : 5 . All the patients were euthyroid except “ 1 ” having hypothyroidism. All the patients presented with swelling in front of the neck within ( 1 – 10 ) years of onset of swelling. Majority of the patients had solitary nodule followed by multinodular swellings.

Pre-operative FNAC of the 56 cases had shown benign lesion in 34 cases ( 60.7 % ) and

malignancy in 22 cases ( 39.2 % ) . Out of 34 benign, nodular and multinodular colloid goitre accounts for 30 cases ( 88.2 % ), 2 cases ( 5.8 % ) constitute thyroiditis and 2 cases ( 5.8 % ) were hurthle cell adenoma. Majority of the benign cases ie, 22 ( 64.7% ) were female and male constitute 12 cases ( 35.3 % ) . Among the 22 malignant cases, majority ie, 18 ( 81.8 % ) were female and remaining 4 cases ( 22.2 % ) were male. And all the malignant cases were papillary carcinoma and no other variant detected as shown in table 2.

TABLE 2: FNAC findings of the Thyroid swellings:

FNAC	BENIGN -34 MALIGNANCY – 22 SUSPICIOUS – 0 INCONCLUSIVE – 0 FOLLICULAR NEOPLASM - 0
TOTAL	56 CASES

Hemithyroidectomy was done in 28 cases ( 50 % ), Sub total thyroidectomy in 6 ( 10.7 % ) and total thyroidectomy in 22 cases ( 39.2 % ) .

On histopathological examination, 34 cases were benign and 22 cases were malignant and the ratio between benign and malignant lesion was

1.54 : 1. In male, the ratio was 3:1. Out of 34 benign cases, 24 solitary nodular goitre, 6 multinodular goitre, 2 thyroiditis and 2 hurthle cell adenoma were encountered as shown in table ( 3 ). And among the malignant cases, all the 22 cases were papillary thyroid carcinoma only.



**TABLE 3:** Histopathological ( HPE ) Findings:

BENIGN		MALIGNANCY	
i)	Benign nodular colloid goitre-30	i)	Papillary Carcinoma – 22
ii)	Thyroiditis -2	ii)	Follicular Carcinoma – 0
iii)	Hurthle Cell adenoma -2	iii)	Medullary Carcinoma –0
		iv)	Anaplastic Carcinoma –0
			Total –22
Total --34			

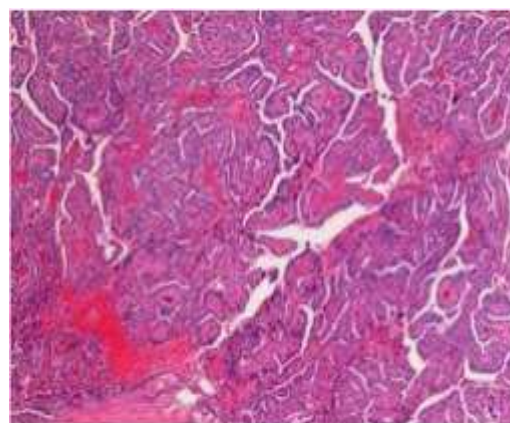
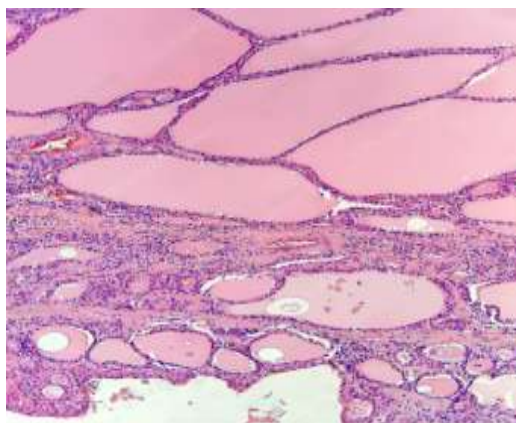


Fig : HPE Picture of Benign Colloid Goitre      Fig: HPE Picture of Papillary Carcinoma of Thyroid

#### IV.DISCUSSION:

India has the world's largest goitre belt in the sub-Himalayan region [9] and about 12 % of adult population in India have a palpable goitre [10] . Manipur is one of the goitre endemic states of north east India. Our report suggests that despite the promotion of iodization, the prevalence of goitre still continue to be a public health problem [11]. In our study, simple colloid goitre was the highest cause of thyroid swelling (53.57 %) followed by malignancy, thyroiditis and adenoma.

Little information is available regarding the prevalence of thyroiditis. In a study on school girls in India , 7.5 % of patients with goitre undergoing FNAC had evidence of juvenile autoimmune thyroiditis including both Hashimoto's thyroiditis and focal lymphocytic thyroiditis [12]. In the present study, thyroiditis was found in 2 cases ( 5.8% ).

In most of the studies on thyroid swelling, majority of the cases are of benign origin. In our study also, majority ie ,34 cases (60.7% ) were benign and 22 cases (39.2%) were malignant. A study from Italy shows the incidence of benign thyroid swelling to be 68.75% and malignancy in 31.25% of the patients and this findings are comparable to our study. Most common malignancy detected was papillary carcinoma [13]

which was true in our study also with papillary carcinoma comprising all the 22 malignant cases.

Study by Rahman et al., shows the occurrence of malignancy to be only 8.2% out of all the cases of thyroid swellings. In their study, follicular carcinoma was commonest [14]. Refeidi et al., demonstrated that the commonest thyroid cancer to be papillary carcinoma, followed by follicular carcinoma while lymphoma ranked third with only 1.1% incidence [15]. Similar finding has been reported by Ht We et al. Papillary carcinoma was commonest in their series , while anaplastic carcinoma has the lowest incidence [16].

In Africa, the documented prevalence rates of papillary carcinoma ranges from ( 6.7- 72.1) % , follicular ( 4.9- 68) % , anaplastic ( 5- 21.4) % and medullary ( 2.6- 13.8 ) % . There is a changing trend towards more frequent occurrence of papillary carcinoma compared to follicular carcinoma and this may be attributable to widespread iodization programmes.[17]. Data from the Indian council of Medical Research also established that the commonest cancer type was papillary, followed by follicular cancer [1]. It is well established that papillary carcinoma is the most common malignant neoplasm of the thyroid gland, representing about 80% of all thyroid cancers [18].



### V.CONCLUSION:

Thyroid swelling is a common lesion seen among the patients attending surgery OPD JNIMS. Majority of the swellings were seen in female population ( 71.1% ) in 4<sup>th</sup> to 6<sup>th</sup> decades of life. Incidence is lower in extreme of age and male gender. Maximum cases were benign 34 ( 60.7 % ) out of 56 patients , comprising of solitary and multinodular colloid goitre ( 88.2 % ). Remaining 22 cases were malignant and papillary thyroid carcinoma was the commonest malignancy we encountered.

### REFERENCES :

- [1]. Medvei VC. A history of endocrinology. In: Kovacs K, Asa S, editors. Functional Endocrinology. England: Blackwell Science. 1998. P.1.
- [2]. Canaris GJ, Manowitz NR, Mayor G, Ridgway EC. The Colorado thyroid disease prevalence study. Arch Int Med 2000; 160 : 526-34.
- [3]. Kochupillai N. Clinical endocrinology in India. Curr Sci 2000; 79: 1061-7.
- [4]. Dean DS, Gharib H. Epidemiology of thyroid nodules. Best Pract Res Clin Endocrinol Metab 2008; 22: 901-11.
- [5]. Ezzal S, Sarti DA, Cain DR, Braunstein GD. Thyroid incidentalomas: Prevalence by palpation and ultrasonography. Arch Intern Med 1994; 154: 1338-40.
- [6]. Lamfon HA . Thyroid Disorders in Makkah, Saudi Arabia. Ozean J Appl Sci 2008; 1: 55-8.[7] Zimmerman MB. Iodine deficiency. Endocr Rev 2009; 30: 376-408.
- [7]. Vanderpump MP. The epidemiology of thyroid diseases. In: Braverman LE, Utiger RD, editors. Wesner and Ingbar's the Thyroid: A Fundamental and Clinical Text. 9<sup>th</sup> ed. Philadelphia: JB Lippincott-Raven; 2005.p.[9] Handa U, Garg S, Mohan H, Nagarkar N. Role of fine needle aspiration cytology in diagnosis and management of thyroid lesions : A study on 434 patients, J Cytol 2008; 25: 13-7.
- [8]. Menon UV, Sundaram KR, Unnikrishnan AG, Jayakumar RV, Nair V, Kumar H. High prevalence of undetected thyroid disorders in an iodine sufficient adult south Indian population. J Indian Med Assoc. 2009; 107: 72-7.
- [9]. Marwaha RK, Tandon N, Gupta N, Karak AK, Verma K, Kochupillai N. Residual goitre in the postiodization phase: Iodine status, thiocyanate exposure and autoimmunity. Clin Endocrinol ( Oxf) 2003; 59: 672-81.
- [10]. Marwaha RK, Tandon N, Karak AK, Gupta N, Verma K, Kochupillai N. Hashimoto's thyroiditis: Countrywide screening of goitrous healthy young girls in postiodization phase in India. J Clin Endocrinol Metab 2000; 85: 3798-802.
- [11]. Pezzolla A, Lattarulo S, Milella M, Barile G, Pascazio B, Ciampolillo A, et al. Incidental carcinoma in thyroid pathology: Our experience and review of the literature. Ann Ital Chir 2010; 81: 165-9.
- [12]. Rahman GA, Abdulkadir AY, Braimoh KT, Inikori AR. Thyroid cancers amongst goitre population in a Nigerian tertiary hospital : Surgical and radiographic perspective. Niger J Med 2010; 19: 432-5.
- [13]. Refeidi AA, Al-Shehri GY, Al-Ahmary AM, Tahtouh MI, Alsareii SA, Al-Ghamdi AG, et al. Patterns of thyroid cancer in south western Saudi Arabia. Saudi Med J 2010 ; 31: 1238- 41.
- [14]. Htwe TT, Hamdi MM, Swethadri GK, Wong JO, Soe MM, Abdullah MS. Incidence of thyroid malignancy among goitrous thyroid lesions from the Sarawak General Hospital 2000-2004. Singapore Med J 2009; 50: 724-8.
- [15]. Ogbera AO, Kuku SF. Epidemiology of thyroid diseases in Africa. Indian J Endocrinol Metab. 2011; 15 Suppl 2: S 82-8.
- [16]. Scheuller MC, Eisele DW. Malignant thyroid neoplasm. Current diagnosis and treatment Otolaryngology Head and Neck Surgery. 2<sup>nd</sup>ed. New York,US: McGraw Hill: 2008.