



Spindle Cell Lesion

¹Ajay. D, ²AjayKumar.V, ³Shradha. R, Dr. Nila, Dr.S.Marytresa Jeyapriya, Dr. M. Sathish kumar

(UG)Karpaga Vinayaga Institute Of Dental Science, Chengalpattu, India

(UG) Karpaga Vinayaga Institute Of Dental Science, Chengalpattu, India

(UG) Karpaga Vinayaga Institute Of Dental Science, Chengalpattu, India

(PG) Department of Oral maxillofacial pathology, Karapaga Vinayaga institute dental science

(Reader), Department of Oral maxillofacial pathology and oral Microbiology, Karapaga Vinayaga institution of dental science, Chengalpattu, India

(Head of the Department), Department of Oral maxillofacial pathology and o Microbiology, Karapaga Vinayaga institution of dental science, Chengalpattu, India

Date of Submission: 10-12-2023

Date of Acceptance: 20-12-2023

ABSTRACT:

Spindle cell lesions are defined as neoplasms that consist of spindle shaped cells in histopathology. In the oral cavity, the origin of spindle cell lesion may h traced by epithelial, mesenchymal & odontogenic components. This article aims to review the spindle cell lesions of oral cavity with emphasis of Radiographic & histologic features.

KEYWORDS:spindle cell, lesion, neoplasms, oral cavity

I. INTRODUCTION:

Spindle cell tumors are a diverse group of tumors characterized by elongated spindle-shaped cells that make up the majority of their histological makeup. These tumors include a large number of benign and malignant entities originating from various tissues and organ systems throughout the body. Their diagnostic and therapeutic challenges have made them the subject of considerable interest and research in the medical community. The purpose of this article is to provide a comprehensive overview of spindle cell tumors and to provide a comprehensive overview of their pathogenesis, clinical presentation, diagnostic methods, and treatment options. Spindle cell tumors include a variety of diseases, from dermatofibrosarcoma protuberance to gastrointestinal stromal tumors, each with unique characteristics and clinical implications.[1][2-19]

ETIOLOGY:

As part of the body's natural response to soft tissue injury, spindle cells in the damaged tissue begin to divide to promote healing. Normally, after the damaged area is repaired, the spindle cells stop multiplying. But sometimes cells can continue to divide uncontrollably for reasons that are not fully understood. The extra cells can then accumulate, bind together and form a spindle

cell sarcoma. Some people are genetically predisposed to developing spindle cell sarcoma. Other risk factors include:

Paget's disease of bone - A chronic bone disease, Paget's disease disrupts bone remodeling and causes bone weakening and deformities. Previous radiation therapy to the bone - A spindle cell sarcoma can develop several years after the bone has been exposed to radiation therapy. Fibrous dysplasia - As part of the bone regeneration process, mature bone tissue is replaced by new immature bone tissue. Bone infarction - Due to poor blood circulation, bone tissue loses the oxygen it needs and dies. Osteomyelitis - Osteomyelitis, often the result of injury, is an inflammation of the bone that causes inflammation and swelling.[20][21-25]

CLASSIFICATION:

1.NEURAL TUMORS

NEURILEMMOMA

Neurolemmoma is a fairly common tumor that originates from Schwann cells, also called schwannoma. Neurites are not a component of the tumor as in neurofibroma, but can be found on the surface of the tumor. Tissue culture studies by Murray and Stout, who grew this tumor in vitro, confirm the idea of Schwann cells. as a source of origin.[26]

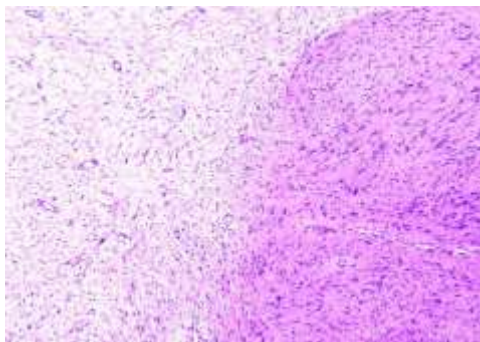
RADIOGRAPHIC FEATURES:

MRI is the test of choice to confirm the presence of a neoplasm. Typical features of schwannoma on MR imaging are slightly hyperintense or isointense signal relative to skeletal muscle on T1-weighted images and increased, slightly heterogeneous signal intensity on T2-weighted images. In Fluid 18 sensitive sequences, the signal intensity may be high at the periphery of the lesions and low or moderate in the center. [26]



HISTOLOGIC FEATURES:

The microscopic picture of a neurilema is typical and can rarely be confused with other lesions. They have a capsule consisting of epineurium and residual nerve fibers. Traditionally, the tumor is described as consisting of two tissue types: Antoni type A and Antoni type B. Antoni type A tissue consists of cells with elongated or spindle-shaped nuclei aligned to form a characteristic palisade pattern, while the intercellular fibers lie parallel between the nuclear rows. These filaments give the impression on some levels that they are formed in eddies or eddies. [26]



2.MYOFIBROBLASTIC TUMORS: MYOFIBROMA

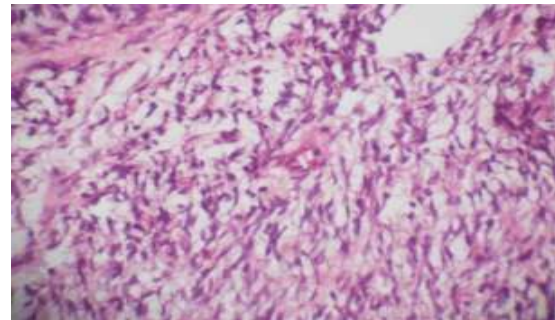
Myofibroma (unifocal) and myofibromatosis (multifocal) are rare spindle cell tumors composed of myofibroblasts that usually present as a painless mass that may show rapid enlargement and ulceration. Again, no phenomenon leading to inadequate preoperative diagnosis could be observed in our case.[27][28-30]

RADIOGRAPHIC FEATURES:

Radiological features of mandibular myofibroma showed a radiolucent lesion that was often monocular (70%) and well circumscribed (67%). Cortical enlargement and/or perforation was sometimes present. [27][28-30]

HISTOLOGICAL FEATURES:

Histologically, intertwining bundles of spindle cells with narrow and obtuse nuclei and eosinophilic cytoplasm suggest smooth muscle and fibroblastic differentiation. A biphasic or zonal pattern is usually seen, consisting of nodular connective tissue of spindle cells surrounding cellular groups of undifferentiated cells with small, round basophilic nuclei. [27][28-30]



3. DESMOPLAST FIBROMA:

Desmoplastic fibroma is a rare, benign, and locally aggressive but nonmetastatic tumor originating in connective tissue. Like other intraosseous connective tissue lesions, it is most often occurs in the metaphysis of long bones. Desmoplastic of the jaw was first reported by Griffith and Irby in 1965. It usually resembles a soft tissue desmoid tumor in histological features.[31][32-35]

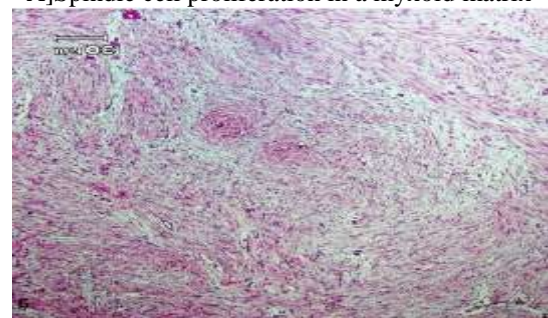
RADIOGRAPHIC FEATURES:

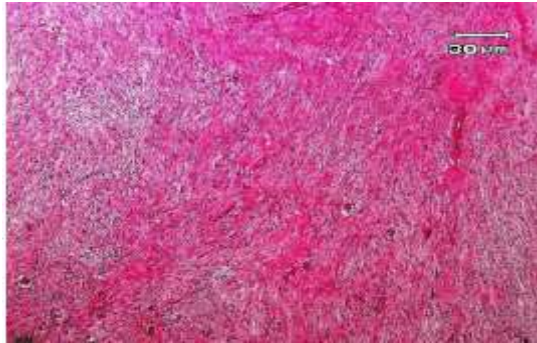Radiographs of Desmoplastic are nonspecific. It can be monocular or multifocal with well-defined or ill-defined borders or irregular radiolucencies. It usually has a lobulated appearance similar to soap bubbles and thus can mimic some other jaw lesions such as ameloblastoma, myxoma, aneurysmal bone cyst, central hemangioma, and eosinophilic granuloma.[31][32-35]

HISTOLOGICAL FEATURES:

Pathognomonic histological features of DF include the presence of mature connective tissue and spindle-shaped fibroblasts separated by abundant collagen fibers. Due to its pathognomonic histological features, it is important to distinguish it from other benign spindle cell tumors such as neophytic fibroma, nodular fasciitis, myofibroma, odontogenic fibroma, as well as fibrous dysplasia and low-grade fibrosarcoma.[31][32-35]

A]Spindle cell proliferation in a myxoid matrix





B] Fibrotic matrix

4. MUSCLE TUMORS:

Vascular LEIOMYOMA:

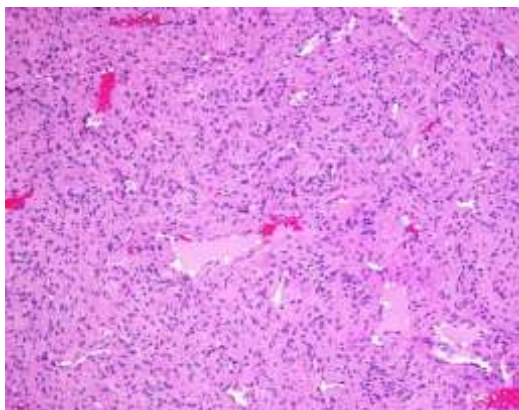
Vascular leiomyoma or angioleiomyoma is a benign smooth muscle tumor that arises from the central part of the vascular tunic.⁶ Other presumed sites are erectile fistula, sweat glands and vascular tunic centers. They are usually less than 2 cm in diameter. These lesions are found in the dermis, subcutaneous fat or deep fascia. [36][37-41]

RADIOGRAPHIC FEATURES:

X-ray findings are usually normal, but rarely dystrophic calcifications may be seen. MR imaging is very useful for differentiating between benign and malignant soft tissue tumors and delineating anatomical boundaries and vascularity before surgery. [36][37-41]

HISTOLOGICAL FEATURES:

Histopathological identification using staining methods such as Masson's trichrome, hematoxylin-eosin-Alcian blue, van Gieson, and periodic acid-Schiff (PAS) can be very valuable in the diagnosis of leiomyoma. Immunohistochemical staining for vimentin, desmin, and smooth muscle actin also completes the histopathologic diagnosis of leiomyoma.



5. VASCULAR TUMOUR IN SPINDLE CELL HEMANGIOMA:

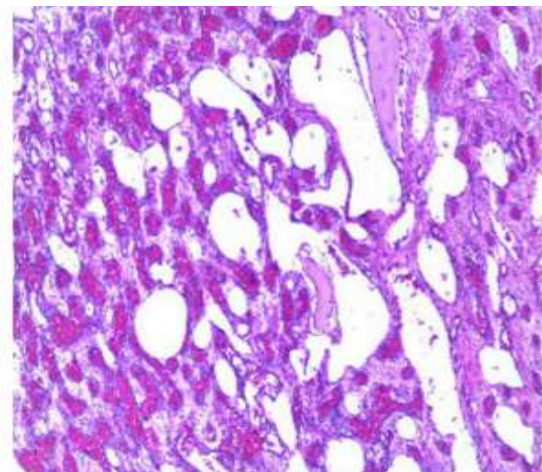
Spindle cell hemangioma is a rare vascular lesion first described in 1986. This entity was originally thought to be a tumor with limited metastatic potential, but is now considered a benign tumor characterized by a combination of cavernous spaces and solid areas of spindle cells and epithelial cells. vascular lesion rather than low-grade angiosarcoma. Although the course is benign, the lesion tends to recur.[42][43-45]

RADIOGRAPHIC FEATURES:

The lesion may appear aggressive with a bony and soft tissue component. The lesions are typically hypointense on T1-weighted imaging, heterogeneous on T2-weighted imaging, and show enhancement on contrast sequences. Imaging differential diagnosis of frontal spindle cell hemangioma includes eosinophilic granuloma and metastatic tumors. [42][43-45]

HISTOLOGICAL FEATURES:

spindle cell hemangioma is characterized by cavernous vessels and fusiform areas. The cells are dark pink in HE is staining, with plump nuclei and clear nucleoli. Immunohistochemical CD31 (and factor VIII or CD34) were positive.



6.EPITHELIAL TUMORS

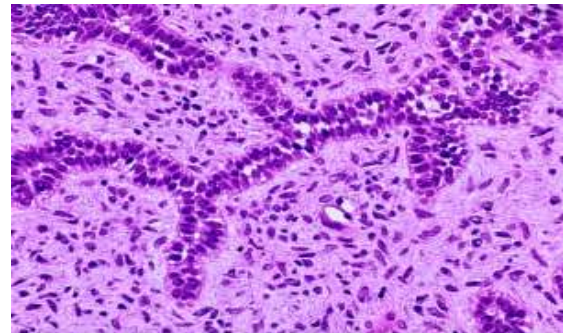
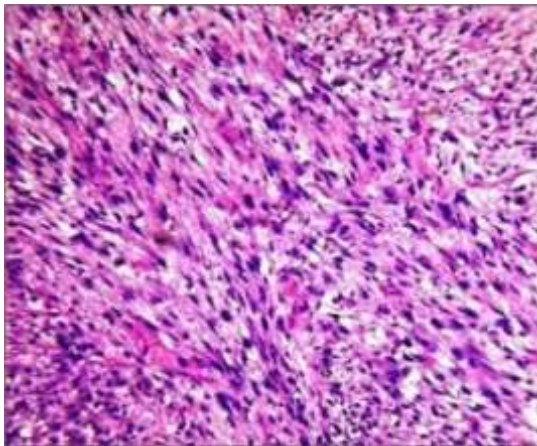
SPINDLE CELL CARCINOMA

Spindle cell squamous carcinoma (SpCC) is an exceedingly rare variant of squamous cell carcinoma (SCC) with unique clinicopathological characteristics. SpCC is often referred to as a biphasic malignant neoplasm, describing both an epithelial SCC component and a mesenchymal sarcomatoid spindle cell component. [46][47-56]



HISTOLOGIC FEATURES:

The histological features of SpCC could present as a monophasic spindle, pleomorphic, or more commonly as a biphasic tumor with epithelial changes including dysplasia to invasive carcinoma, admixed with zones of spindle cells. The multiplicity of nomenclature indicates the complexity of SpCC histogenesis. [46][47-56]



DIAGNOSIS

IMAGING:

X-rays can show tumors or other abnormalities in your bones. A chest X-ray can show if the cancer has spread to the lungs. Metastatic spindle cell sarcoma often spreads to the lungs first.[20][21-25]

BLOOD tests:

There is no specific blood test that detects spindle cell sarcoma. However, blood tests provide important information about your health that your provider needs to know. In general, blood tests provide information about:

Blood cells. Organ function. Enzyme levels (enzymes are chemicals that allow organs to carry out important processes).[20][21-25]

BIOPSY:

A biopsy is the best way to know for sure if a tumor is cancerous. It is also the only way to know the type of cancer and its stage. During biopsy, a healthcare provider removes a tissue sample from the tumor and sends it to a lab to test the cells. Most people with spindle cell sarcoma will have a needle biopsy. Healthcare providers numb the tissue around the tumor and then use a small, hollow needle to remove the sample.[20][21-25]

TREATMENT:

SURGERY:

The goal of surgery is to remove the tumor while preserving as much bone as possible. Removing all signs of cancer from the primary tumor and secondary tumors can cure the cancer. However, it is much more difficult to completely remove cancer when it has spread beyond the primary tumor.[20][21-25]

Chemotherapy:

Chemotherapy uses drugs throughout the body to kill cancer cells. Before surgery, you may need chemotherapy to shrink the tumor so it is easier to remove. Or you may need chemotherapy after surgery to kill any remaining cancer cells.

7. ODONTOGENIC TUMORS

AMELOBLASTIC FIBROMA:

Ameloblastic fibromas are one of the few types of benign odontogenic tumors in which the proliferative odontogenic epithelium is embedded in cellular ectomenchymal tissue similar to a dental papilla.[57][58-66]

RADIOGRAPHIC FEATURES:

Ameloblastic fibroids are seen as well-defined uni- or multilocular radiolucencies with sclerosing radiolucent borders. Unilocular lesions are asymptomatic, while multilocular cases often present as jaw swelling. Most ameloblastic fibroids are discovered incidentally during a routine examination. [57][58-66]

HISTOLOGICAL FEATURES:

An ameloblastic fibroma consists of chains and islets of odontogenic epithelium in a loose and primitive connective tissue stroma similar to a dental papilla. Islands similar to the follicular stage of the developing mica organ can be observed. [57] [58-66]



Chemotherapy is also one of the forms of palliative treatment. [20][21-25]

Radiotherapy:

External beam radiation therapy (EBRT) uses a machine that directs X-rays at the tumor and kills the cancer cells. If you are not a candidate for surgery, you may need radiation to destroy the tumor. Sometimes the surgeon cannot access the tumor through surgery.. [20][21-25]

II. CONCLUSION:

In this article, classification, clinical features, radiographic features, histological features, diagnosis & Treatment has been discussed.

REFERENCE

- [1]. Feng L, Cai D, Muhetaer A, Yang YL, Ren F, Yishake M, Zhang H, Fang Y, Wushou A. Spindle cell carcinoma: the general demographics, basic clinicopathologic characteristics, treatment, outcome and prognostic factors. *Oncotarget*. 2017 Jun 27;8(26):43228-43236. doi: 10.18632/oncotarget.18017. PMID: 28591732; PMCID: PMC5522141.
- [2]. Battifora H. Spindle cell carcinoma: ultrastructural evidence of squamous origin and collagen production by the tumor cells. *Cancer*. 1976; 37:2275-2282.
- [3]. Gupta R, Singh S, Hedau S, Nigam S, Das BC, Singh I, Mandal AK. Spindle cell carcinoma of head and neck: an immunohistochemical and molecular approach to its pathogenesis. *J Clin Pathol*. 2007; 60:472-475.
- [4]. Ung M, Rouquette I, Filleron T, Taillandy K, Brouchet L, Bennouna J, Delord JP, Milia J, Mazières J. Characteristics and clinical outcomes of sarcomatoid carcinoma of the lung. *Clin Lung Cancer*. 2016; 17:391-397.
- [5]. Malla M, Wang JF, Trepeta R, Feng A, Wang J. Sarcomatoid carcinoma of the urinary bladder. *Clin Genitourin Cancer*. 2016; 14:366-372.
- [6]. Chang NJ, Kao DS, Lee LY, Chang JW, Hou MM, Lam WL, Cheng MH. Sarcomatoid carcinoma in head and neck: a review of 30 years of experience—clinical outcomes and reconstructive results. *Ann Plast Surg*. 2013; 71:S1-S7.
- [7]. Lee AH. Recent developments in the histological diagnosis of spindle cell carcinoma, fibromatosis and phyllodes tumour of the breast. *Histopathology*. 2008; 52:45-57.
- [8]. Ellis GL, Corio RL. Spindle cell carcinoma of the oral cavity. A clinicopathologic assessment of fifty-nine cases. *Oral Surg Oral Med Oral Pathol*. 1980; 50:523-33.
- [9]. Olsen KD, Lewis JE, Suman VJ. Spindle cell carcinoma of the larynx and hypopharynx. *Otolaryngol Head Neck Surg*. 1997; 116:47-52.
- [10]. Viswanathan S, Rahman K, Pallavi S, Sachin J, Patil A, Chaturvedi P, D'Cruz A, Agarwal J, Kane S. Sarcomatoid (spindle cell) carcinoma of the head and neck mucosal region: a clinicopathologic review of 103 cases from a tertiary referral cancer centre. *Head Neck Pathol*. 2010; 4:265-275.
- [11]. Kim JH, Leeper RD. Treatment of anaplastic giant and spindle cell carcinoma of the thyroid gland with combination Adriamycin and radiation therapy. A new approach. *Cancer*. 1983; 52:954-957.
- [12]. Sneige N, Yaziji H, Mandavilli SR, Perez ER, Ordonez NG, Gown AM, Ayala A. Low-grade (fibromatosis-like) spindle cell carcinoma of the breast. *Am J Surg Pathol*. 2001; 25:1009-1016.
- [13]. Mainwaring MG, Poor C, Zander DS, Harman E. Complete remission of pulmonary spindle cell carcinoma after treatment with oral germanium sesquioxide. *Chest*. 2000; 117:591-593.
- [14]. Bigby SM, Eva LJ, Jones RW. Spindle cell carcinoma of the vulva: a series of 4 cases and review of the literature. *Int J GynecolPathol*. 2014; 33:203-212.
- [15]. Marrelli D, Morgagni P, De MG, Coniglio A, Marchet A, Saragoni L, Tiberio G, Roviello F. Prognostic value of the 7th AJCC/UICC TNM classification of noncardia gastric cancer: analysis of a large series from specialized Western centers. *Ann Surg*. 2012; 255:486-491.
- [16]. Bice TC, Tran V, Merkley MA, Newlands SD, van der Sloot PG, Wu S, Miller MC. Disease-specific survival with spindle cell carcinoma of the head and neck. *Otolaryngol Head Neck Surg*. 2015; 153:973-980.
- [17]. Gerry D, Fritsch VA, Lentsch EJ. Spindle cell carcinoma of the upper aerodigestive tract: an analysis of 341 cases with comparison to conventional squamous cell



- carcinoma. *Ann OtolRhinolLaryngol.* 2014; 123:576-583.
- [18]. Dubal PM, Marchiano E, Kam D, Dutta R, Kalyoussef E, Baredes S, Eloy JA. Laryngeal spindle cell carcinoma: a population-based analysis of incidence and survival. *Laryngoscope.* 2015; 125:2709-2714.
- [19]. Moten AS, Jayarajan SN, Willis AI. Spindle cell carcinoma
- [20]. Feng L, Cai D, Muhetaer A, Yang YL, Ren F, Yishake M, Zhang H, Fang Y, Wushou A. Spindle cell carcinoma: the general demographics, basic clinicopathologic characteristics, treatment, outcome and prognostic factors. *Oncotarget.* 2017 Jun 27;8(26):43228-43236. doi: 10.18632/oncotarget.18017. PMID: 28591732; PMCID: PMC5522141.
- [21]. Davis DD, Shah SJ, Kane SM. Fibrosarcoma of the breast: a comprehensive analysis. *Am J Surg.* 2016;211:716-721.
- [22]. Mangla A, Yadav U. Leiomyosarcoma (https://www.ncbi.nlm.nih.gov/books/NBK560759/). [Updated 2022 Jun 27]. In: StatPearls [Internet]. Treasure Island (FL): StatPearls Publishing; 2023 Jan-. Accessed 5/23/2023.
- [23]. Park SY, Lee MH, Jeon JY, Chung HW, Lee SH, Shin MJ. MRI Evaluation of Suspected Pathologic Fracture at the Extremities from Metastasis: Diagnostic Value of Added Diffusion-Weighted Imaging (https://www.ncbi.nlm.nih.gov/pmc/articles/PMC6470093/). *Korean J Radiol.* 2019;20(5):812-822. Accessed 5/23/2023.
- [24]. Robles-Tenorio A, Solis-Ledesma G. Undifferentiated Pleomorphic Sarcoma (https://www.ncbi.nlm.nih.gov/books/NBK570612/). [Updated 2022 Apr 14]. In: StatPearls [Internet]. Treasure Island (FL): StatPearls Publishing; 2023 Jan-. Accessed 5/23/2023.
- [25]. U.S. National Cancer Institute. Soft Tissue Sarcoma-Patient Version (https://www.cancer.gov/types/soft-tissue-sarcoma). Multiple pages reviewed. Accessed 5/23/2023.
- [26]. SHAFERS textbook of oral pathology 9th edition, Sivapathasundaram, 2020
- [27]. Venkatesh V, Kumar BP, Kumar KA, Mohan AP. Myofibroma-a rare entity with unique clinical presentation. *J Maxillofac Oral Surg.* 2015 Mar;14(Suppl 1):64-8. doi: 10.1007/s12663-011-0299-5. Epub 2011 Oct 18. PMID: 25838671; PMCID: PMC4379250.
- [28]. Kempson RL, Fletcher CDM, Evans HL, Hendrickson MR, Sibley RK (1998) Atlas of tumor pathology. Tumors of soft tissue. Armed Forces Institute of Pathology, Bethesda, pp 64–67.
- [29]. Foss RD, Ellis GL (2000) Myofibromas and myofibromatosis of the oral region: a clinicopathologic analysis of 79 cases. *Oral Surg Oral Med Oral Pathol Oral Radiol Endod* 89:57–65
- [30]. Desmoplastic fibroma of the jaw: A case report and review of literature Said-Al-Naief, Nasser et al. *Oral Surgery, Oral Medicine, Oral Pathology, Oral Radiology and Endodontics*, Volume 101, Issue 1, 82 - 94
- [31]. Neville BW, Damm DD, Allen CM, Bouquot J (2001) Oral & maxillofacial pathology. WB Saunders, Philadelphia, p 518
- [32]. Templeton K1, Glass N, Young SK. Desmoplastic fibroma of the mandible in a child: report of a case. *Oral Surg Oral Med Oral Pathol Oral Radiol Endod.* 1997; 84(6):620-3. (DOI:10.1016/S1079-2104(97)90362-0)
- [33]. Skinner HR, Vargas A, Solar A, et al. Desmoplastic Fibroma of the Mandible in a Pediatric Patient: A Case Report of Resection and Reconstruction With A Six Year Follow-Up. *J Oral Maxillofac Surg.* 2017; 75(7):1568.e1-1568.e10. (DOI:10.1016/j.joms.2017.03.003) (PMID)
- [34]. Bakaeen G1, Rajab LD. Desmoplastic fibroma of the mandible: report of a case. *Int J Paediatr Dent.* 1999; 9(2):117-21. (DOI:10.1046/j.1365-263x.1999.00115.x) (PMID)
- [35]. J.G. Griffith, W.B. Irby Desmoplastic fibroma: report of a rare tumor of the oral structures. *Oral Surg Oral Med Oral Pathol,* 1965, pp. 269-275 (DOI:10.1016/0030-4220(65)90201-X)
- [36]. Sayit E, Sayit AT, Zan E, Bakirtas M, Akpinar H, Gunbey HP. Vascular leiomyoma of an extremity: Report of two



- cases with MRI and histopathologic correlation. *J Clin Orthop Trauma*. 2014 Jun;5(2):110-4. doi: 10.1016/j.jcot.2014.04.001. Epub 2014 May 9. PMID: 25983482; PMCID: PMC4085364.
- [37]. Hwang JW, Ahn JM, Kang HS, Suh JS, Kim SM, Seo JW. Vascular leiomyoma of an extremity: MR imaging-pathology correlation. *AJR*. 1998;171:981e985.
- [38]. Boutayeb F, Ibrahimi AE, Chraibi F, Znati K. Leiomyoma in an index finger: report of case and review of literature. *Hand*. 2008;3(3):210e211.
- [39]. Yang WE, Hsueh S, Chen CH, Lee ZL, Chen WJ. Leiomyoma of the hand mimicking a pearl ganglion. *Chang Gung Med J*. 2004;27(2):134e137.
- [40]. Cigna E, Maruccia M, Malzone G, Malpassini F, Soda G, Drudi FM. A large vascular leiomyoma of the leg. *J Ultrasound*. 2012;15(2):121e123.
- [41]. Kulkarni AR, Haase SC, Chung KC. Leiomyoma of the hand. *Hand*. 2009;4(2):145e149.
- [42]. K.I. Tosios, I. Gouveris, A. Sklavounou, I.G. Koutlas, Spindle cell hemangioma (hemangioendothelioma) of the head and neck: case report of an unusual (or underdiagnosed) tumor, *Oral Surgery, Oral Medicine, Oral Pathology, Oral Radiology, and Endodontology*, Volume 105, Issue 2, 2008, Pages 216-221, ISSN 1079-2104
- [43]. Ding J, Hashimoto H, Imayama S, Tsuneyashi M, Enjoje M. Spindle cell hemangioendothelioma: probably a benign vascular lesion, not a low grade angiosarcoma. A clinicopathological, ultrastructural and immunohistochemical study. *Virchows Arch A Pathol Anat Histopathol* 1992;420:77-88.
- [44]. Chung DH, Keum JS, Lee GK, et al. Spindle cell hemangioendothelioma. *J Korean Med Sci* 1995;10 211S-215S.
- [45]. Weiss SW, Goldblum JR. Spindle cell hemangioma. In: Weiss SW, Goldblum JR, editors. *Enzinger and Weiss's soft tissue tumors*. Philadelphia, PA: Mosby/Elsevier; 2008. p. 655-8.
- [46]. Benjamin Palla, Omar Suhaym, Nasma Majeed, Steven Garzon, Nicholas Callahan, Spindle cell variant squamous cell carcinoma of the oral cavity: Case presentation and review of literature, *Oral and Maxillofacial Surgery Cases*, Volume 6, Issue 3, 2020, 100174, ISSN 2214-5419
- [47]. World Health Organization. ICD-11 - mortality and morbidity statistics. World Health organization - classifications. <https://icd.who.int/browse11/1-m/en/#/> <http://id.who.int/icd/entity/1181505860>. [Accessed 30 August 2019].
- [48]. Rizzardi C, Frezzini C, Maglione M, Tirelli G, Melato M. A look at the biology of spindle cell squamous carcinoma of the oral cavity: report of a case. *J Oral Maxillofac Surg* 2003;61(2):264-8.
- [49]. Lewis JE, Olsen KD, Sebo TJ. Spindle cell carcinoma of the larynx: review of 26 cases including DNA content and immunohistochemistry. *Hum Pathol* 1997;28 (6):664-73.
- [50]. Leventon GS, Evans HL. Sarcomatoid squamous cell carcinoma of the mucous membranes of the head and neck. *Cancer* 1981;48(4):10.
- [51]. Lewis JS. Spindle cell lesions—neoplastic or non-neoplastic? *Head Neck Pathol* 2008;2(2):103-10.
- [52]. Neville BW. *Oral and maxillofacial pathology*. 3. Saunders/Elsevier; 2009.
- [53]. Ellis GL. Spindle cell carcinoma of the oral cavity 1980;6:12.
- [54]. Thompson LDR, Wieneke JA, Miettinen M, Heffner DK. Spindle cell (sarcomatoid) carcinomas of the larynx: a clinicopathologic study of 187 cases. *Am J Surg Pathol* 2002;26(2):153-70
- [55]. Zarbo RJ, Crissman JD, Venkat H, Weiss MA. Spindle-cell carcinoma of the upper aerodigestive tract mucosa. An immunohistologic and ultrastructural study of 18 biphasic tumors and comparison with seven monophasic spindle-cell tumors. *Am J Surg Pathol* 1986;10(11):741-53.
- [56]. Viswanathan S, Rahman K, Pallavi S, et al. Sarcomatoid (spindle cell) carcinoma of the head and neck mucosal region: a clinicopathologic review of 103 cases from a tertiary referral cancer centre. *Head Neck Pathol* 2010;4(4):265-75.
- [57]. Nasir A, Khare A, Ali I, Khan MI. Ameloblastic fibroma: A case report. *J Oral Maxillofac Pathol* 2023;27:S60-3.
- [58]. Kramer RH, Pindborg JJ, Shear M. The WHO histological typing of odontogenic tumours. *Cancer* 1992;70:2988-94.
- [59]. Sloomweg PJ. An analysis of the interrelationship of the mixed odontogenic



- tumors—ameloblastic fibroma, ameloblastic fibroodontoma, and the odontomas. *Oral Surg Oral Med Oral Pathol* 1981;51:266-76.
- [60]. Chen Y, Li TJ, Gao Y, Yu SF. Ameloblastic fibroma and related lesions: A clinicopathologic study with reference to their nature and interrelationship. *J Oral Pathol Med* 2005;34:588-95.
- [61]. Barnes L, Eveson JW, Reichart PA, Sidransky P. *Pathology and Genetics of Tumours of the Head and Neck: World Health Organization Classification of Tumours: International Histological Classification of Tumors*. 3rd ed. Lyon, France: IARC Press; 2005.
- [62]. Regezi JA, Sciubba JJ, Jordan RC. *Oral Pathology Clinical Pathologic Correlations*. Amsterdam, The Netherlands: Elsevier; 4th ed; 2003.
- [63]. Nelson BL, Folk GS. Ameloblastic fibroma. *Head Neck Pathol* 2009;3:51-3
- [64]. Gupta S, Tandon A, Mehrotra D, and Gupta OP. Ameloblastic fibroma: Report of 3 cases and literature review. *Int J Oral Maxillofac Pathol* 2011;2:59-63.
- [65]. Jindal C, Bhole RS. Ameloblastic fibroma in six-year-old male: Hamartoma or a true neoplasm. *J Oral Maxillofac Pathol* 2011;15:303-5.
- [66]. Pitak – Armnop P, Chaine A, Dhanuthai K, Charles Bertrand J, Bertolus C. Extensive ameloblastic fibroma in an adolescent patient: A case report with a follow up of 4 years. *Eur J Dent* 2009;3:224-8.