



## Stargardt Disease: A Rare Case Report

Dr. Harshika, Dr. Atul Mishra

(Junior resident, Department of Ophthalmology, Katihar medical college, Katihar)  
(Prof and HOD, Department of Ophthalmology, Katihar medical college, Katihar)

Date of Submission: 05-10-2023

Date of Acceptance: 15-10-2023

### ABSTRACT

We present a case of Stargardt disease in a thirty year old male who had been experiencing visual loss in both of his eyes since 8 years. Upon examination, a circular lesion at the macula was discovered. Its appearance was hammered bronze and suggested Stargardt disease. One of the most prevalent forms of inherited vision impairment in children and adults is Stargardt disease. The capacity to detect Stargardt illness in its initial stages has significantly improved due to the disease's considerable phenotypic and genetic heterogeneity.

**KEYWORDS:** Lipofuscin, Macular dystrophy, Autosomal recessive, Stargardt disease.

### I. INTRODUCTION

A juvenile hereditary macula dystrophy known as Stargardt disease is characterised by the deposition of small, distinct yellowish, round, or pisciform flecks around the posterior pole.[1] The level of the retinal pigment epithelium (RPE) is often where these deposits are found. The most typical kind of inherited macular dystrophy is it. Although there is little information on disease occurrence, a rough estimate places the prevalence rate between 1 in 8000 and 10000.[1-7] The ABCA4 gene has been identified to be related with this condition, which often has an autosomal recessive mode of inheritance.[8-11] Both in terms of clinical appearance and genetic underpinnings, there is no gender or racial bias, and there is heterogeneity.[12-17]

Patients typically complain of bilaterally diminished visual acuity during their first or second decade. A better prognosis is related to late onset.[18] Additionally possible are a positive

central scotoma and impaired colour vision. Gradually, visual acuity drops to 6/60. A fundus examination indicates the presence of some yellowish flecks and an early stage of snail's slime at the macula. As the condition worsens, a bull's-eye maculopathy with atrophy of the retinal pigment epithelium or a beaten bronze look may develop. The posterior pole is where changes are most noticeable, although occasionally they can also damage the peripheral retina, causing disc pallor, vascular attenuation, and pigmentary disturbances.

Fundus fluorescein angiography is the preferred investigation because it shows "silent choroidien". This observation of a quiet choroid that appears dark in FFA is most likely the result of an accumulation of lipofuscin in the RPE. Against a hypofluorescent choroid, the retinal arteries are more visible. In the later stages, ERG and EOG deteriorate and visual fields likewise shrink.

### II. CASE REPORT

A 30-year-old young male presented with complaints of diminution of vision in both eyes since 8 years. Additionally, he also reported a steady and gradual loss of his capacity to identify minute features in objects and distinguish between faces and colours. None of his siblings or first-degree relatives had a history like this. He did not have a chronic condition, and he did not require ongoing medical care. He did not engage in any addiction of any kind.

His overall and systemic examination results were normal. His visual acuity was found to be 3/60 in his right eye and 2/60 in his left eye during an ocular checkup. His colour vision was impaired in both of his eyes.

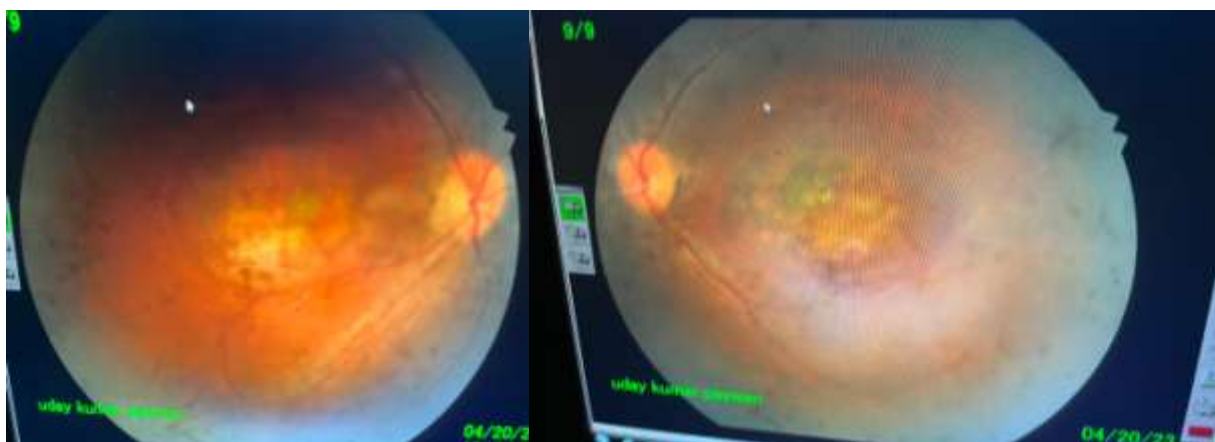
	RIGHT EYE	LEFT EYE
Visual acuity	3/60	2/60
IOP (by NCT)	16 mmhg	14 mmhg
EOM	full in all directions	full in all directions
Palpebral conjunctiva	quite	quite
Cornea	transparent	transparent
Iris	normal	Normal
Pupil	RRR	RRR



Lens	clear	clear

On distant direct ophthalmoscopy, the media and red fundal glow were both normal. Both eyes' optic discs were pallid on direct ophthalmoscopy, and neither eye's foveal reflex was present. The right eye has more pallor than the left. The ocular discs in both eyes were of typical size and form, with clearly defined edges. In both eyes, vessels with a normal arteriovenous ratio of 2:3 emerged from the disc's centre in a

dichotomously branching pattern. At the macula, an ill-defined circular lesion with a beaten golden appearance was visible. It was more noticeable in red free fundus images. There were numerous little pale specks. All four quadrants of both eyes revealed several tiny yellowish specks. The patient's weak fixation made it impossible to do a visual field test. There were no electrophysiological experiments conducted.



As part of his visual rehabilitation, the patient was provided low vision devices and given a thorough explanation of his condition's prognosis.

### III. DISCUSSION

Stargardt disease is a hereditary disorder brought on by mutations in the big ABCA4 gene. The transmembrane transporter protein, which is expressed by rod outer segments, is not produced by the ABCA4 (ABCR) gene as a result of these mutations. Since this protein is essential for vision, a lack of it eventually causes lipofuscin to accumulate in the retina.[21,22] Autosomal recessive cone rod dystrophy can also be brought on by mutations in ABCA4.[23]

The susceptibility to age-related macular degeneration is also increased by some ABCR-variant alleles, however further research is necessary in this area.[24]

The three-step pathogenesis hypothesised by Glazer and Dryja for Stargardt's illness is as follows: (1) a faulty Rim protein produced by the ABCA4 gene leads to a buildup of protonated N-retinylethylene-PE in the outer segments of rods (2) Retinal pigment epithelium cells accumulate A2E, a result of N-retinylethylene-PE and cause toxicity (3)

photoreceptors eventually atrophy due to loss of retinal pigment epithelial support function[25]

Parents of persons with Stargardt disease often have one defective ABCA4 gene each. A faulty gene from either parent will impact the offspring. This type of inheritance is autosomal recessive. However, there is extremely little chance that a person with Stargardt illness will have a kid who is afflicted.

Another disorder is known as Stargardt-like disease. It results from ELOVL4 gene mutations. In this instance, the disorder can be brought on by even one faulty gene. Autosomal dominant inheritance is the term used for this. A family may have been affected by a condition similar to Stargardt for several generations. Genetic counselling and testing can differentiate between these conditions.

There are presently no approved treatments to stop or delay the Stargardt disease-related visual loss. Since there is currently no other available form of treatment, low vision aids are prescribed.[26] Even if eyesight remains consistent, it is still crucial to get frequent eye examinations to detect significant but curable issues like macular edema.



Numerous studies have been conducted to develop potential therapies for Stargardt illness. Clinical trials for two different forms of treatment have already been completed.

Treatments known as "gene therapy" try to replace defective genes in retinal cells with healthy ones. This may prevent additional visual loss by slowing or stopping the accumulation of lipofuscin.

Another set of studies is investigating the transplantation of fresh RPE cells made from stem cells to assist the retina in removing the accumulation of lipofuscin. This could stop or delay additional eyesight loss. The first trials for this medicine have started.

#### IV. CONCLUSION

One of the most prevalent forms of inherited vision impairment in children and adults is Stargardt disease which is highly heterogeneous both phenotypically & genetically, and significant progress has been made in the diagnosis of the disease at its earlier stages, identifying clinical characteristics that allow for more accurate prognosis information, carrying out accurate rapid molecular genetic testing, and comprehending the underlying disease mechanisms. Until now, there is no specific therapy for Stargardt disease. Supportive therapy such as correction with low vision aids or the provision of sun protective glasses can help in the daily lives of patients

#### REFERENCES

- [1]. Michaelides M, Hunt DM, Moore AT. The genetics of inherited macular dystrophies. *J Med Genet*, 2003; 40: 641–50.
- [2]. Fujinami K, Lois N, Davidson AE, et al. A longitudinal study of stargardt disease: clinical and electrophysiologic assessment, progression, and genotype correlations. *Am J Ophthalmol*, 2013; 155: 1075–88.
- [3]. Fujinami K, Zernant J, Chana RK, et al. Clinical and molecular characteristics of childhood-onset Stargardt disease. *Ophthalmology*, 2015; 122: 326–34.
- [4]. Molday RS. Insights into the molecular properties of ABCA4 and its role in the visual cycle and stargardt disease. *Prog Mol BiolTransl Sci.*, 2015; 134: 415–31.
- [5]. Strauss RW, Ho A, Munoz B, et al. The natural history of the progression of atrophy secondary to Stargardt disease (ProgStar) studies: design and baseline characteristics: ProgStar Report No. 1. *Ophthalmology*, 2016; 123: 817–28.
- [6]. Burke TR, Tsang SH. Allelic and phenotypic heterogeneity in ABCA4 mutations. *Ophthalmic Genet*, 2011; 32: 165–74.
- [7]. Lambertus S, van Huet RA, Bax NM, et al. Early-onset stargardt disease: phenotypic and genotypic characteristics. *Ophthalmology*, 2015; 122: 335–44.
- [8]. Allikmets R, Singh N, Sun H, et al. A photoreceptor cell-specific ATP-binding transporter gene (ABCR) is mutated in recessive Stargardt macular dystrophy. *Nat Genet*, 1997; 15: 236–46.
- [9]. Fujinami K, Zernant J, Chana RK, et al. ABCA4 gene screening by next-generation sequencing in a British cohort. *Invest Ophthalmol Vis Sci.*, 2013; 54: 6662–74.
- [10]. Zernant J, Schubert C, Im KM, et al. Analysis of the ABCA4 gene by next-generation sequencing. *Invest Ophthalmol Vis Sci.*, 2011; 52: 8479–87.
- [11]. Haji Abdollahi S, Hirose T. Stargardt-Fundus flavimaculatus: recent advancements and treatment. *Semin Ophthalmol*, 2013; 28: 372–6.
- [12]. Michaelides M, Chen LL, Brantley MA Jr, et al. ABCA4 mutations and discordant ABCA4 alleles in patients and siblings with bull's-eye maculopathy. *Br J Ophthalmol*, 2007; 91: 1650–5.
- [13]. Fujinami K, Lois N, Mukherjee R, et al. A longitudinal study of Stargardt disease: quantitative assessment of fundus autofluorescence, progression, and genotype correlations. *Invest Ophthalmol Vis Sci.*, 2013; 54: 8181–90.
- [14]. Fujinami K, Sergouniotis PI, Davidson AE, et al. The clinical effect of homozygous ABCA4 alleles in 18 patients. *Ophthalmology*, 2013; 120: 2324–31.
- [15]. Fujinami K, Sergouniotis PI, Davidson AE, et al. Clinical and molecular analysis of Stargardt disease with preserved foveal structure and function. *Am J Ophthalmol*, 2013; 156: 487–501.
- [16]. Westeneng-van Haaften SC, Boon CJ, Cremers FP, et al. Clinical and genetic characteristics of late-onset Stargardt's disease. *Ophthalmology*, 2012; 119: 1199–210.
- [17]. Lois N, Holder GE, Bunce C, et al. Phenotypic subtypes of Stargardt macular dystrophy-fundus flavimaculatus. *Arch Ophthalmol*, 2001; 119: 359–69.



- [18]. Rotenstreich Y, Fishman GA, Anderson RJ. Visual acuity loss and clinical observations in a large series of patients with Stargardt disease. *Ophthalmology*, 2003; 110: 1151–8.
- [19]. Burke TR, Tsang SH, Zernant J, et al. Familial discordance in Stargardt disease. *Mol Vis*, 2012; 18: 227–33.
- [20]. Singh R, Fujinami K, Chen LL, et al. Longitudinal follow-up of siblings with a discordant Stargardt disease phenotype. *Acta Ophthalmol*, 2014; 92: e331–2.
- [21]. Cremers FP, Van de Pol DJ, VanDriel M, et al. Autosomal recessive retinitis pigmentosa and cone-rod dystrophy caused by splice site mutations in the Stargardt's disease gene ABCR. *Hum Mol Genet*, 1998 Mar; 7(3): 355-62.
- [22]. Mageri A, Klevering BJ, Rohrschneider K, et al. Mutations in the ABCA4 (ABCR) gene are the major cause of autosomal recessive cone-rod dystrophy. *Am J Hum Genet*, 2000; 67: 960–966.
- [23]. Rudolph G, Kalpadakis P, Haritoglou C, Rivera A, Weber BH. Mutations in the ABCA4 gene in a family with Stargardt's disease and retinitis pigmentosa (STGD1/RP19) *KlinMonatsblAugenheilkd*, 2002; 219: 590–596.
- [24]. Bernstein PS, Leppert M, Singh N. Genotype-phenotype analysis of ABCR variants in macular degeneration probands and siblings. *Invest Ophthalmol Vis Sci*, 2002; 43: 466–473.
- [25]. Glazer LC, Dryja TP. Understanding the etiology of Stargardt's disease *Ophthalmol Clin North Am*, 2002 Mar; 15(1): 93-100.
- [26]. Fishman GA, Farber M, Patel BS, et al. Visual acuity loss in patients with Stargardt's macular dystrophy. *Ophthalmology*, 1987 Jul; 94(7): 809-14.