



Threestage Laparoscopic Ileal Pouch Anal Anastomosis (Ipa) In Ulcerative Colitis.

Dr.Kakumanu A Y Bharath

Prathima Institute of Medical Sciences, Karimnagar, Telangana

Corresponding Author: Prof. Dr.K.Lakshmana Murthy

Submitted: 10-10-2022

Accepted: 21-10-2022

ABSTRACT:

Restorative Proctocolectomy with Ileal Pouch Anal Anastomosis (IPAA) has revolutionized the treatment of ulcerative colitis (UC) and is now considered as treatment of choice in a subset of Ulcerative Colitis (UC). Though laparoscopic surgery is complex it is feasible and considered safe when done by experienced surgeon. Technical aspects and troubleshooting with minimal invasive approach are to be noted.

KEYWORDS: Laparoscopic, Ileal pouch anal anastomosis (IPAA), ulcerative colitis (UC).

I. INTRODUCTION:

Restorative Proctocolectomy with the ileal pouch–anal anastomosis (IPAA) is a surgical procedure that is used to restore gastrointestinal tract continuity after surgical removal of the colon and rectum. Various conditions, including inflammatory states like Ulcerative Colitis, cancer, or infection, may necessitate the complete surgical removal of the colon and rectum. It is also called a J pouch or an internal pouch, the procedure involves the creation of a pouch of small intestine to recreate the removed rectum. Two or more loops of intestine are sutured or stapled together to form a reservoir for stool. Ulcerative colitis (UC) is very uncommon in early age, it's a chronic, lifelong condition that can cause problems with growth and development. The exact cause of ulcerative colitis is unknown, but experts suspect both genetic and environmental factors are involved in triggering the immune system response that causes intestinal inflammation and leads to inflammatory bowel disease. A family history of inflammatory bowel disease increases the risk of developing ulcerative colitis.

CASE REPORT DETAILS :

A 21yr old male patient had recurrent episodes of bleeding per rectum and pain abdomen since 15 days. Colonoscopy revealed erosions and ulcers from rectum till hepatic flexure, biopsy was done suggesting UC. Medical management was

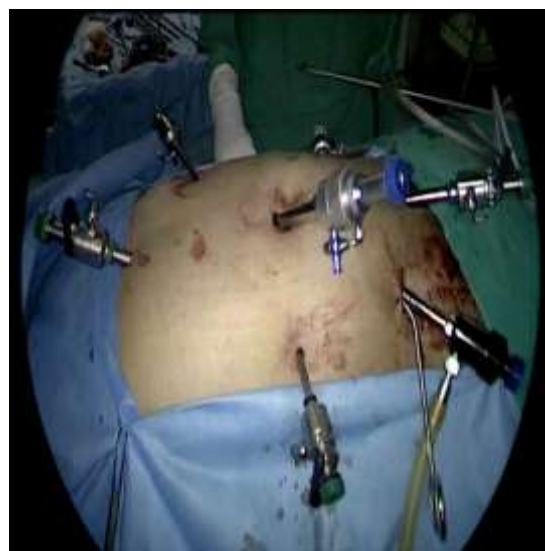done, but suffered from multiple relapses even on steroids. Due to steroid dependency after appropriate investigations, Three stage Restorative Proctocolectomy was planned.

1ST STAGE ---- Laparoscopic Subtotal Colectomy + Ileostomy was done. Post operatively medical management was given and after 6 weeks.

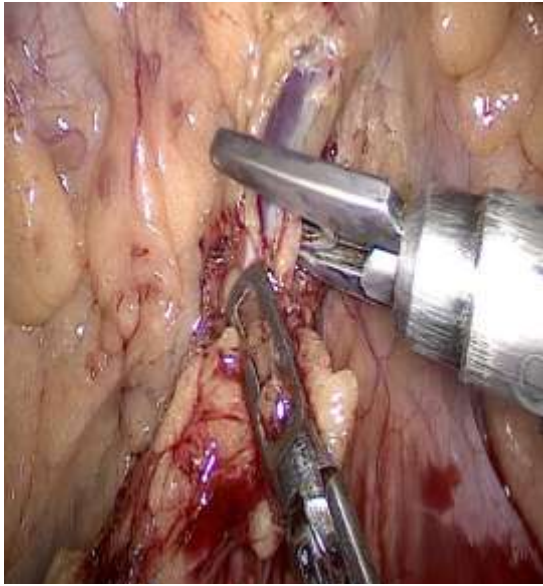2ND STAGE ---- Subtotal Proctocolectomy + Ileal Pouch Anal Anastomosis (IPAA) was done.

3RD STAGE ---- Ileostomy closure was done 4 weeks later.

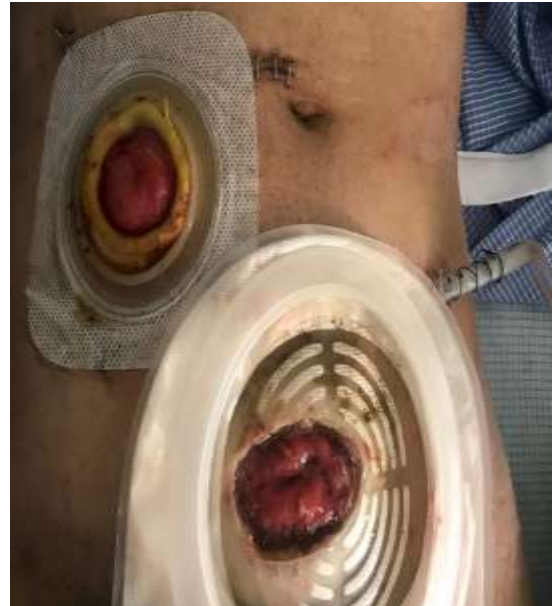During follow up stool frequency was 6-8 episodes with no evidence of pouch complications.



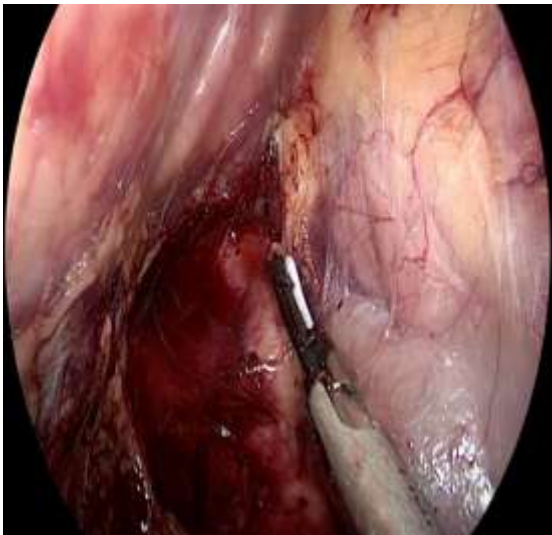
Figure_1A: Position of seven ports



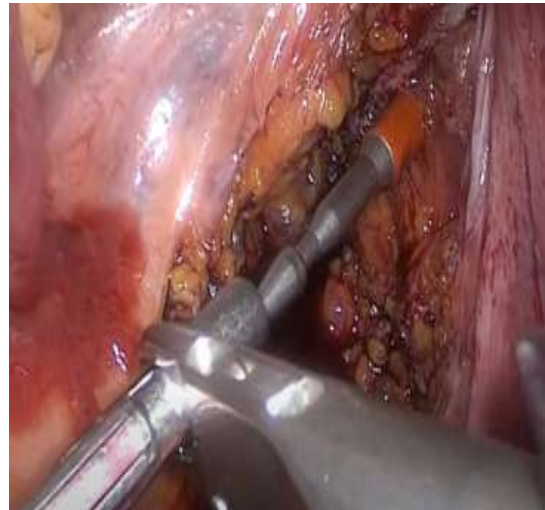Figure_1B: Ligation of Sigmoid artery



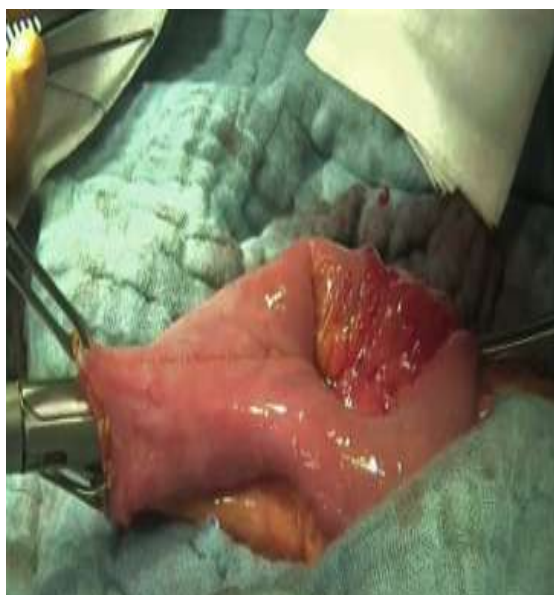Figure_1D : Ileostomy with distal mucus fistula



Figure_1C : Retrocolic dissection duodenum pancreas (right),Gerota's fascia (left)



Figure_1E : Ileal J pouch construction



Figure_1F : Ileal Pouch Anal Anastomosis (IPAA) with circular stapler

II. DISCUSSION :

Restorative Proctocolectomy with Ileal Pouch Anal Anastomosis (IPAA) cures Ulcerative Colitis (UC) and has satisfactory functional result. These Staged procedures still remains prudent for selected patients (steroid dependent ulcerative colitis (UC), severe colitis, malnutrition). This complex operation removes the diseased colon, rectum and construction of neo rectum using ileal pouch. Even though there are complications from pouch, Ileal Pouch Anal Anastomosis (IPAA) has a protective effect ensuring avoidance of drugs in Ulcerative Colitis (UC) and related side effects (steroid psychosis, azathioprine pancreatitis). Ambiguity of open versus laparoscopic approach still remains because of inadequate randomised control trials. The study by Fleming et al^[3] showed that the laparoscopic approach was associated with a lower rate of major and minor complications. American College of Surgeons National Surgical Quality Improvement Program database^[4] for all ulcerative colitis (UC) patients who underwent colectomy demonstrated that a laparoscopic approach was associated with lower morbidity, mortality.

III. CONCLUSION :

Ileal Pouch Anal Anastomosis (IPAA) is the procedure of choice in medically uncontrolled Ulcerative colitis (UC). Dilemma between open versus laparoscopic is due to inadequate evidence. If randomised controlled trials provide evidence in favour of laparoscopic Ileal Pouch

Anal Anastomosis (IPAA), it will become standard care especially in younger patients.

REFERENCES :

- [1]. Bailey and love's short practice of surgery 27th edition.
- [2]. Sabiston textbook of surgery the biological basis of modern surgical practice 1st south asian edition.
- [3]. Fleming FJ, Francone TD, Kim MJ, Gunzler D, Messing S, Monson JR. A laparoscopic approach does reduce short-term complications in patients undergoing ileal pouch-anal anastomosis. *Dis Colon Rectum* 2011; 54: 176-182 [PMID: 21228665 DOI: 10.1007/DCR.0b013e3181fb4232]
- [4]. Causey MW, Stoddard D, Johnson EK, Maykel JA, Martin MJ, Rivadeneira D, Steele SR. Laparoscopy impacts outcomes favorably following colectomy for ulcerative colitis: a critical analysis of the ACS-NSQIP database. *Surg Endosc* 2013; 27: 603-609 [PMID: 22955999 DOI: 10.1007/s00464-012-2498-7].