



Unusual Presentation of Central Giant Cell Granuloma of Mandible

Dr. Ranjan Ghosh*¹, Dr Jayanta Saha², Dr Sourav Bhattacharya³, Dr. Aniket Adhikari⁴

BDS, MDS (Oral pathology), PGDHS (Tobacco Control).

BDS, MDS (Oral and Maxillofacial Surgery),

BDS, MDS (Oral Pathology),

MSc, Ph.D. (Oral Cancer).

Date of Submission: 01-05-2024

Date of Acceptance: 10-05-2024

ABSTRACT: Central Giant Cell Granuloma (CGCG) is an uncommon benign osseous lesion of the jaws. We present here a case of bilateral involvement of lower jaw in a young female patient. The case is unusual because the patient presented with the same lesion on both sides which appeared over a period of five long years. CT (Computed Tomography) scan revealed that there was osseous remodelling of the lesion and both radiopaque and radiolucent lesions were present in the jaws. The patient presented with both a lytic lesion which showed active bone destruction and teeth mobility as well as static lesion with no bone destruction. This case helps to show the wide variety of clinical, radiological and histopathological features of CGCG and the importance of thorough investigation for timely diagnosis.

KEYWORDS: CGCG, Osseous lesion, CT, Histopathology, Bilateral involvement

I. INTRODUCTION

Central giant cell granuloma (CGCG) is a non-neoplastic, benign lesion that shows osteolytic behaviour. CGCG in the jaws vary from asymptomatic lesion to symptomatic lesion. The lesion was named giant cell reparative granuloma (GCRG) discovered by Jaffe in 1953. Later on, GCRG was changed to CGCG, due to the destructive nature of the lesion [1]. The World Health Organization (WHO) defines CGCG as a unicentric benign lesion which may present as an aggressive (destructive) osteolytic growth composed of fibro-collagenous tissue admixed with foci of hemorrhage, hemosiderin deposits, osteoclast-like giant cells and reactive bone formation. Though the aetio-pathogenetic basis for CGCG is not yet well known, its clinico-pathologic features have been well studied. Theories on the nature of CGCG variably describe it as a reactive

lesion, developmental anomaly, benign neoplasm or non-neoplastic bone lesion [2]. CGCGs develop twice as often frequently in the mandible than in the maxilla. However, there was no clear prevalence concerning the different regions of the jaws. CGCGs have a wide range of clinical manifestations, from symptomatic, slow-growing lesions without recurrence to rapidly growing, painful, and aggressive lesions with cortical plate thinning and perforation, as well as soft tissue mass and mucosal ulceration [3].

We present here an unusual case in a female patient where the lesion was present for almost five years without treatment and presented on the opposite side of the jaw with a completely different manifestation. The lesion was such that we thought of two different lesions initially but histopathology proved that it was a single lesion with varied manifestations.

II. CASE REPORT

A 31-year-old female patient reported to the Department of Oral Pathology, Burdwan Dental College and Hospital with chief complaint of facial swelling and bleeding gums of the left side of the lower jaw along with mobility of teeth for one and a half months. The patient reported about a similar swelling on the right side of the jaw five years ago. Planned surgical exploration of the lesion was to be done but the surgery was deferred due to pregnancy of the patient. Subsequently, the intraoral lesion on the right side of the lower jaw healed although some posterior teeth were lost due to extraction (#47, #48). The swelling on the right side of the jaw persisted. Post pregnancy the patient did not go for any treatment.

Now the patient has presented with a firm fleshy mass on the left side of the posterior lower jaw with mobility and displacement of molar teeth. The overlying mucosa was erythematous and tender. The mass is almost 3 cm x 1.5 cm in size

with displacement of #36 & #38 both of whom are

carious. #37 has been lost. (Figure 1 & 2)

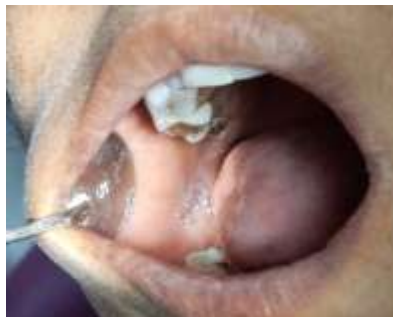

Figure 1

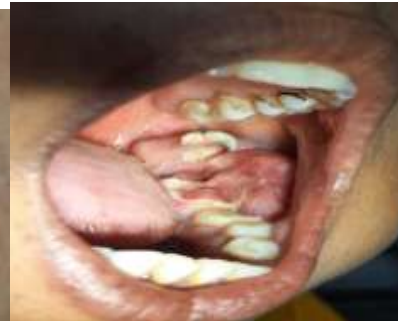

Figure 2

Radiological findings were very contrasting on the right and left side of the jaw. The right side of the mandible on OPG of the jaw showed a mixed radiolucent radiopaque lesion involving the body and angle of the mandible with

expansion of the lower border. The lesion was diffuse without any definite borders and more radiopacity was noted. On the left side, definite bone loss was noted particularly in relation to the molar teeth marked by radiolucency. (Figure 3)

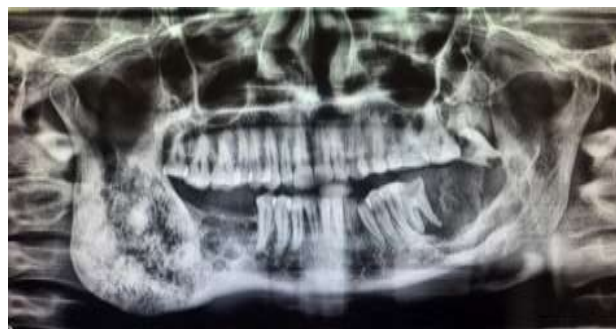

Figure 3

Investigations revealed normal blood picture. The patient was put up for biopsy with a provisional diagnosis of odontogenic tumour/collision tumour. It was thought that the two sides of the jaw might present separate diagnosis. Incisional biopsy was done from both right and left side of the lower jaw. Three bits of tissues were taken. From the right side, both bony tissue and soft tissue were taken whereas from the left side only soft tissue was taken. Histopathology was

done using Haematoxylin & Eosin (H&E) staining. Sections stained with H&E revealed unremarkable trabeculae of bone with fibro collagenous tissue of the bony tissue. Both the soft tissue biopsies had similar findings. They revealed multiple multinucleated osteoclast like giant cells in a fibrous stroma. The stromal cells were without significant mitotic activity or pleomorphism. (Figure 4 & 5)

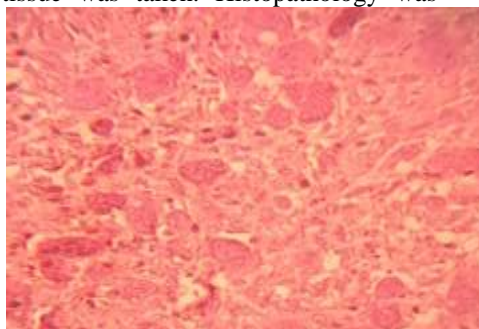


Figure 4

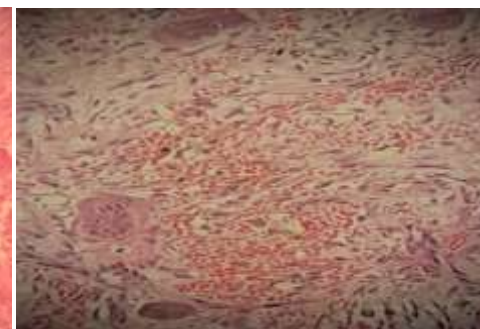


Figure 5



Post biopsy, serum parathyroid and alkaline phosphatase was checked and found to be within normal limits. A CT scan of the mandible

revealed multiple cystic lesions, bony remodelling and multilocularity bilaterally in the mandible. (Figure 6)

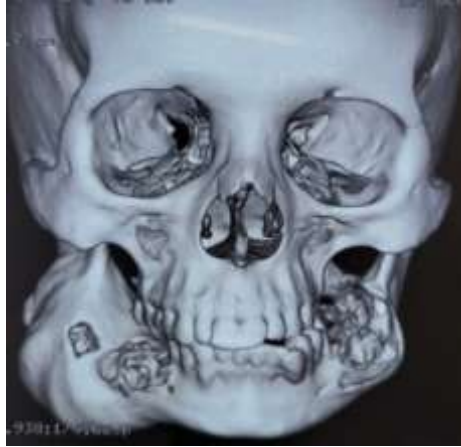

Figure 6

The overall clinical, radiological and histopathological features were concluded to be of Central Giant Cell Granuloma involving the mandible. The lesion was referred to The Department of Oral & Maxillofacial Surgery for further management.

III. DISCUSSION

Central Giant Cell Granuloma (CGCG) has wide range of clinical variations and radiological features. In this case, we found two types of lesions separated by a time period of five years with varying clinical and radiological features. There was osteolysis as well as bone formation within the same lesion on different sides of the jaw. Due to the presentation, we thought of two separate lesions of the jaw bone which were found to be same after biopsy and histopathology.

CGCG is a rare benign mass lesion which can be completely intra-osseous as well as presenting as peripheral lesion. Peripheral lesion can arise from PDL. Tooth extraction can also precipitate CGCG. It can present as aggressive as well as non-aggressive lesion. It is important to carry out assays of serum calcium, alkaline phosphatase, thyroid and parathyroid to rule out close differentials. Radiotherapy is contraindicated [2].

A case of an aggressive CGCG in a 16-year-old boy with a 5-month history of facial swelling and nasal obstruction was reported. He was referred for a radiology consult for multiple expanding swellings on the right hemi-face. The swellings were reported to have an insidious onset, slow progression and no association with

paresthesia, nasal discharge, or systemic symptoms. Extra oral examination revealed a diffuse swelling on the right side of the face which obliterated the nasolabial fold causing facial asymmetry. A face and neck computed tomography (CT) showed expansile multi loculated lytic lesions of the right mandibular ramus which involved the condyle and hard palate. Similar lesions were also found in the skull base. Scans showed fine internal septations and internal ground glass haze. It also revealed involvement of several teeth roots and surrounding soft tissues [4]. This case shows that CGCG can assume very aggressive characteristics and can show unpredictable behaviour.

In another case, authors reported CGCG in an elderly female patient 3 years after extraction of teeth. The lesion was subsequently treated by surgery [5].

CGCG can be so aggressive that sometimes they can be confused with malignancy. A 50 year old man affected by lesion in the lower jaw underwent en bloc resection of the involved regions of the mandible and titanium plate prosthesis was used for the jaw reconstruction [6].

Although some studies have found that aggressiveness of CGCG is related with greater number of Giant cells and greater mitotic activity, others have found that clinical and radiographic features are more important and microscopic findings are not very relevant for treatment purposes [7, 8, 9, 10, 11].

Regarding treatment options, surgery remains the mainstay which can range from simple excision and enucleation to aggressive resections. Medical treatments can include steroids, calcitonin, alpha interferon and bisphosphonates [5].



Also Surgeons should be careful about too much aggressive treatment in growing and young patients because bony remodelling can lead to ossification of the lesion [12].

IV. CONCLUSION

CGCG can present a multitude of presentations and we should remember that each case and patient is different and manifestations are very wide ranging. Proper investigations should be done to rule out the differentials. Although aggressive surgery is needed in some cases, it should be remembered that one shoe does not fit all. The case should be evaluated properly and other modes of treatment should be explored. Lastly, further studies are needed for the role of pregnancy and hormones on the behaviour of the lesion.

REFERENCES

- [1]. Sutare, A., Parihar, A. P. S., Varsha, A.C., Singh, R. (2021). Aggressive Central Giant Cell Granuloma in the Posterior Region of Mandible: A Case Report. *International Journal of Health Sciences and Research*, 11(4),118 -121.
- [2]. Uchechukwu, B. E., Nwashindi, A., Kudamnya, I. (2022). Aggressive central giant cell granuloma of the mandible: A case report and review of literature. *IBOM Medical Journal*,15(2), 183 – 190.
- [3]. Mohammadi, F., Bashizadehfakhar, H., Aliasghari, S., Gholamhoseini, Z. (2023). Aggressive Multiple Central Giant Cell Granulomas of the Jaws. *Hindawi Case Reports in Dentistry*,1-7.
- [4]. Admani, B. Ali., Siddiqui, F., Ahmed, H., Hameed, M. (2023). An unusual radiological manifestation of a mandibular central giant cell granuloma: Case Report. *International Journal of Scientific Reports*,9(9),295-298.
- [5]. International Journal of Scientific Reports ,9(9),295-298.
- [6]. Azzouzi, A., El Harti, K. (2021). Central Giant Cell Granuloma of the Mandible: A Case Report. *Integr J Med Sci*, 8 ,1-4.
- [7]. Najar, K. F., Jazayeri, M., Abbasi, F., Safabakhsh, D., Ahmadi, M. F. (2022). Central giant cell granuloma mimicking a malignant lesion of mandible: A case report. *Journal of Craniomaxillofacial Research* ,9(2), 106-109.
- [8]. Ehtisham, M., Kaur, P., Nissar, S., Wani, F., Jan, I. (2016). Central giant cell granuloma: uncommon yet important. *Journal of Dental and Medical Sciences*, 15(5),74–80.
- [9]. Gataa, I. S., Zardawi, F. (2015). Primary hyperparathyroidism presented as central giant cell granuloma of jaw bones: A report of three cases. *IOSR Journal of Dental and Medical Sciences*,14,75–79.
- [10]. Curtis, N., Walker, D. (2005). A case of aggressive multiple metachronous central giant cell granulomas of the jaws: differential diagnosis and management options, *International Journal of Oral and Maxillofacial Surgery*, 34 (7), 806 - 808.
- [11]. WHO Classification of Tumours, WHO Classification of Head and Neck Tumours: International Agency for Research on Cancer (IARC), 2017.
- [12]. Chuong, R., Kaban,L. B., Kozakewich, H., Perez-Atayde, A. (1986). Central giant cell lesions of the jaws: a clinicopathologic study. *Journal of Oral and Maxillofacial Surgery*, 44(9),708–713.
- [13]. Kashyap, N., Upadhyay, M., Tripathi, R., Pawar, P., Sah, R.K.P., Mandal, R.K. (2019). Central Giant Cell Granuloma: A case report. *J Dent Oral Maxillofac Surg*, 2(2),1 -4.